

Wnt/ β -catenin Signaling in Endometrioid Endometrial Cancer and Precursor Lesions

Dr. Sunita Yadav^{1*}, Dr. Annu Makker², Dr. Seema Nayak³, Dr. Preeti Agarwal⁴, Dr. Uma Singh⁵, Dr. Uma Shanker Singh⁶, Dr. Madhu Mati Goel⁷

¹Assistant Professor, Department of Pathology, Mayo Institute of Medical Sciences, Barabanki, UP 225003, UP, India

²Associate Professor, Department of Biochemistry, Saraswati Medical College, Unnao, UP 209859 India

³Scientist-Molecular Biology and Immunology, Laboratory Medicine, Medanta Hospital Lucknow, UP, India

⁴Additional Professor, Department of Pathology, KGMU, Lucknow 226003, UP, India

⁵Former HOD and Dean Academics KGMU, Senior Technical Director Maternal Health, TSU, UP, India

⁶Professor and Head, Department of Pathology, KGMU, Lucknow 226003, UP, India

⁷Ex- Professor and Head, Department of Pathology KGMU, Director Laboratory Medicine, Medanta Hospital Lucknow, UP, India

DOI: [10.36348/sjpm.2023.v08i08.005](https://doi.org/10.36348/sjpm.2023.v08i08.005)

| Received: 05.07.2023 | Accepted: 09.08.2023 | Published: 15.08.2023

*Corresponding author: Dr. Sunita Yadav

Assistant Professor, Department of Pathology, Mayo Institute of Medical Sciences, Barabanki, UP 225003, UP, India

Abstract

Endometrioid endometrial carcinoma (EEC) is most common invasive malignancy of female genital tract. In spite of advances in diagnosis and treatment, incidence of EEC has been rising because of increasing aging population and prevalence of obesity. Therefore, there is need of research exploring the underlying molecular mechanism of EEC and its precursors. Wnt/ β -catenin signaling are involved in the progression and invasion of EEC. However, the potential role of Wnt/ β -catenin signaling and its effectors in endometrial cancer and precursor lesions remains to be investigated. In the present study a total of 95 samples of endometrial biopsies were assessed histopathologically along with β -catenin expression by immunohistochemistry and promoter methylation of adenomatous polyposis coli (APC) gene by bisulfite method. Women age ranged from 35 to 70 years whose endometrial biopsy and resected samples were obtained. Expression of β -catenin was observed in 28/39; 72% of EEC, 23/37; 62% of precancer cases and 4/19; 21% of normal proliferative endometrium. APC promoter was completely unmethylated in all controls (14/14) and precancer (10/10) groups, however, only one case (1/13, 8%) of cancer was methylated. The present study showed that expression of β -catenin was upregulated in EEC and precursor lesions suggesting involvement of Wnt/ β -catenin signaling from an early stage of development of cancer from precancer. The information might offer a potential therapeutic target for EEC and could also be used as a screening tool in endometrial hyperplasia (EH) cases for detecting potentially precancerous lesions.

Keywords: Immunohistochemistry (IHC), β -catenin, Endometrioid endometrial carcinoma, APC.

Copyright © 2023 The Author(s): This is an open-access article distributed under the terms of the Creative Commons Attribution 4.0 International License (CC BY-NC 4.0) which permits unrestricted use, distribution, and reproduction in any medium for non-commercial use provided the original author and source are credited.

INTRODUCTION

Endometrial carcinoma (EC) contributes to about 7% of all invasive cancer in women [1]. Though, Asian women have a lower incidence of EC than other parts of the world, recent studies have shown increasing trend in these countries [2, 3]. In India, there were 13,328 estimated new cases of EC in 2018, and there were 5010 fatalities [4, 5]. On the clinicopathological basis, EC is divided into two categories: type I and type II. Type I, endometrioid endometrial carcinoma (EEC) are estrogen dependent and make up 80% to 85% of all cases. EEC typically arise in the setting of EH. EH is

associated with prolonged estrogenic stimulation of endometrium. So that they are associated with obesity, diabetes mellitus, hypertension, infertility, nulliparity, anovulation and unopposed estrogen stimulation [6]. EH precedes the development of EEC proved by many studies as they share common predisposing risk factors. Type II carcinomas, account for approximately 15% of cases of EC and usually estrogen-independent [7]. Carcinogenesis is the result of stepwise acquisition of genetic alteration in tumor suppressor genes and oncogenes.

Estrogens can induce Wnt/ β -catenin signaling and activated Wnt/ β -catenin signaling may underlie EH and cancer [8]. β -catenin (*CTNNB1*) functions in a dual manner in epithelial cells, depending on its intracellular localization. At the plasma membrane, β -catenin is an essential component of the E-cadherin–catenin unit and is important for cell differentiation and maintenance of normal tissue architecture. It acts as the main effector of canonical Wnt signaling in the nucleus, which is critically involved in tissue differentiation during embryonic development. From the reports available in literature, it is now apparent that Wnt/ β -catenin signaling are involved in the progression and invasion of EEC and APC promoter was found to be hypermethylated in EC with nuclear β -catenin [9, 10]. However, the potential role of Wnt/ β -catenin signaling and its effectors in endometrial cancer and precursor lesions remains to be investigated.

MATERIAL AND METHODS

Study Design

A prospective case-control study was conducted. The study was carried out at a tertiary care teaching hospital in northern India, between February 2017 to March 2018. Clinical parameters and the results of the endometrial biopsies, including surgically removed materials, were recorded. Biopsies were categorized as normal endometrium, hyperplastic endometrium and endometrioid endometrial carcinoma on the basis of histopathology [11]. All study participants gave written informed consent prior to being enrolled in the study. Patients with endometrial cancers other than EEC and those with any other type of malignancy outside the uterus were excluded. In order to carry out routine histopathology and β -catenin immunolocalization, each sample was taken in 10% neutral formalin. For promoter methylation of APC gene, a part of fresh tissue was collected in PBS (pH=7.4) The Medical University's ethical committee (Ref. no. 78th ECM IIBMD-Ph.D./P2) has approved the study.

Laboratory Techniques and Procedure:

1-Histopathological diagnosis

The tissues were obtained in 10% formalin and processed as per standard techniques for paraffin embedding. Sections were stained with Hematoxylin & Eosin for the histological examination of the tissue.

2-Immunohistochemistry of β -catenin

On some of the selected sections from endometrial lesions that were normal, hyperplastic, and cancerous, β -catenin IHC staining was carried out. Tris EDTA buffer (pH 9.0) was used as the antigen retrieval medium in the EZ antigen retriever system (BioGenex, USA) for 15 minutes at 98°C. Sections were stained for one hour and 30 minutes at 25°C with mouse monoclonal anti- β -catenin (DAKO) (IS720), washed, and then incubated for one hour at room temperature

with Dako Envision FLEX secondary antibody (Dako, Denmark), followed by the addition of 3,3'-diaminobenzidine tetra hydrochloride (DAB). β -catenin-stained cells were counted and their intensity was measured using semi-quantitative scoring. Immunointensity was rated on a scale of 0 (no staining), 1 (light staining), 2 (low intermediate), 3 (high intermediate), and 4 (darkest brown stain). The percentage of staining was graded on a scale of 1: 0-25% of the cells stain positive, 2: 26-50% of the cells stain positive, 3: 51-75% of the cells stain positive, and 4: 76-100% of the cells stain positive. Results ranged from 0 to 16 when the immunointensity and immunopositivity values were multiplied. Samples were classified as negative in the final evaluation for sections scoring 0–3 and positive for sections scoring ≥ 4 [12].

3-DNA isolation and Methylation specific PCR

a. DNA Isolation:

The Pure Link Genomic DNA kit (catalogue no. K1820, Invitrogen, Life Technologies, CA, USA) was used to extract and purify genomic DNA in accordance with the manufacturer's recommendations. Isolated DNA was quantified using Qubit dsDNA broad range assay kits (Invitrogen, Life Technologies, CA; catalog no Q32853) on a Qubit 2.0 fluorometer.

b. Bisulfite treatment and Methylation-specific PCR:

Bisulfite conversion of gDNA (200-500ng) was performed using a commercially available EZ DNA Methylation –Gold™ Kit (Cat no. #D5005, Zymo Research, Irvine, CA, USA). Promoter methylation was analyzed by methylation specific PCR (MSP) as described by Missaoui *et al.*, [13]. Briefly, real time-based MSP was performed using SYBR premix ExTaq (Applied Biosystems), primers specific for the methylated (M) or unmethylated (U) sequences and bisulfite-modified DNA on Applied Biosystems Step One Real-time PCR Detection System (ABI, Foster, Ca) with optimized thermal conditions, followed by final step of melt curve (1cycle of 95°C-15 sec, 60°C-60 sec, 95°C-15 sec with a ramp rate of 0.4). Methyl Primer Express v1.0 Software (Applied Biosystem) and meth primer (Li and Dahiya, 2002) [14], a free online primer design tool was used for designing methylated and unmethylated primers. Specific primer sequences (methylated and unmethylated) were used for APC (Table 1). A sample was regarded as methylation-negative if the PCR product was obtained only with the U set and methylation-positive if the PCR product was obtained with M set or with both the U set and the M set. Human HCT116 DKO non-methylated DNA and methylated DNA were used as negative and positive controls respectively (Cat no. #D5014, Zymo Research, Irvine, CA, USA). MSP was performed in duplicate on all specimens. PCR products were run on 2% agarose gels and visualized after ethidium bromide staining.

Table 1: Details of primers used for methylation specific PCR

Gene (Accession No.)		Primer sequence	Amplicon (bp)
APC (GenbankU02509)	M	F TATTGCGGAGTGCGGGTC	98
		R TCGACGAACTCCCGACGA	
	U	F GTGTTTTATTGTGGAGTGTGGGTT	108
		R CCAATCAACAAACTCCCAACAA	

M: Methylated, U: Unmethylated, F: Forward, R: Reverse, bp: Base pair.

Statistical Analysis

Data was first entered in the pretested structured proforma and then entered into MS excel sheet. The final analysis was done by SPSS software version 24. The categorical variables were compared with Pearson's chi square tests. P-value <0.05 were considered statistically significant.

RESULTS

The cancer group comprised 39 EEC cases, precancer group comprised 37 EH cases and control group comprised 19 normal proliferative endometria cases. Age of women ranged from 35 years to 70 years. Mean \pm SD is 49.11 ± 11.67 . Most frequent complaints in our patients were bleeding per vaginum in 95% of EEC and 71% of precancer cases. Majority of precancer cases (65%) were overweight and 11% were obese. In cancer group 49% were overweight and 13% obese. Most of the cases (86%) of precancer group were premenopausal, however, majority of EEC patients (69%) presented with a history of menopause. Parity was two or more than two in 65% of precancer and 67% of cancer cases. IHC was performed to assess expression of β -catenin and methylation specific PCR for promoter regions of APC gene in normal, precancerous and cancerous endometrial lesions.

Immunohistochemical Expression of β -catenin

Cytoplasmic expression of β -catenin was observed in 72% (28/39) of EEC, 62% (23/37) of precancer cases and 21% (4/19) of normal proliferative endometrium. Within precancer group 63% of EH without atypia and 60% of EH with atypia cases showed positive expression of β -catenin. Statistically significant increase in cytoplasmic expression of β -catenin was observed in glandular epithelium of precancer (p-value 0.004) and cancer (p-value 0.000) as compared to normal control (Table 2, Figure 1). Nuclear positivity indicating nuclear translocation of β -catenin was observed in 8% of cancer cases. Membranous expression of β -catenin was not found significantly increased in precancer and cancer cases.

BMI more than 24 was observed in 17/28; 61% of β -catenin positive EEC cases and 14/23; 61% of β -catenin positive precancer cases. Menopause was noted in 20/28; 71% β -catenin positive EEC cases and 3/23; 13% of β -catenin positive precancer cases. However, association of BMI and menopausal status with β -catenin expression in both cancer and precancer groups was not significant as compared to control.

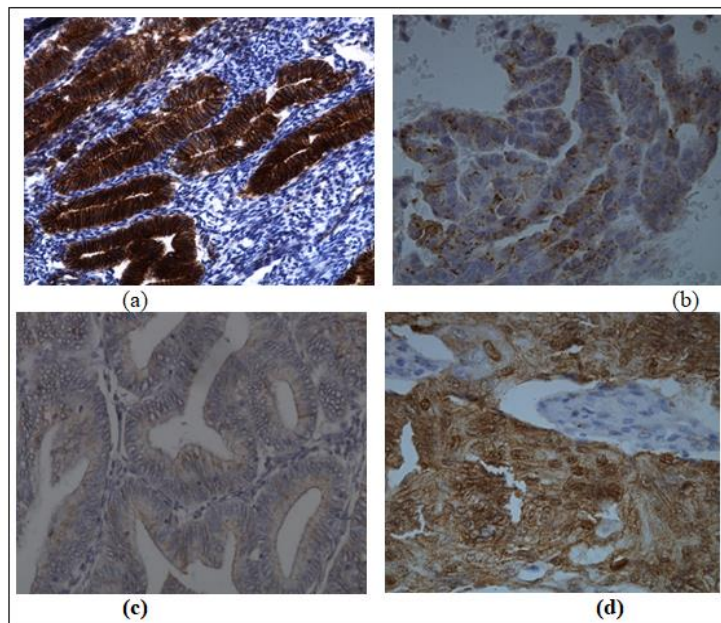


Figure 1: Immunohistochemical localization of β -catenin a) Normal proliferative endometrium showing strong membranous staining in glandular epithelium b) Precancerous endometrium showing cytoplasmic and membranous staining in glandular epithelium c) Endometrioid endometrial carcinoma showing cytoplasmic β -catenin staining d) Endometrioid endometrial carcinoma showing nuclear β -catenin staining

Promoter Methylation of APC gene

Promoter methylation of tumor suppressor APC gene was performed in normal, precancer and cancer cases. APC promoter was completely

unmethylated in all controls (14/14) and precancer (10/10) groups, however, only one case (1/13, 8%) of cancer was methylated (Table 2, Figure 2).




Figure 2: Status of promoter methylation of APC: Methylated & Unmethylated products

Table 2: Immunohistochemical and Promoter methylation analysis of WNT/β-Catenin pathway

1 WNT/β-Catenin pathway: Proteins of Pathway										
S. No	IHC Markers	Control N=19	Precancer N=37					Cancer N=39		
			EH without Atypia N=27		EH with Atypia N=10		Total N=37			
1.1	β-Catenin (Cytoplasmic)	N; %	N; %	X ² ; p	N; %	χ ² ; p	N; %	χ ² ; p	N; %	χ ² ; p
	Positive	4; 21%	17; 63%	.0049	6; 60%	.0359	23; 62%	8.49;	28; 72%	13.30;
	Negative	15; 79%	10; 37%		4; 40%		14; 38%	.004	11; 28%	.000
1.2	β-Catenin (Membranous)									
	Positive	13; 54%	22; 81%	1.05;	8; 80%	.507	30; 81%	1.12;	32; 82%	1.36;
	Negative	6; 46%	5; 19%	.306	2; 20%		7; 19%	.28	7; 18%	.24
Methylation status of WNT/β-Catenin pathway (APC gene)										
2.		Control N=14	EH without Atypia N=6	EH with Atypia N=4		Total Precancer N=10	Cancer N=13			
	Methylated	0; 0%	0; 0%	0; 0%		0; 0%	1; 8%			
	Unmethylated	14; 100%	6; 100%	4; 100%		10; 100%	12; 92%			

DISCUSSION

In the present study we observed 72% EEC showed positive expression of β-catenin. Similar to our results Narita *et al.*, (2003) [15] observed positive expression of β-catenin in 70% (7/10) of G1, 55.6% (5/9) of G2 differentiated EC, but never found in G3

undifferentiated carcinoma. Their findings suggested that expression of β-catenin was inversely related to grades of EEC and was associated with favorable prognosis.

In this study expression of β -catenin was observed in 60% of EH with atypia cases. Norimastu *et al.*, (2007) [16], observed β -catenin positivity in 26.3% (10/38) in cases of endometrial intraepithelial neoplasia. Immunohistochemical positivity of β -catenin in precancerous lesions might suggest, that Wnt/ β -catenin signaling activation is an early event in tumorigenesis of EEC and may serve as an effective biomarker for early diagnosis of EEC. None of the normal proliferative endometrium in our study showed β -catenin expression.

Unlike our findings, Shaco-Levy *et al.*, (2008) [17], found cytoplasmic and membranous positivity of β -catenin in all cases of proliferative endometrium and 99% of EEC cases, although in serous carcinoma only 22% cases showed positivity. Similar to our findings they also found 25% nuclear staining of β -catenin in one out of 14 cases, this case however, did not show membranous and cytoplasmic expression of β -catenin. Their study suggested that expression of β -catenin differs according to histological type of EC. Nuclear accumulation of β -catenin related to activation of APC/ β -catenin /Tcf pathway and implicated in the development of EC. Xiong *et al.*, (2009) [18] reported positive expression of β -catenin in 66.7% (16/24) of EEC, 50% (12/24) of endometrial hyperplasia with atypia and 10.2% (6/59) of endometrial hyperplasia without atypia. They suggested that abnormal expression of β -catenin, may be an early event in tumorigenesis of EEC. This can also be useful in distinguishing endometrial hyperplasia without atypia from endometrial hyperplasia with atypia and EEC. Salv *et al.*, 2016 [19] in their study of PTEN and β -catenin IHC in 59 cases of EC, observed 61% and 69.5% positivity respectively. They opined that these two markers can not be used to determine the prognosis of EC.

Travaglino *et al.*, (2019) [20] found moderate to strong expression of β -catenin in EH as a marker of premalignancy. They also defined the association between nuclear β -catenin expression and premalignant features in EH. Mitzi *et al.*, (2022) [21] found β -catenin expression in 47.7% of atypical EH. They suggested, β -catenin expression could be used as diagnostic adjunct in histopathological diagnosis of atypical EH.

In the present study, no methylation of APC gene was observed in the precancer cases, however, only one cancer case (1/13, 8%) showed APC promoter methylation. Ignatov *et al.*, (2010) [22] have reported APC gene methylation in 23.5% atypical EH, 56.9% of EEC which decreased stepwise (24.2%) in advanced stage of EC. Variation in the methylation status of APC gene in studies might be because of variable stage of disease progression, different age group and variability in the sampling.

CONCLUSION

The present study showed that expression of β -catenin was upregulated in EEC and precursor lesions suggesting involvement of Wnt/ β -catenin signaling from an early stage of development of cancer from precancer. The information might offer a potential therapeutic target for EEC and could also be used as a screening tool in endometrial hyperplasia cases for detecting potentially precancerous lesions.

Conflict of Interest: None

ACKNOWLEDGEMENT

Authors gratefully acknowledge the funding agencies; Indian Council of Medical Research (ICMR), New Delhi as contingency grants to Dr Sunita Yadav as post MD, PhD fellowship and Grant no. DHR/GIA/3/2014 funded by Department of Health and Research, Ministry of Health & family Welfare New Delhi.

REFERENCES

- Prat, J. (2004). Prognostic parameters of endometrial carcinoma. *Human pathology*, 35(6), 649-662. [10.1016/j.humpath.2004.02.007](https://doi.org/10.1016/j.humpath.2004.02.007)
- Bansal, N., Yendluri, V., & Wenham, R. M. (2009). The molecular biology of endometrial cancers and the implications for pathogenesis, classification, and targeted therapies. *Cancer control*, 16(1), 8-13. [10.1177/107327480901600102](https://doi.org/10.1177/107327480901600102)
- Fujimoto, T., Nanjyo, H., Fukuda, J., Nakamura, A., Mizunuma, H., Yaegashi, N., ... & Tanaka, T. (2009). Endometrioid uterine cancer: histopathological risk factors of local and distant recurrence. *Gynecologic oncology*, 112(2), 342-347. [10.1016/j.ygyno.2008.10.019](https://doi.org/10.1016/j.ygyno.2008.10.019)
- Balasubramaniam, G., Sushama, S., Rasika, B., & Mahantshetty, U. (2013). Hospital-based study of endometrial cancer survival in Mumbai, India. *Asian Pacific Journal of Cancer Prevention*, 14(2), 977-980.
- Cancer Today-Global cancer observatory. <https://gco.iarc.fr/today/home>. Last accessed on 12 Oct 2018.
- McMeekin, D. S., Yashar, C., & Campus, S. M. (2013). Corpus: Epithelial tumors. In: Principles and Practice of Gynecologic Oncology (eds. Barakat, R. R., Berchuk, A., Markman, M. M., Randall, M). 6th ed. Lippincott Williams & Wilkins; p.661-714.
- Münstedt, K., Grant, P., Woenckhaus, J., Roth, G., & Tinneberg, H. R. (2004). Cancer of the endometrium: current aspects of diagnostics and treatment. *World journal of surgical oncology*, 2(1), 1-17.
- Goad, J., Ko, Y. A., Kumar, M., Jamaluddin, M. F. B., & Tanwar, P. S. (2018). Oestrogen fuels the growth of endometrial hyperplastic lesions initiated by overactive

- Wnt/ β -catenin signalling. *Carcinogenesis*, 39(9), 1105-1116. doi:10.1093/carcin/bgy079
9. Wang, Y., van der Zee, M., Fodde, R., & Blok, L. J. (2010). Wnt/B-catenin and sex hormone signaling in endometrial homeostasis and cancer. *Oncotarget*, 1(7), 674-684.
 10. Jia, S., Wei, Y., Liu, H., Fu, J., Wang, F., & Zhang, Y. (2015). Signaling pathway in endometrial carcinoma. *Cancer Genetics and Epigenetics*, 3(3), 1-4.
 11. WHO Classification of Tumours Editorial Board. Female Genital Tumours. Lyon (France): International Agency for Research on Cancer; 2020. (WHO Classification of Tumours series, 5th ed: 4, 248-252. <http://publication.iarc.fr/592>).
 12. Nayak, S., Goel, M. M., Makker, A., Bhatia, V., Chandra, S., Kumar, S., & Agarwal, S. P. (2015). Fibroblast growth factor (FGF-2) and its receptors FGFR-2 and FGFR-3 may be putative biomarkers of malignant transformation of potentially malignant oral lesions into oral squamous cell carcinoma. *PLoS One*, 10(10), e0138801. [10.1371/journal.pone.0138801](https://doi.org/10.1371/journal.pone.0138801)
 13. Missaoui, N., Hmissa, S., Trabelsi, A., Traoré, C., Mokni, M., Dante, R., & Frappart, L. (2011). Promoter hypermethylation of CDH13, DAPK1 and TWIST1 genes in precancerous and cancerous lesions of the uterine cervix. *Pathology-Research and Practice*, 207(1), 37-42.
 14. Li, L. C., & Dahiya, R. (2002). MethPrimer: designing primers for methylation PCRs. *Bioinformatics*, 18(11), 1427-1431.
 15. Narita, F., Sato, A., Hamana, S., Deguchi, M., Otani, T., & Maruo, T. (2003). Simultaneous immunohistochemical localization of beta-catenin and cyclin D1 in differentiated but not in undifferentiated human endometrial carcinoma. *European journal of gynaecological oncology*, 24(2), 129-134.
 16. Norimatsu, Y., Moriya, T., Kobayashi, T. K., Sakurai, T., Shimizu, K., Tsukayama, C., & Ohno, E. (2007). Immunohistochemical expression of PTEN and β -catenin for endometrial intraepithelial neoplasia in Japanese women. *Annals of diagnostic pathology*, 11(2), 103-108.
 17. Shaco-Levy, R., Sharabi, S., Piura, B., & Sion-Vardy, N. (2008). MMP-2, TIMP-1, E-cadherin, and β -catenin expression in endometrial serous carcinoma compared with low-grade endometrial endometrioid carcinoma and proliferative endometrium. *Acta obstetrica et gynecologica Scandinavica*, 87(8), 868-874.
 18. Xiong, Y., Xiong, Y. Y., & Zhou, Y. F. (2009). Expression of beta-catenin, Glut-1, PTEN proteins in uterine endometrioid adenocarcinoma and its precursor lesions. *Zhonghua Bing li xue za zhi= Chinese Journal of Pathology*, 38(9), 594-599.
 19. Sal, V., Demirkiran, F., Erenel, H., Tokgozlu, N., Kahramanoglu, I., Bese, T., ... & Guralp, O. (2016). Expression of PTEN and β -catenin and their relationship with clinicopathological and prognostic factors in endometrioid type endometrial cancer. *International Journal of Gynecologic Cancer*, 26(3), 512-520. [10.1097/IGC.0000000000000626](https://doi.org/10.1097/IGC.0000000000000626)
 20. Travaglino, A., Raffone, A., Saccone, G., De Luca, C., Mollo, A., Mascolo, M., ... & Zullo, F. (2019). Immunohistochemical nuclear expression of β -catenin as a surrogate of CTNNB1 exon 3 mutation in endometrial cancer. *American Journal of Clinical Pathology*, 151(5), 529-538.
 21. Aguilar, M., Chen, H., Rivera-Colon, G., Niu, S., Carrick, K., Gwin, K., ... & Castrillon, D. H. (2022). Reliable identification of endometrial precancers through combined Pax2, β -catenin, and Pten immunohistochemistry. *The American Journal of Surgical Pathology*, 46(3), 404-414.
 22. Ignatov, A., Bischoff, J., Ignatov, T., Schwarzenau, C., Krebs, T., Kuester, D., ... & Schneider-Stock, R. (2010). APC promoter hypermethylation is an early event in endometrial tumorigenesis. *Cancer science*, 101(2), 321-327.