

# Analysis of Expression of Myofibroblast in Oral Squamous Cell Carcinoma Cases: A Case-Control Study

Dalvinder Singh<sup>1</sup>, Piyush Gandhi<sup>2\*</sup>

<sup>1</sup>Professor, Department of Anatomy, Faculty of Dentistry, Jamia Millia Islamia, Delhi- 110025, India

<sup>2</sup>Associate Professor, Department of oral pathology and microbiology, Dasmesh institute of research and dental sciences, Faridkot, Punjab, India

DOI: [10.36348/sjpm.2020.v05i04.005](https://doi.org/10.36348/sjpm.2020.v05i04.005)

| Received: 14.04.2020 | Accepted: 25.04.2020 | Published: 29.04.2020

\*Corresponding author: Dr. Piyush Gandhi

## Abstract

**Background:** In the past couple of decades, considerable importance has been given on the role of myofibroblasts (MFs) in tumour progression and prognosis. Myofibroblasts create a physical barrier between carcinoma cells and immune system of the body against cancer. Hence; the present study was undertaken for assessing the expression of myofibroblast in oral squamous cell carcinoma cases and comparing it with healthy controls. **Materials & Methods:** A total of 20 biopsy specimens of oral squamous cell carcinoma and 20 healthy controls were enrolled in the present study. Complete demographic details and clinical data of all the specimens were obtained from data records. Two sections were obtained from each specimen: one for staining immune-histo-chemically using  $\alpha$ -SMA antibody (alpha-smooth muscle actin antibody) and other for staining with haematoxylin and eosin. Criteria described by Etemad-Moghadam S et al were used for evaluating the expression of myofibroblast. Based on these criteria, staining index was graded as zero, moderate and high. Blood capillaries were taken as positive controls. Comparison was done in between the OSCC group and the control group. All the results were recorded in Microsoft excel sheet and were analysed by SPSS software. **Results:** In the OSCC group, 90 percent of the cases had high staining index of myofibroblast, while the remaining 10 percent of the cases had moderate staining index. In the control group, all the specimens showed negative staining index. While comparing statistically, it was observed that mean staining was significantly higher among OSCC group in comparison to the control group. **Conclusion:** Myofibroblast play a definitive role in the invasive behaviour of OSCC. Hence, it is suggested that myofibroblasts might be used as a stromal marker for observing the severity and progression of OSCC.

**Keywords:** Myofibroblast, Oral squamous cell carcinoma.

**Copyright © 2020:** This is an open-access article distributed under the terms of the Creative Commons Attribution license which permits unrestricted use, distribution, and reproduction in any medium for non-commercial use (NonCommercial, or CC-BY-NC) provided the original author and sources are credited.

## INTRODUCTION

In the past couple of decades, considerable importance has been given on the role of myofibroblasts (MFs) in tumour progression and prognosis. Results from different studies highlight that oral squamous cell carcinoma cases with highly increased MFs expression are associated with poor prognosis. This has become a well-known fact that the tumor microenvironment makes crucial contribution to tumor advancement. This micro-environment consists of numerous components; mainly activated fibroblast endothelial cells, inflammatory cells, and different extra cellular matrix components. Majority of these activated fibroblasts are  $\alpha$ -smooth muscle actin-positive myofibroblast which mostly symbolize the majority of tumor stromal cells. According to the data of past-literature, it has been evident that in more than half of the reported OSCC cases, myofibroblast constitute the micro-environment [1-3].

The tumor stroma in oral squamous cell carcinoma (OSCC) is associated with the secretion of various cytokines such as transforming growth factor beta-1 from cancerous cells that promote differentiation of fibroblasts into myofibroblasts, neo-angiogenesis, increases the inflammatory cells and increases the expression of mesenchymal markers such as vimentin. Myofibroblasts, in turn, causes tumor growth by the destruction of extra-cellular matrix (ECM) [4-6].

The tumor-promoting effect of myofibroblast is based on the direct cytokine stimulation of cancer cells, maintenance of vascularity and on their capacity to produce enzymes which degrade molecules like lysyl oxidase which enhance the structural integrity of matrix. Myofibroblasts create a physical barrier between carcinoma cells and immune system of the body against cancer.<sup>7, 8</sup> Hence; the present study was undertaken for assessing the expression of

myofibroblast in oral squamous cell carcinoma cases and comparing it with healthy controls.

## MATERIALS & METHODS

The present study was conducted for assessing the expression of myofibroblast in oral squamous cell carcinoma cases and comparing it with healthy controls. A total of 20 biopsy specimens of oral squamous cell carcinoma and 20 healthy controls were enrolled in the present study. Complete demographic details and clinical data of all the specimens were obtained from data records. Two sections were obtained from each specimen: one for staining immune-histo-chemically using  $\alpha$ -SMA antibody (alpha-smooth muscle actin antibody) and other for staining with haematoxylin and eosin. Criteria described by Etemad-Moghadam S et al were used for evaluating the expression of myofibroblast [7]. According to this criteria, myofibroblast staining was calculated based on product of percentage of immune-positive cells in the sub-epithelial zone (connective tissue) and level of magnification at which staining was visible. Based on these criteria, staining index was graded as zero, moderate and high. Blood capillaries were taken as positive controls. Comparison was done in between the OSCC group and the control group. All the results were recorded in Microsoft excel sheet and were analysed by SPSS software. Chi-square test was used for evaluation of level of significance.

## RESULTS

In the present study, a total of 20 OSCC specimens and 20 normal controls were analysed. Data records were analysed for obtaining the demographic and clinical details. Mean age of the OSCC cases and controls was found to be 49.2 respectively and 47.7 years respectively. Majority of the cases of both the study groups were males. In the OSCC group, 90 percent of the cases had high staining index of myofibroblast, while the remaining 10 percent of the cases had moderate staining index (Figure-1). In the control group, all the specimens showed negative staining index. While comparing statistically, it was observed that mean staining was significantly higher among OSCC group in comparison to the control group.

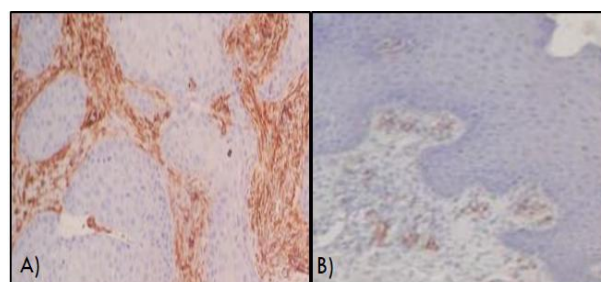


Fig-1: Expression of myofibroblast in A) OSCC specimens and B) Normal controls

Table-1: Comparison of staining index grade

Staining index	OSCC group		Control group		p- value
	Number	Percentage	Number	Percentage	
Zero	0	0	20	100	0.000 (Highly significant)
Moderate	2	10	0	0	
High	18	90	0	0	

## DISCUSSION

MFs are specific fibroblasts with smooth muscle-like characteristics. They are heterogeneous in nature and exhibit differential phenotype. MFs reveal numerous characteristic histologic traits like large, spindle-shaped stellate cells with long cytoplasmic extensions, amphophilic cytoplasm and indented nucleus with conspicuous nucleoli. But transmission electron microscopy remains the method of choice for identification of MFs. The occurrence of MFs in various lesions and conditions, their heterogeneous cytoskeletal composition and various functions, it makes it difficult to assume a common origin for these cells. Data from previous studies have shown that MFs play a crucial role in the pathogenesis of OSCC [9-11]. Hence; the present study was undertaken for assessing the expression of myofibroblast in oral squamous cell carcinoma cases and compares it with healthy controls.

In the present study, a total of 20 OSCC specimens and 20 normal controls were analysed. Data records were analysed for obtaining the demographic and clinical details. Mean age of the OSCC cases and

controls was found to be 49.2 respectively and 47.7 years respectively. Majority of the cases of both the study groups were males. In the OSCC group, 90 percent of the cases had high staining index of myofibroblast, while the remaining 10 percent of the cases had moderate staining index. Our results were in concordance with the results obtained by Prasad BV *et al.*, who also reported similar findings. They analysed the expression of MFs in OSCC specimens. Their study comprised of analysis of 20 well-differentiated OSCC (WDOSCC), 20 poorly differentiated OSCC (PDOSCC), and 10 normal healthy controls. All the specimens were stained immune-histo-chemically with monoclonal antihuman  $\alpha$ -SMA. The mean myofibroblasts score in their study among WDOSCC and PDOSCC specimens was found to be 2.88 and 2.92 respectively. They reported statistically significant results while comparing MF expression in between OSCC group and normal control group. However; they didn't observed any significant difference in the staining index in between different grades of OSCC. They concluded that malignant epithelium might induce the adjacent stromal tissue to produce myofibroblasts.

These specialized cells may be utilized as therapeutic targets for the treatment of OSCC [10].

In the control group, all the specimens showed negative staining index. While comparing statistically, it was observed that mean staining was significantly higher among OSCC group in comparison to the control group. Our results were also in concordance with the results obtained by Gandhi P *et al.*, who also analysed expression of MFs in OSCC and oral submucous fibrosis (OSMF) specimens and compared their expression with healthy controls. The presence of myofibroblasts was significantly higher in OSMF cases when compared with normal epithelium specimens. The presence of myofibroblasts was significantly higher in OSCC compared to OSMF cases. A significant difference was not observed between the different grades of OSCC. They concluded that OSMF might actually represent an abnormal healing process in response irritation caused by areca nut. A significant increase in myofibroblasts in OSCC as compared to OSMF also highlights the possible role it may play in the malignant transformation of OSMF [11]. Similar results were also observed by Lúcio PS et al who also reported similar findings in their meta-analysis. They performed a literature review on the origin of myofibroblasts, their main morpho-physiological and immunohistochemical aspects, and to discuss the correlations with oral SCC. They concluded that increased expression of MFs might be associated with local disease recurrence and decreased patient survival in OSCC patients [12]. In another study conducted by Ganesan K et al, authors compared the presence of myofibroblasts in normal mucosa, early invasive carcinoma and different grades of OSCC. Their findings showed that the genetically altered epithelium (carcinomatous epithelium) might have an inductive effect on the adjacent stroma to produce myofibroblasts [13].

## CONCLUSION

From the above results, the authors concluded Myofibroblast play a definitive role in the invasive behaviour of OSCC. Hence, it is suggested that myofibroblasts might be used as a stromal marker for observing the severity and progression of OSCC.

## REFERENCES

1. Bucala, R., Spiegel, L. A., Chesney, J., Hogan, M., & Cerami, A. (1994). Circulating fibrocytes define a new leukocyte subpopulation that mediates tissue repair. *Molecular medicine*, 1(1), 71-81.
2. Blazejewski, S., Preaux, A. M., Mallat, A., Brocheriou, I., Mavier, P., Dhumeaux, D., ... & Rosenbaum, J. (1995). Human myofibroblastlike cells obtained by outgrowth are representative of the fibrogenic cells in the liver. *Hepatology*, 22(3), 788-797.
3. Küffer, R., & Lombardi, T. (2002). Premalignant lesions of the oral mucosa. A discussion about the place of oral intraepithelial neoplasia (OIN). *Oral oncology*, 38(2), 125-130.
4. Kellermann, M. G., Sobral, L. M., da Silva, S. D., Zecchin, K. G., Graner, E., Lopes, M. A., ... & Coletta, R. D. (2008). Mutual paracrine effects of oral squamous cell carcinoma cells and normal oral fibroblasts: induction of fibroblast to myofibroblast transdifferentiation and modulation of tumor cell proliferation. *Oral oncology*, 44(5), 509-517.
5. Kalluri, R., & Neilson, E. G. (2003). Epithelial-mesenchymal transition and its implications for fibrosis. *The Journal of clinical investigation*, 112(12), 1776-1784.
6. Hinz, B., & Gabbiani, G. (2003). Mechanisms of force generation and transmission by myofibroblasts. *Current opinion in biotechnology*, 14(5), 538-546.
7. Etemad- Moghadam, S., Khalili, M., Tirgary, F., & Alaeddini, M. (2009). Evaluation of myofibroblasts in oral epithelial dysplasia and squamous cell carcinoma. *Journal of oral pathology & medicine*, 38(8), 639-643.
8. Kunz-Schughart, L. A., & Knuechel, R. (2002). Tumor-associated fibroblasts (part I): Active stromal participants in tumor development and progression?. *Histol Histopathol*, 17:599-621.
9. Eyden, B. (2008). The myofibroblast in health and disease. *Revista Española de Patología*, 41(1), 3-10.
10. Prasad, B. V., Kakatkar, G. S., Jain, P., Jain, M., Patel, M., & Khan, J. (2016). Expression of Myofibroblasts in Oral Squamous Cell Carcinoma: An Immunohistochemical Study. *The journal of contemporary dental practice*, 17(10), 857-860.
11. Gandhi, P., & Prasad, U. C. (2017). Evaluation of myofibroblasts in oral submucous fibrosis and oral squamous cell carcinoma: The pathogenesis and correlation. *Dental research journal*, 14(5), 314-320.
12. Lúcio, P. S. C., Cavalcanti, A. L., Alves, P. M., Godoy, G. P., & Nonaka, C. F. W. (2013). Myofibroblasts and their relationship with oral squamous cell carcinoma. *Brazilian Journal of otorhinolaryngology*, 79(1), 112-118.
13. Ganesan, K., Nirmal, R. M., Nassar, M. M., Veeravarmal, V., Amsaveni, R., & Kumar, A. (2015). Evaluation of myofibroblasts in oral squamous cell carcinoma using H1 calponin: An immunohistochemical study. *Journal of oral and maxillofacial pathology: JOMFP*, 19(1), 42.