

Tissue Microarray Based Immunohistochemical study of TLE1 in Synovial Sarcoma and its Histologic Mimics

Sunandalakshmi GV¹, Sujitha Chougani^{2*}, Durga Kharidehal³, Ravi Sankar V⁴, Santhi Vissa⁵

¹Assistant Professor, Department of pathology, Narayana Medical College, Nellore, Andhrapradesh, India

²Consultant Pathologist, Yashoda Hospital, Secunderabad, Telangana India

³Professor, Department of pathology, Narayana Medical College, Nellore, Andhrapradesh, India

⁴Assistant Professor, Department of Emergency Medicine, Narayana Medical College, Nellore, Andhrapradesh, India

⁵Professor and Head, Department of pathology, Narayana Medical College, Nellore, Andhrapradesh, India

DOI: [10.36348/sjpm.2020.v05i01.007](https://doi.org/10.36348/sjpm.2020.v05i01.007)

| Received: 20.01.2020 | Accepted: 27.01.2020 | Published: 30.01.2020

*Corresponding author: Sujitha Chougani

Abstract

Background: Synovial sarcoma is a translocation-associated mesenchymal neoplasm that represents around 10% of all soft tissue sarcomas. Diagnosing biphasic synovial sarcoma is generally straight forward, owing to distinctive histologic features. Transducer-like enhancer of split 1 (TLE1) is overexpressed in synovial sarcomas. Study aimed to evaluate sensitivity and specificity of TLE1 immunohistochemical expression in synovial sarcoma and its histological mimics.

Methods: Conventional sections from 30 cases of synovial sarcoma, 24 cases of monophasic synovial sarcoma mimics and 6 cases of poorly differentiated sarcoma mimics were subjected to TLE1 IHC staining. TLE1 immunostaining was graded from 0, 1+, 2+, 3+, with 2+ or 3+ grades interpreted as positive staining. **Results:** Of the 60 tumours, majority are monophasic spindle cell type (56.6%), followed by biphasic (16.6%), monophasic epithelial (6.6%), poorly differentiated (13.3%) and calcifying type (6.6%). Upon expression of TLE1 in tumors, 20 cases showed Grade 3, 8 cases shown Grade 2, 2 cases shown Grade 1 TLE1 Expression in Synovial sarcoma. 2 cases shown Grade 3 and 2 cases shown Grade 2 TLE1 expression in Schwannoma. Whereas 1 case shown grade 2 in Rhabdomyosarcoma. 1 case shown grade 2 in Hemangiopericytoma. TLE1 sensitivity for diagnosis of synovial sarcomas was 93.3%, and specificity of 73.3% with positive predictive value of 77.77% and negative predictive value of 91.6%. **Conclusion:** Specificity can be increased with optimal IHC panel which includes BCL2, Pan Cytokeratin, EMA, CD99 and CD34. Molecular confirmation is the diagnostic gold standard for synovial sarcoma, TLE1, in view of its high sensitivity may be a useful marker within the optimal IHC panel for substantiating a diagnosis of synovial sarcoma. Awareness of TLE1 expression in other tumours and its correct interpretation are necessary.

Keywords: Immunohistochemistry of synovial sarcoma, *TLE1*, Synovial sarcomas.

Copyright © 2020: This is an open-access article distributed under the terms of the Creative Commons Attribution license which permits unrestricted use, distribution, and reproduction in any medium for non-commercial use (NonCommercial, or CC-BY-NC) provided the original author and sources are credited.

INTRODUCTION

Synovial sarcoma (SS) is a mesenchymal tumour, which displays a variable degree of epithelial differentiation including gland formation, and has a specific chromosomal translocation t(X; 18) (p11; q11) that leads to formation of a SS18-SSX fusion gene [1-4]. It is the fourth most common high grade soft tissue sarcoma, accounts for 5-10% of all soft tissue sarcomas and is accompanied by an often poor prognosis with high chance of metastasis despite surgical resection. Local control requires wide local excision and radiation therapy, causing significant morbidity in relatively young patients. Histologically, synovial sarcoma is subtyped into biphasic SS, monophasic SS, poorly differentiated SS and calcifying type [5]. The diagnosis of biphasic synovial sarcoma is

generally straightforward, but the diagnosis of monophasic SS and poorly differentiated SS is challenging.

The diagnostic gold standard for synovial sarcoma is demonstration of the characteristic translocation between the *SS18* (*SYT*) gene on chromosome 18 and one of three *SSX* genes (*SSX1*, *SSX2*, or rarely *SSX4*) on chromosome X (t(X;18)(p11.2;q11.2)) [6,7]. Detection of t(X;18) can be accomplished by cytogenetic karyotyping, fluorescence in situ hybridization (FISH) or reverse-transcriptase polymerase chain reaction (RT-PCR), the use of these techniques is limited by many practical issues (cost, specialized equipment, availability). Thus, in practice the diagnosis of synovial sarcoma is usually

based on histological examination and immunohistochemistry.

Cytokeratin, EMA, CD99 and Bcl-2 are used to identify synovial sarcomas, but have limited specificity and sensitivity. Transducin-like enhancer of split 1 (TLE 1) gene is a member of the TLE gene family and involved in control of hematopoiesis, neuronal, and terminal epithelial differentiation [8-10]. TLE 1 competes with β -catenin, which plays an important role in Wnt/ β -catenin signaling pathway [11, 12]. Several studies analyzed TLE1 as a diagnostic immunohistochemical marker for synovial sarcoma [13-17]. The study done by Kosemehmetoglu *et al.* concludes that TLE1 immunohistochemistry may play a limited role in diagnosis of SS with sensitivity of 85% and specificity of 75% [18]. In the present study, we will evaluate immunohistochemical expression of TLE1 in synovial sarcoma and its histological mimics.

Study designed to evaluate sensitivity and specificity of TLE1 immunohistochemical expression in synovial sarcoma and its histological mimics and to

assess the value of TLE1 as a diagnostic marker in Synovial sarcoma.

MATERIAL AND METHODS

Study design

This is a prospective and retrospective study. Slides (H &E, special stains and IHC slides) and paraffin blocks were retrieved from surgical pathology archives of Department of Pathology at MNJIO & RCC. The study was approved by the institutional ethics committee. The study includes 30 cases of synovial sarcoma, 24 cases of monophasic synovial sarcoma mimics (2Leiomyosarcoma, 4 Gastrointestinal stromal tumour, 2 Hemangiopericytoma, 3Dermatofibrosarcomaprotuberans, 3 Fibrosarcoma, 3 MPNST, 2 Solitary fibrous tumour, 1 Malignant fibrous histiocytomaand 4 Schwannoma) and 6 cases of poorly differentiated sarcoma mimics (4 Ewing sarcomas and 1Rhabdomyosarcoma, 1Desmoplastic Small round cell tumor).The original H& E and IHC slides of all the cases were reviewed to confirm the diagnosis. The inclusion criteria for SS and its mimics included in the study are provided in Table 1.

Table-1: Inclusion criteria of synovial sarcoma and its histological mimics

Cases	Criteria
Synovial sarcoma (30)	Classic morphology, peripheral location, Bcl2 positivity with panCKand CD99 and or EMA positivity
Leiomyosarcoma (2)	Classic morphology, with both Desmin and SMA positivity
Gastrointestinal stromal tumour (4)	Classic morphology, with both CD117 and DOG1 positivity
Hemangiopericytoma (2)	Classic morphology, CNS/PNS location and CD34 positivity
Dermatofibrosarcoma protuberance (3)	Classic morphology and location
Fibrosarcoma (3)	Classic morphology
MPNST (3)	Classic morphology with background of Familial Neurofibromatosis
Schwannomas (4)	Classic morphology and S-100 positivity
Solitary fibrous tumour (2)	Classic morphology and CD34+
Ewing sarcoma (4)	Classic morphology, CD99 Positivity.
Rhabdomyosarcoma (1)	Classic morphology and myogenin positivity.
Desmoplastic small round cell tumor(1)	Classic morphology and location.
Malignant fibrous histiocytoma (1)	Classic morphology and Vimentin positivity.

Tissue microarray preparation

The original H&E section of the tumor are reviewed, representative areas were identified and marked on the corresponding tissue blocks. Care was taken, to avoid the area with necrosis and or hemorrhage. The tissue cores were extracted from the marked area and transferred into corresponding tissue block. Marked tissues were extracted from the donor block using Quick-Ray needle with 5mm tip. One core was taken per case subject to availability of material. Tissue cores were delivered into corresponding holes of the recipient block and each core was numbered appropriately. Recipient block was put in embedding mold with cutting section faced down and incubated at 60°C for 30 minutes. Then, recipient block was embedded; sections were cut at 4 μ m thickness and taken on to charged slides for H&E and for IHC studies.

Immunohistochemistry

IHC analysis was carried out on TMA blocks using TLE1 (1F5) Mouse Monoclonal Antibody (CELL MARQUE, USA). Concentrated working solution was diluted in 1 in 30 dilutions.

Immunohistochemistry technique

The IHC was performed by semi-automated immunostainer (i6000, Biogenex). Immunohistochemistry (IHC) was done by Poly HRP technique. To fix, the sections were kept at 60°C for 30min.Dewaxing was done in 3 changes of xylene followed by hydration in graded alcohol and water. Antigen retrieval was done by using pressure cooker in TRIS EDTA at pH 9.0. After cooling to room temperature, sections were washed with three changes of distilled water to replace TRIS EDTA gradually. Then the slides were rinsed in phosphate buffer saline thrice for 5 minutes each followed by immersion in 3% methanol H₂O₂ for 10min to block endogenous

peroxidase activity and treated with power block for 10 minutes to inhibit binding to non-specific sites. Sections were incubated with primary antibody (TLE 1) for 90min, then secondary antibody (super enhancer) for 20min and HRP-polymer for 30min. In between each of these above steps two rinses of PBS for 5minutes each were applied. The antigen-antibody complex was visualized by using DAB (diaminobenzidine) as chromogen for 7 min. Sections were counterstained with Harris' hemotoxylin for 1min. Then they were dehydrated through alcohol, cleared in xylene and mounted in DPX.

Positive control

Two cases showing SS18 break-apart by fluorescent in situ hybridization and showing positive staining with TLE 1 served as positive control.

Interpretation on IHC results

Nuclear immunoreactivity was graded as 0, 1+, 2+ and 3+ based on intensity and percentage of cells. More than 50% of the cells exhibit intense positivity which is visible with a 4X objective, was graded as 3+; 25-50% of the cells exhibiting intense positivity or more than 50% of the cells showing moderate intensity which is visible on 10X objective was graded as 2+; 5-25% of the cells with intense

positivity graded as 1+; less than 5% staining of tumour nuclei is graded as nil (0).

STATISTICS

Over all Sensitivity, Specificity, Positive Predictive value and Negative Predictive value of TLE 1 were calculated.

RESULTS

The study included a total of 60 cases; of which 30 are synovial sarcomas and 30 other benign and malignant mesenchymal tumors which can histologically mimic synovial sarcoma.

The complete demographic, clinical, histological characteristics and IHC results of synovial sarcoma included in the present study are summarized in Table 2, 3 and 4. The mean age of the patients is 30 years with male preponderance. Location wise majority are lower extremity tumors.

Of the included cases of SS, majority are monophasic spindle cell type (56.6%), followed by biphasic (16.6%), monophasic epithelial (6.6%), poorly differentiated (13.3%) and calcifying type (6.6%).

Table-2: Demography, clinical profile and the tumour characteristics of patients with synovial sarcoma

Total patients (n)	30
Age in median (range)	30 (13-68years)
M:F	1.7:1
SIZE in median (range)	6 (1cm to 30cm)
SITE	
Lower extremities	21 (70%)
Upper extremities	5 (16.6%)
Aryepiglottic fold	1 (3.3%)
Lung	1 (3.3%)
Mediastinum	1 (3.3%)
Urinary Bladder	1(3.3%)
Type	
Monophasic	19 (63.3%)
Biphasic	5 (16.6%)
Poorly differentiated	4 (13.3%)
Calcifying type	2(6.6%)
Recurrence	5 patients
Metastasis	1 patient (lung) Unilateral inguinal lymphnodes(2) Axillary lymphnode(1)

Table-3: Synovial sarcoma histological characteristics

Tumour patterns	Positive (n=30)	Percentage
Fascicles	22	73.3%
Hemangiopericytomatous	15	50%
Hyalinization	12	40%
Necrosis	10	33.3%
Calcification	10	33.3%
Myxoid changes	6	20%
Cystic degeneration	5	20%
Palisading	5	16.6%
Herringbone	3	10%
Ossification	1	3.3%

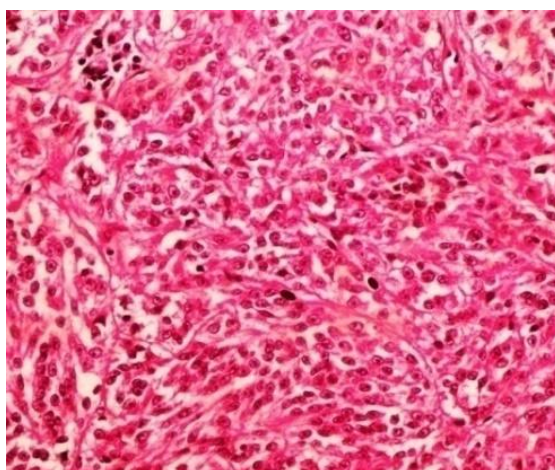
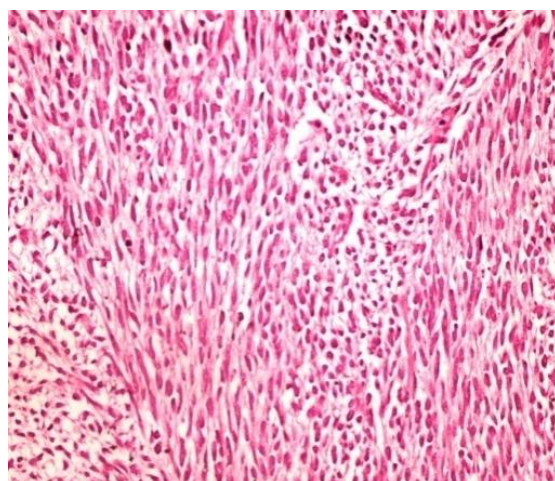
Table-4: Immunohistochemistry (IHC) results of patient with synovial sarcoma.

IHC marker	Done (n)	No. of Positive cases	% Positivity
BCL2	30	30	100%
EMA	28	26	92.8%
CK	25	17	68%
S 100	8	2	25%
CD 99	25	21	84%
Vimentin	12	10	83.3%
DOG1	3	-	0%
Desmin	3	-	0%
CD 34	5	-	0%
Myogenin	1	-	0%

IHC results of TLE1 immunostaining on TMA slides are summarized in Table 5. Grade 3+ and 2+ staining was taken as positive. Accordingly TLE 1 positivity was observed in 28/30 (93.3%) cases of synovial sarcoma. The other tumours which showed positivity include 3/4 (75%) GIST cases, 1/2 (50%) Hemangiopericytoma, 4/4 (100%) Schwannomas, 1/1 Rhabdomyosarcoma (100%). All cases of leiomyosarcoma, Ewing sarcoma, Dermatofibrosarcoma protuberans, Fibrosarcoma, MPNST, Malignant fibrous histiocytoma and Solitary fibrous tumor included in the study were negative for TLE 1. Accordingly TLE-1 showed a sensitivity of

93.3%, specificity of 73.3% with positive predictive value of 77.77% and negative predictive value of 91.6%.

Synovial sarcoma subtypes didn't show much difference in TLE 1 immunostaining (Table 6). In case of biphasic tumor, TLE-1 positivity was noted in both epithelial and mesenchymal component. Intensity of TLE1 positivity was more in epithelial than mesenchymal component (Foo et al). Back ground staining is not observed in any of the tumor.

**Fig-1: H&E 40X- Biphasic SS****Fig-2: H&E 40X Monophasic spindle SS**

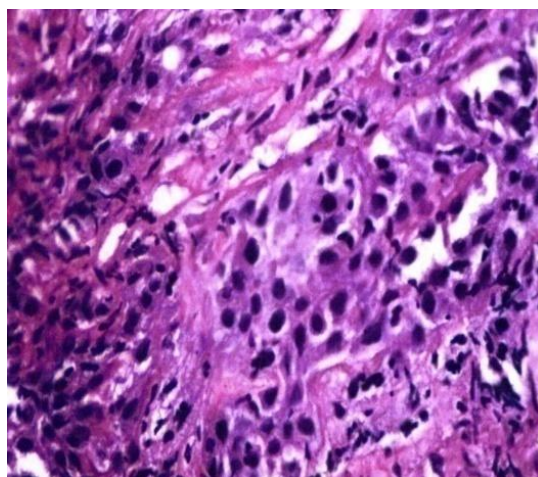


Fig-3: 40x Poorly differentiated

Table-5: Expression of TLE1 in tumors

Total number of cases (n=60)	TLE1 Expression			
	Grade 0	Grade 1	Grade 2	Grade 3
Synovial sarcoma(n=30)	0	2	8	20
Leiomyosarcoma(n=2)	2	0	0	0
Gastrointestinal stromal tumour (n=4)	0	1	2	1
Ewing sarcoma (n=4)	4	0	0	0
Hemangiopericytoma (n=2)	1	0	1	0
DFSP (n=3)	2	0	0	0
Fibrosarcoma (n=3)	3	0	0	0
MPNST (n=3)	2	1	0	0
Schwannoma (n=4)	0	0	2	2
Solitary fibrous tumour (n=2)	1	1	0	0
Rhabdomyosarcoma (n=1)	0	0	1	0
Desmoplastic small round cell tumor(1)	1	0	0	0
Malignant fibrous histiocytoma(1)	0	1	0	0

Table-6: TLE1 staining in synovial sarcoma subtypes

Types of synovial sarcoma (n=30)	TLE1 Expression			
	Grade 0	Grade 1	Grade 2	Grade 3
Monophasic SS(19)	0	1	5	13
Biphasic SS (5)	0	1	1	3
Poorly differentiated SS (4)	0	0	2	2
Calcifying type of SS (2)	0	0	1	1

DISCUSSION

Synovial sarcoma has wide anatomic distribution and variable histologic patterns, which create diagnostic difficulties [5]. Monophasic fibrous synovial sarcoma can be difficult to distinguish from its histological mimics which include other spindle cell sarcomas such as Malignant peripheral nerve sheath tumours, Cellular Schwannomas, Solitary fibrous tumour, Fibrosarcoma, DFSP, Haemangiopericytoma, Malignant fibrous histiocytoma, GIST and Leiomyosarcoma. Mimics of poorly differentiated synovial sarcoma include Ewings sarcoma, Desmoplastic small round cell tumor and Rhabdomyosarcoma. Though IHC is helpful in differentiation, in many cases there may be overlapping immunohistochemical results. Molecular analysis is gold standard for diagnosis of synovial sarcoma, but use of

these ancillary techniques is limited by many practical issues like cost and limited resources. Many attempts have been made to identify highly specific, sensitive marker for SS [19, 20]. Gene expression studies showed overexpression of TLE family genes, particularly TLE 1 in SS [21, 22].

Comparisons between our study and previous studies are summarized in Table 7. In the present study, sensitivity and specificity of TLE 1 for SS is 93.3% and 73.3% respectively which is similar to several other studies. The reported sensitivity in previous studies has ranged from 82-100% and specificity from 72-96%. Grading system for TLE1 positivity was similar to that followed by Terry *et al.*, Jagdis *et al.* and Rekhi *et al.* Our sensitivity was similar to these three studies. The other two studies by Kosemehmetoglu *et al.* [18] and

Foo *et al.* [15] showed lesser sensitivity. However all these studies employed different grading scheme to assess TLE1 positivity. In the present study the number of cases with grade 3+ (19/30; 64%) positivity was higher than grade 2+ positive cases (9/30; 30%) which is similar to that reported by Terry *et al.* and Rekhi *et al.* [13,17]. The remaining two TLE1 negative cases of SS in the present series were one MSS and one biphasic and both showed grade 1 staining. Though these 2 cases had classical morphology and IHC findings of SS, molecular confirmation was not done.

One of the limitations of present study compared to others was inclusion criteria for SS, which was mainly based on morphology and IHC findings, while others included molecularly confirmed cases. We tried to overcome this, by rigid morphological and IHC criteria. The correlation of our study results with that of other studies, further strengthens our inclusion criteria. The present study and that of Terry *et al.* [13] was carried out on tissue microarray, whereas the other studies used whole sections, however the results were well correlated. There was no significant difference in sensitivity for TLE1 among various histological types of SS included in present study, whereas Foo *et al.* observed higher sensitivity for PDSS (91%) when compared to overall sensitivity of SS (82%) [15].

The analysis of SS mimics showed a variation in the entities as well as number of cases included in different studies to analyze specificity of TLE 1. The positivity of MPNST to TLE 1 reported in previous studies ranges from 2.3-30%. In the present study all 3 were negative. Schwannomas have also shown wide range of positivity ranging from 0- 100%. In our study, there was 100% (4/4) positivity. TLE1 on GIST was done in two studies-Kosemehmetoglu *et al.* [18] and Rekhi *et al.* [17] in 6 and 1 cases respectively and were negative whereas Terry *et al.* [13] studied 35 cases and showed positivity in 6% of their cases. !! We studied 4 cases of GIST, of which 3 were positive & 1 negative for TLE1 and all 4 were CD117 and DOG1 positive thereby concluding them as GIST rather than SS. There were 4 cases of Ewing's sarcoma included in the present study which was TLE1 negative. Similar results were reported by many other studies as well, except for the study by Rekhi *et al.* [17], who demonstrated positivity in 40% of their cases. This could be due to different sensitivity of the antibody clone used. Of the 2 Haemangiopericytomas in the present study 1/2 cases (50%) had TLE1 positivity whereas Terry *et al.* [13] observed 40% positivity and is the only previous study to analyze TLE1 immunostaining in Haemangiopericytomas. The reported TLE1 positivity in leiomyosarcoma has been low ranging from 2- 20%. In present study, all the 2 cases were negative. All cases of Dermatofibrosarcoma protuberans and Fibrosarcoma were negative for TLE 1 in the present study as were seen in other studies. Analysis of TLE1 on

rhabdomyosarcoma was done in few previous studies. The reported TLE1 positivity in Rhabdomyosarcoma ranged from 0-100%. (Jagdis *et al.* 0%, Rekhi *et al.* 100% [17], 100% Kosemehmetoglu *et al.* [18]. In our study the single case was in comparison with Kosemehmetoglu and Rekhi *et al.* TLE1 on desmoplastic small round cell tumor was done in few previous studies. The reported TLE1 positivity in desmoplastic small round cell tumor was 0%. (Rekhi *et al.* 0% [17], 0% in Kosemehmetoglu *et al.* [18] including our study. Analysis of TLE 1 on malignant fibrous histiocytoma was negative in literature, similar to our single case.

We observed that most of the tumour (SS mimics) other than SS showed less intensity of positivity to TLE1. Chaung *et al.* also observed the same and concluded that, grading could differentiate SS from its mimics [23]. Negative predictive value of TLE 1 is 100% in study done by Jagdis *et al.* In the present study Negative Predictive Value is 91.6% which is close to the previous study whereas the Positive Predictive Value in this study is 77.7% which is much less when compared to Jagdis *et al.* [14] (92%) study.

Microscopic pictures of TLE1 immunostaining

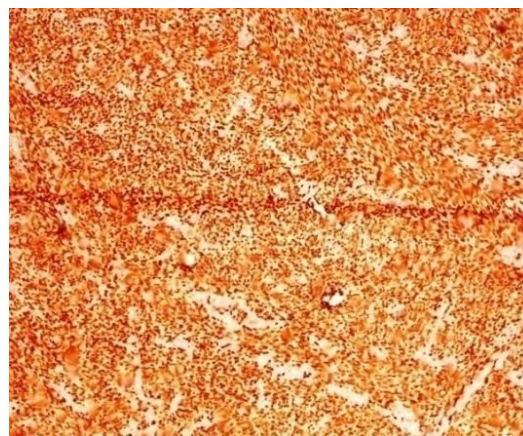


Fig-04: 10x TLE1 Grade 3

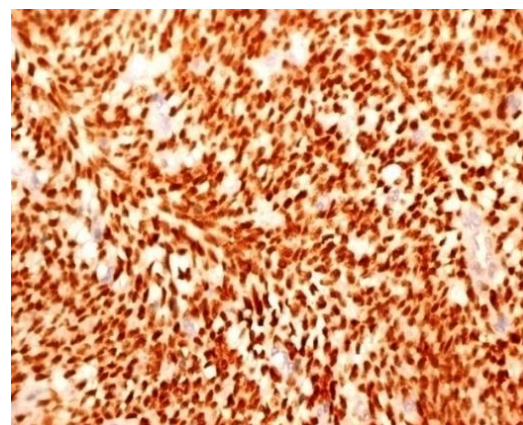


Fig-05: 40 xs

Table-7: Comparison between present study and previous studies

Variables	Terry et al. 2007	Kosemehmetoglu et al. 2009	Jagdis et al. 2009	Foo et al. 2011	Rekhi et al. 2012	Present study, 2015
Cases (SS+Mimics)	693 (94+599)	163 (20+143)	108 (35+73)	212 (73+139)	112 (42+70)	60 (30+30)
Inclusion criteria for SS	Molecularly Confirmed	MSS & PDSS – Molecularly proven	Molecularly proven	Molecularly proven	21 cases – Morphology & IHC only 21 cases – Molecularly proven	30 cases- Morphology and IHC 2 cases – Molecularly confirmed
Inclusion criteria of mimics	MPNST in background of NF	NM	NM	MPNST in background of NF and S-100 Ewings sarcoma - molecularly proven	Ewings sarcoma- molecularly proven	MPNST in background of NF and S-100.
Sections	TMA	Whole section	Whole section	Whole section	Whole section	TMA
Antibody	Polyclonal rabbit (M101) & Monoclonal anti-pan-TLE (Santa Cruz, USA)	TLE 1 (sc-9121) (Santa Cruz, USA)	Polyclonal rabbit (M101)(Santa Cruz, USA)	Polyclonal rabbit (M101)(Santa Cruz, USA)	Polyclonal rabbit (Abcam,USA)	Mouse monoclonal Antibody (Cell Marque, USA)
Criteria for grading	Percentage and intensity (0, 1+, 2+, 3+)	Percentage of cells (0, 1+, 2+, 3+)	Percentage and intensity (0, 1+, 2+, 3+)	Intensity and percentage of cells evaluated separately	Percentage and intensity (0, 1+, 2+, 3+)	Percentage and intensity (0, 1+, 2+, 3+)
Sensitivity	97%	85%	100%	82%	95.2%	93.33%
Specificity	-	75%	96%	92%	72%	73.3%
MSS	NM	NM	NM	18/25 (72%)	NM	18/19 (94.7%)
BSS	NM	NM	NM	22/28 (78.6%)	NM	4/5 (80%)
PDSS	4/4 (100%)	NM	NM	20/22 (90.9%)	NM	4/4 (100%)
Calcifying type of SS	NM	NM	NM	NM	NM	2/2 (100%)
MPNST	4/88 (5%)	3/10 (30%)	1/43 (2.3%)	7/47 (15%)	2/12 (16.6%)	0/3(0%)
Schwannomas	5/16 (31%)	9/11 (82%)	0/1 (0%)	ND	5/5 (100%)	4/4 (100%)
SFT	4/15 (27)	1/5 (20%)	ND	1/1 (100%)	0/1 (0%)	0/2 (0%)
Fibrosarcoma	0/3 (0%)	0/3 (0%)	1/1 (100%)	ND	0/1 (0%)	0/3(0%)
Ewing sarcoma	1/13 (8%)	0/4 (0%)	0/2 (0%)	0/23 (0%)	4/10 (40%)	0/4(0%)
HPC	2/5 (40%)	ND	ND	ND	ND	1/2 (50%)
GIST	2/35 (6%)	0/6 (0%)	ND	ND	0/1 (0%)	3/4 (75%)
RMS	ND	39/39(100%)	0/1(0%)	ND	2/2(100%)	1/1 (100%)
LMS	1/41 (2%)	1/5 (20%)	ND	ND	1/5 (20%)	0/2 (0%)
DFSP	0/17 (0%)	ND	0/5 (0%)	0/20 (0%)	0/1 (0%)	0/3 (0%)
MFH	0/56(0%)	ND	0/1(0%)	ND	ND	0/1(0%)
DSRCT	0/4(0%)	0/1(0%)	ND	ND	0/1(0%)	0/1(0%)

Abbreviations: NM – Not mentioned; ND – Not done; MSS- monophasic synovial sarcoma; BSS- Biphasic synovial sarcoma; PDSS- poorly differentiated synovial sarcoma, MPNST- malignant peripheral nerve sheath tumour, SFT- solitary fibrous tumour, HPC- haemangiopericytoma, LMS- leiomyosarcoma, DFSP- dermatofibrosarcoma protuberance, RMS- rhabdomyosarcoma, MFH-malignant fibrous histiocytoma.

CONCLUSION

TLE 1 is a sensitive marker for synovial sarcoma. Specificity can be increased with optimal IHC panel which includes BCL2, Pan Cytokeratin, EMA, CD99 and CD34. Although molecular confirmation remains the gold standard, immunohistochemical studies for TLE1 along with other IHC markers are valuable in differential diagnosis, especially when access to molecular testing is limited. Awareness of TLE1 expression in other tumours, leading to its limited

specificity, as well as its correct interpretation are necessary.

REFERENCES

1. Dimitriadis, E., Rontogianni, D., Kyriazoglou, A., Takou, A., Frangia, K., Pandis, N., & Trangas, T. (2009). Novel SYT–SSX fusion transcript variants in synovial sarcoma. *Cancer genetics and cytogenetics*, 195(1), 54-58.
2. Takenaka, S., Ueda, T., Naka, N., Araki, N., Hashimoto, N., Myoui, A., ... & Iwamoto, Y. (2008). Prognostic implication of SYT-SSX fusion type in synovial sarcoma: a multi-institutional retrospective analysis in Japan. *Oncology reports*, 19(2), 467-476.
3. Sun, B., Sun, Y., Wang, J., Zhao, X., Zhang, S., Liu, Y., ... & Hao, X. (2008). The diagnostic value of SYT- SSX detected by reverse transcriptase–polymerase chain reaction (RT- PCR) and fluorescence in situ hybridization (FISH) for

- synovial sarcoma: A review and prospective study of 255 cases. *Cancer science*, 99(7), 1355-1361.
4. Amary, M. F. C., Berisha, F., Bernardi, F. D. C., Herbert, A., James, M., Reis-Filho, J. S., ... & Flanagan, A. M. (2007). Detection of SS18-SSX fusion transcripts in formalin-fixed paraffin-embedded neoplasms: analysis of conventional RT-PCR, qRT-PCR and dual color FISH as diagnostic tools for synovial sarcoma. *Modern pathology*, 20(4), 482-496.
 5. Bergh, P., Meis-Kindblom, J. M., Gherlinzoni, F., Berlin, Ö., Bacchini, P., Bertoni, F., ... & Kindblom, L. G. (1999). Synovial sarcoma: identification of low and high risk groups. *Cancer*, 85(12), 2596-2607.
 6. Chang, C. C., & Shidham, V. B. (2003). Molecular genetics of pediatric soft tissue tumors: clinical application. *The Journal of molecular diagnostics*, 5(3), 143-154.
 7. Coindre, J. M., Pelmus, M., Hostein, I., Lussan, C., Bui, B. N., & Guillou, L. (2003). Should molecular testing be required for diagnosing synovial sarcoma? A prospective study of 204 cases. *Cancer*, 98(12), 2700-2707.
 8. Liu, Y., Dehni, G., Purcell, K. J., Sokolow, J., Carcangiu, M. L., Artavanis-Tsakonas, S., & Stifani, S. (1996). Epithelial Expression and Chromosomal Location of Human TLE Genes: Implications for Notch Signaling and Neoplasia. *Genomics*, 31(1), 58-64.
 9. Stifani, S., Blaumueller, C. M., Redhead, N. J., Hill, R. E., & Artavanis-Tsakonas, S. (1992). Human homologs of a Drosophila Enhancer of split gene product define a novel family of nuclear proteins. *Nature genetics*, 2(2), 119-127.
 10. Chen, G., Courey, A.J. (2000). Groucho/TLE family proteins and transcriptional repression. *Gene*, 249(1-2):1-16.
 11. Baird, K., Davis, S., Antonescu, C.R., Harper, U.L., Walker, R.L., Chen, Y. (2005). Gene expression profiling of human sarcomas: insights into sarcoma biology. *Cancer research*, 65(20):9226-35.
 12. Pretto, D., Barco, R., Rivera, J., Neel, N., Gustavson, M.D., Eid, J.E. (2006). The synovial sarcoma translocation protein SYT-SSX2 recruits beta-catenin to the nucleus and associates with it in an active complex. *Oncogene*, 25(26):3661-9.
 13. Terry, J., Saito, T., Subramanian, S., Ruttan, C., Antonescu, C.R., Goldblum, J.R. (2007). TLE1 as a diagnostic immunohistochemical marker for synovial sarcoma emerging from gene expression profiling studies. *The American journal of surgical pathology*, 31(2):240-6.
 14. Jagdis, A., Rubin, B. P., Tubbs, R. R., Pacheco, M., & Nielsen, T. O. (2009). Prospective evaluation of TLE1 as a diagnostic immunohistochemical marker in synovial sarcoma. *The American journal of surgical pathology*, 33(12), 1743-1751.
 15. Foo, W. C., Cruise, M. W., Wick, M. R., & Hornick, J. L. (2011). Immunohistochemical staining for TLE1 distinguishes synovial sarcoma from histologic mimics. *American journal of clinical pathology*, 135(6), 839-844.
 16. Knösel, T., Heretsch, S., Altendorf-Hofmann, A., Richter, P., Katenkamp, K., Katenkamp, D., ... & Petersen, I. (2010). TLE1 is a robust diagnostic biomarker for synovial sarcomas and correlates with t (X; 18): analysis of 319 cases. *European Journal of Cancer*, 46(6), 1170-1176.
 17. Rekhi, B., Basak, R., Desai, S. B., & Jambhekar, N. A. (2012). Immunohistochemical validation of TLE1, a novel marker, for synovial sarcomas. *The Indian journal of medical research*, 136(5), 766.
 18. Kosemehmetoglu, K., Vrana, J. A., & Folpe, A. L. (2009). TLE1 expression is not specific for synovial sarcoma: a whole section study of 163 soft tissue and bone neoplasms. *Modern pathology*, 22(7), 872-878.
 19. Folpe, A. L., Schmidt, R. A., Chapman, D., & Gown, A. M. (1998). Poorly differentiated synovial sarcoma: immunohistochemical distinction from primitive neuroectodermal tumors and high-grade malignant peripheral nerve sheath tumors. *The American journal of surgical pathology*, 22(6), 673-682.
 20. Pelmus, M., Guillou, L., Hostein, I., Sierankowski, G., Lussan, C., & Coindre, J. M. (2002). Monophasic fibrous and poorly differentiated synovial sarcoma: immunohistochemical reassessment of 60 t (X; 18)(SYT-SSX)-positive cases. *The American journal of surgical pathology*, 26(11), 1434-1440.
 21. Allander, S. V., Illei, P. B., Chen, Y., Antonescu, C. R., Bittner, M., Ladanyi, M., & Meltzer, P. S. (2002). Expression profiling of synovial sarcoma by cDNA microarrays: association of ERBB2, IGFBP2, and ELF3 with epithelial differentiation. *The American journal of pathology*, 161(5), 1587-1595.
 22. Nielsen, T. O., West, R. B., Linn, S. C., Alter, O., Knowling, M. A., O'Connell, J. X., ... & Brown, P. O. (2002). Molecular characterisation of soft tissue tumours: a gene expression study. *The Lancet*, 359(9314), 1301-1307.
 23. Chuang, H. C., Hsu, S. C., Huang, C. G., Hsueh, S., Ng, K. F., & Chen, T. C. (2013). Reappraisal of TLE-1 immunohistochemical staining and molecular detection of SS 18-SSX fusion transcripts for synovial sarcoma. *Pathology international*, 63(12), 573-580.