

## Molecular Tumor Markers (CD68, CK) In Detecting Good Prognostic Phenotypes of Breast Carcinoma

Dr. P. Subhashini<sup>1\*</sup>, Dr. M. Preethi<sup>2</sup>, Dr. Hemalatha Ganapathy<sup>3</sup>

<sup>1</sup>Assistant Professor Department of pathology, Sree Balaji Medical Collage & Hospital, 7, Works Road, Shankar Nagar, Chromepet, Chennai, Tamil Nadu, India

<sup>2</sup>Senior Resident of Department of pathology, Sree Balaji Medical collage & Hospital, 7, Works Road, Shankar Nagar, Chromepet, Chennai, Tamil Nadu, India

<sup>3</sup>Professor, Department of Pathology, Sree Balaji Medical College, 7, Works Road, Shankar Nagar, Chromepet, Chennai, Tamil Nadu, India

\*Corresponding author: Dr. P. Subhashini

| Received: 05.01.2019 | Accepted: 05.02.2019 | Published: 08.02.2019

DOI: [10.21276/sjpm.2019.4.2.1](https://doi.org/10.21276/sjpm.2019.4.2.1)

### Abstract

**Introduction:** Breast cancer is the most common malignancy in women, accounting for 56% of all female tumors. it is one of the leading causes of death in female. Metaplastic carcinoma is another rare carcinoma, with incidence accounting for 3-6 % of breast carcinoma. Early treatment management has better prognosis. **Aim:** To detect the importance of immunohistochemistry studies in detecting breast carcinoma. **Material and Methods:** Among 75 total mastectomy specimens received in Sree Balaji Medical College in department of Pathology 57 cases reported as ductal carcinoma insitu, Metaplastic carcinoma 5 cases, Papillary carcinoma 10 cases and Neuroendocrine carcinoma 3 cases. Among 5 Metaplastic carcinoma cases, Immunohistochemistry staining was done with tumor marker CD68 and CK to find the expression of the markers in tumor cell and to find rare variants in the carcinoma. **Results:** Out of 5 cases of metaplastic carcinoma of breast, 3 cases were positive for CD68 and CK. CD68 and CK has a sensitivity of 86% and specificity 80% in detecting variants in breast carcinoma. **Conclusion:** Molecular genetic analysis should be done in breast carcinoma in large number of cases to know the onset of this rare variant and early treatment management gives better prognosis.

**Keywords:** Breast carcinoma, Immunohistochemistry.

**Copyright @ 2019:** This is an open-access article distributed under the terms of the Creative Commons Attribution license which permits unrestricted use, distribution, and reproduction in any medium for non-commercial use (NonCommercial, or CC-BY-NC) provided the original author and sources are credited.

### INTRODUCTION

Breast cancer is the most common malignancy in women, accounting for 56% of all female tumors. It is one of the leading causes of death in female. Metaplastic carcinoma is another rare carcinoma, with incidence accounting for 3-6 % of breast carcinoma. Early treatment management have better prognosis

#### Objectives

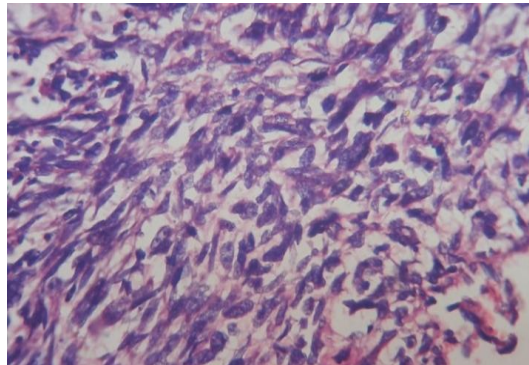
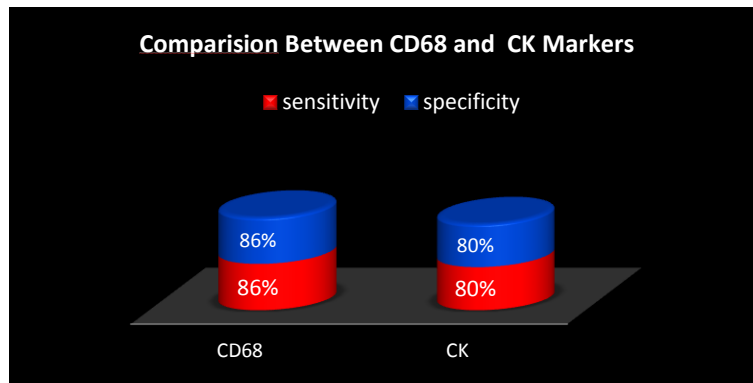
- To detect the importance of immunohistochemistry studies in detecting breast carcinoma.
- To find the incidence and prognostic value of IHC in breast carcinoma

### MATERIALS AND METHODS

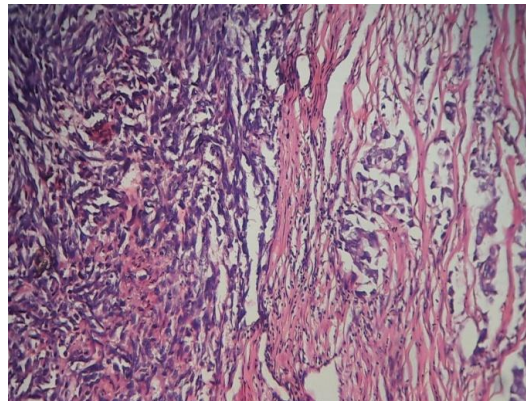
Among 75 total mastectomy specimens received in Sree Balaji Medical College in department of Pathology 57 cases reported as ductal carcinoma insitu, Metaplastic carcinoma 5 cases, Papillary carcinoma 10 cases and Neuroendocrine carcinoma 3 cases. Among 5 Metaplastic carcinoma cases, Immunohistochemistry staining was done with tumor marker CD68 and CK to find the expression of the markers in tumor cell and to find rare variants in the carcinoma.

### RESULTS

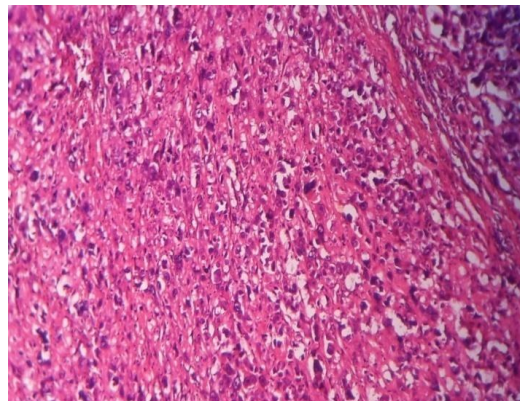
Out of 5 cases of metaplastic carcinoma of breast, 3 cases were positive for CD68 and CK. CD68 and CK has a sensitivity of 86% and specificity 80% in detecting variants in breast carcinoma.



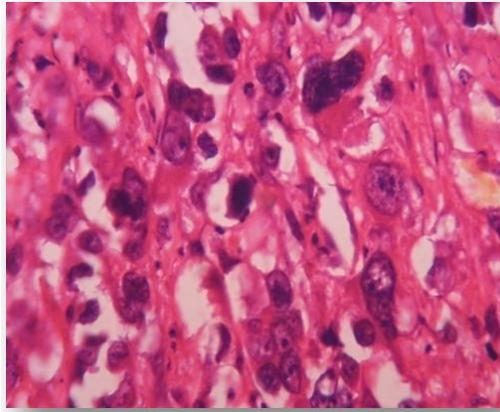
**Fig-1: Shows Spindle cell component with elongated cells, hyperchromatic and pleomorphic nuclei with mitotic figures, arranged in fascicles and interlacing bundles**



**Fig-2: Shows spindle cell component and adenocarcinoma component in breast (arrow points out adenocarcinoma region)**



**Fig-3: Shows Cellular neoplasm composed of round to oval cells with hyperchromatic, pleomorphic and prominent nucleoli arranged in islands, sheets and cords infiltrating the stroma**



**Fig-4: Immunohistochemistry staining showing CK and CD 68 positive in the sarcomatous component**

## DISCUSSION

Metaplastic carcinoma of breast is a rare variant. It includes giant cell variant, which has both sarcomatous and adenocarcinoma region [1]. CD68 is a tumor marker which is expressed on macrophages and monocytes, KP-1 is important for identifying macrophages in tissue sections. It stains macrophages in a wide variety of human tissue, including Kupffer cells and macrophage. KP-1 reacts with myeloid precursor and peripheral blood granulocytes [2]. It also reacts with plasmacytoid T cells which are supposed to be of monocyte and macrophages origin. It shows strong granular cytoplasmic staining of chronic and acute leukemia and also reacts with rare cases of true histiocytic neoplasia. CK is a cytoplasmic intermediate filament protein expressed on most ductal and glandular epithelium including lung, breast, bladder and female genital tract. The restricted expression of CK in some epithelium makes it useful in identify the organ origin of adenocarcinoma when combined with staining cytokeratin. In our studies we have identified the giant cell variants in the metaplastic carcinoma which is a rare variant with tumor marker positivity expression CD68 and CK [3, 4]. In our study Immunohistochemistry showed expression of  $\alpha$ -smooth muscle actin immunoreactivity and MMP-13 mRNA in myofibroblasts. In contrast, cytokeratin-positive cancer cells,  $\alpha$ -smooth muscle actin-positive vascular smooth muscle cells, CD68-positive macrophages. In our study the tumor marker expression showed a sensitivity and specificity 86% and 80% [5, 6]. According to Chhieng C and Cranor study showed 76% sensitivity and 70% positivity in expression of the tumor marker in the metaplastic carcinoma. According to Herrington CS and Buley conducted a study in Chicago showed a sensitivity of 75% and specificity of 68% in tumor marker expression [7, 8]. According to Meis J. M., and Ordóñez NG showed a sensitivity of 68% and specificity of 60% in the studies

## CONCLUSION

Molecular genetic analysis should be done in breast carcinoma in large number of cases to know the

onset of this rare variant and early treatment management gives better prognosis.

## REFERENCES

1. Chhieng, C., Cranor, M., Lesser, M. E., & Rosen, P. P. (1998). Metaplastic carcinoma of the breast with osteocartilaginous heterologous elements. *The American journal of surgical pathology*, 22(2), 188-194.
2. Herrington, C. S., Tarin, D., Buley, I., & Athanasou, N. (1994). Osteosarcomatous differentiation in carcinoma of the breast: a case of 'metaplastic' carcinoma with osteoclasts and osteoclast-like giant cells. *Histopathology*, 24(3), 282-285.
3. Meis, J. M., Ordóñez, N. G., & Gallager, H. S. (1987). Sarcomatoid carcinoma of the breast: an immunohistochemical study of six cases. *Virchows Archiv A*, 410(5), 415-421.
4. Oberman, H. A. (1987). Metaplastic carcinoma of the breast. A clinicopathologic study of 29 patients. *The American journal of surgical pathology*, 11(12), 918-929.
5. Tavassoli, F. A., & Norris, H. J. (1986). Breast carcinoma with osteoclastlike giant cells. *Archives of pathology & laboratory medicine*, 110(7), 636-639.
6. Wada, H., Enomoto, T., Tsujimoto, M., Nomura, T., Murata, Y., & Shroyer, K. R. (1998). Carcinosarcoma of the breast: molecular-biological study for analysis of histogenesis. *Human pathology*, 29(11), 1324-1328.
7. Chhieng, C., Cranor, M., Lesser, M. E., & Rosen, P. P. (1998). Metaplastic carcinoma of the breast with osteocartilaginous heterologous elements. *The American journal of surgical pathology*, 22(2), 188-194.
8. Leddy, R., Irshad, A., Rumboldt, T., Cluver, A., Campbell, A., & Ackerman, S. (2012). Review of metaplastic carcinoma of the breast: imaging findings and pathologic features. *Journal of clinical imaging science*, 2.