

Unique Case of Primary Malignant Melanoma arising in an Ovarian Cystic Teratoma: A Diagnostic and Therapeutic Challenge

Dr. Priyanka Anand^{1*}, Dr. Namrata Sarin²

¹M.D Senior Resident, Department of Pathology, NDMC and Hindu Rao hospital, New Delhi, India

²M.D Head of Department, Department of Pathology, NDMC and Hindu Rao hospital, New Delhi, India

Case Report

*Corresponding author

Dr. Priyanka Anand

Article History

Received: 14.06.2018

Accepted: 22.06.2018

Published: 30.06.2018

DOI:

10.21276/sjpm.2018.3.6.5



Abstract: Mature cystic teratomas comprise of 10-20% of ovarian neoplasms. Malignant transformation in a dermoid cyst occurs in 0.17-2% of cases. Primary ovarian melanoma arising in a dermoid cyst is an extremely rare entity. It must be differentiated from a metastatic melanoma which is more common. A fifty nine year old female presented with lower abdominal pain and heaviness. A right adnexal mass was noted on Computed tomography (CT) scan. Left ovary and uterus were normal. She underwent a right salpingo-oophorectomy. Histopathological examination along with immunohistochemical analysis and clinical correlation serves the diagnostic purpose and surgery with adequate margin clearance plays an important role in management. We report a rare case of primary malignant melanoma arising in a mature cystic teratoma.

Keywords: Mature cystic teratoma, primary ovarian, malignant melanoma.

INTRODUCTION

Mature teratomas comprise of 10-20% of ovarian neoplasms [1]. Malignant transformation in a dermoid cyst occurs in 0.17-2% of cases[2]. Most common malignancies arising in a teratoma are squamous cell carcinoma (88%), adenocarcinoma, fibrosarcoma, carcinoid tumor and mixed tumors. Malignant melanoma is a very rare transformation occurring in an ovarian teratoma[3].

Melanomas of the genital tract usually involve vulva or vagina. Other sites are cervix and ovary[4]. Usually ovarian melanomas arise in a cystic teratoma.

For the diagnosis of primary ovarian melanoma Boughton et al, Cronje and Woodruff proposed a criteria including four features [5,6]: 1) no other possible sites of a primary tumor 2) unilateral tumor within the ovarian teratoma 3) good correlation of age and symptoms of the patient with those cases documented in literature 4) demonstration of junctional activity.

It must be differentiated from a metastatic melanoma which is more common. In cases of metastatic carcinomas, the patient has a past history of malignant melanoma and in the ovary there is an absence of benign cystic teratoma[5]. Prognosis is unfavourable and prognostic factors are negative resected margins and stage at the time of diagnosis[7]. We report a case of primary malignant melanoma of the ovary arising in a mature cystic teratoma.

CASE PRESENTATION

A fifty nine year old female presented with a three months history of lower abdominal pain and heaviness. A 10x2 cm solid-cystic, right adnexal mass was noted on Computed tomography (CT) scan. Left

ovary and uterus were normal. Cancer antigen-125 was performed which was normal. The patient underwent a right salpingo-oophorectomy. The specimen was sent for histopathological examination. On gross examination, ovary was 10x6x2.5cm, tan-yellow with multiloculated cysts filled with clear watery fluid and few cysts contained pultaceous material with hair. A solid area measuring 0.5x0.5cm was also identified which on cut section was smooth tan- brown in appearance. On microscopic examination, cyst was lined by stratified squamous epithelium along with respiratory epithelium. The findings were diagnostic of a mature cystic teratoma. The tan-brown solid area was composed of groups of tumor cells. These cells showed pleomorphic oval to spindle cells with vesicular nuclei, prominent large eosinophilic nucleoli and eosinophilic cytoplasm containing abundant brown pigment to be melanin. Cells stained positive for HMB-45 and S100. A provisional diagnosis of melanoma arising within a teratoma was given. Patient was advised hysterectomy with a left salpingo-oophorectomy and a pelvic clearance.

Radiologic imaging with CT followed by PET was done to assess distant metastasis. Gall bladder, liver and spleen were of normal appearance. There was no evidence of retroperitoneal lymphadenopathy. Other primary sites for melanoma such as skin, intestine and eye were examined all of which were normal. Ascitic and peritoneal fluid were also negative for malignant cells.

Malignant melanoma arising in unilateral ovary associated with teratoma fulfilled the main criteria established by Boughton et al, Cronje and Woodruff [6] for diagnosis of primary malignant melanoma of ovary occurring in associated dermoid cyst.

Post-operative period was uneventful. Patient has received two cycles of chemotherapy (dacarbazine) and is currently under follow up period.

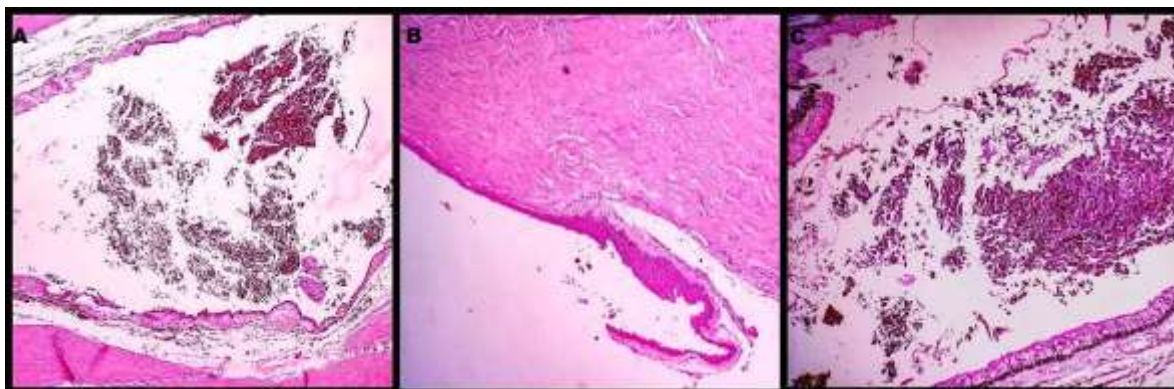


Fig-1(A): Microphotograph showing low power view of the cyst and a tumor component within the cyst wall. (H&E stain, 4x), **(B):** Microphotograph of mature cystic teratoma component showing cyst lined by stratified squamous epithelium and **(C)** shows cyst lined by pseudostratified epithelium along with melanoma component dispersed within the cyst, comprising of tumor cells arranged in a sheet like pattern. (H&E stain, 10x)

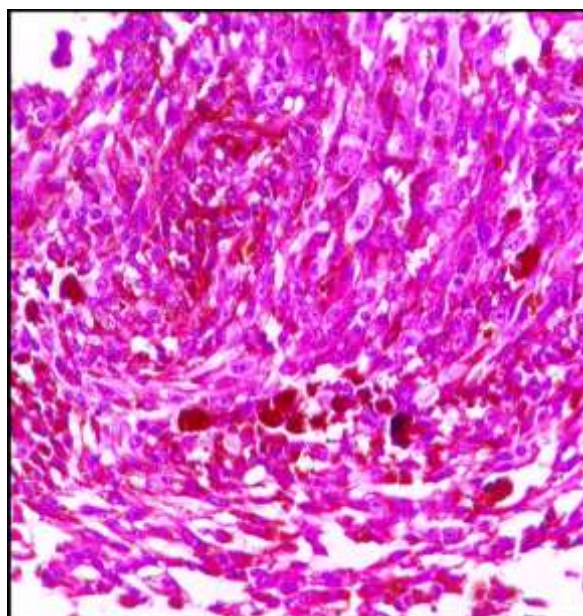


Fig-2: Microphotograph shows tumor cells showing nuclear pleomorphism with oval to spindle vesicular nuclei, prominent large nucleoli and eosinophilic cytoplasm containing abundant melanin pigment. (HE stain, 40x)

DISCUSSION

Mature cystic teratoma comprises of 10-20% of all ovarian tumors[8]. It consists of derivations from atleast two of the three germ cell layers.

Malignant melanomas in ovary are mostly metastatic than primarily occurring.^[5] Primary melanomas of ovary arise due to malignant

transformation in a mature cystic teratoma having an incidence of only 0.2-2% [3].

Most common malignancy that can arise in a dermoid cyst ovary is squamous cell carcinoma. Others include adenocarcinoma, fibrosarcoma, carcinoid tumor or mixed tumors. Malignant melanoma is the rarest tumor arising in an ovarian teratoma with an estimated

incidence of less than 1%[9]. Therefore the possibility of metastasis should always be ruled out[5].

Ovarian melanoma can be isolated or can be present in association with other types of ovarian carcinoma as reported in the literature[7].

In our case, there was no extraovarian tumor present. It complied with the criteria affirmed by Boughton *et al.* [10] the tumor was confined to only one ovary with associated teratoid component and there was a good correlation of the patient's age and symptoms with those cases documented previously. Fifty percent of the cases do not show junctional activity as was seen in our case.^[11] Primary melanoma of ovary was first described by Andrews in 1901[12]. Uptil now only forty nine cases have been reported in the literature[7].

Abdominal pain and distension are the most common presenting symptoms. In this case also patient presented with lower abdominal pain. Patient's age ranges from 19-86 yrs[7].

Prognosis is poor as compared to other ovarian tumors[13]. Treatment of choice is hysterectomy with bilateral salpingo-oophorectomy and pelvic clearance. Chemotherapy and immunotherapy can be used as an adjuvant treatment. There is a role of targeted molecular therapy as was studied by Inzanov *et al.*^[14] BRAF inhibition target therapy has shown clinical benefits. BRAF is a serine/ threonine protein kinase activating the MAP kinase/ ERK- signalling pathway and its mutations are seen in 50% of melanomas[8].

CONCLUSION

Malignant transformation of mature cystic teratomas, mainly malignant melanoma can pose a difficulty in the diagnosis and management. As per the literature, prognosis is poor with a five year mortality rate of 90%. Histopathological examination along with immunohistochemical analysis for diagnostic purpose and adequate margin clearance plays an important role in management. Role of targeted molecular therapy has shown benefits and is under evaluation.

Conflict of interest

There are no conflicts of interest.

REFERENCES

1. Park, J. H., Whang, S. O., Song, E. S., Choi, S. J., & Lee, W. Y. (2008). An ovarian mucinous cystadenocarcinoma arising from mature cystic teratoma with para-aortic lymph node metastasis: a case report. *Journal of gynecologic oncology*, 19(4), 275-278.
2. Hackethal, A., Brueggmann, D., Bohlmann, M. K., Franke, F. E., Tinneberg, H. R., & Münstedt, K. (2008). Squamous-cell carcinoma in mature cystic teratoma of the ovary: systematic review and analysis of published data. *The lancet oncology*, 9(12), 1173-1180.
3. O'Gorman, T., & Olaitan, A. (2009). Primary malignant melanoma arising in an ovarian cystic teratoma. *European journal of gynaecological oncology*, 30(1), 88-89.
4. Sugiyama, V. E., Chan, J. K., & Kapp, D. S. (2008). Management of melanomas of the female genital tract. *Current opinion in oncology*, 20(5), 565-569.
5. Moore, R. G., Chung, M., Granai, C. O., Gajewski, W., & Steinhoff, M. M. (2004). Incidence of metastasis to the ovaries from nongenital tract primary tumors. *Gynecologic oncology*, 93(1), 87-91.
6. Cronje, H. S., & Woodruff, J. D. (1981). Primary ovarian malignant melanoma arising in cystic teratoma. *Gynecologic oncology*, 12(3), 379-383.
7. Paola, A., Maria, R. S., Laura, C., Elena, N., Orlando, C., & Teresio, M. (2018). A rare melanoma feature with primary ovarian origin: a case report and the literature review. *Obstetrics & gynecology science*, 61(2), 282-285.
8. Brudie, L. A., Khan, F., Radi, M. J., Yates, M. M., & Ahmad, S. (2016). Malignant melanoma arising in a mature teratoma: a case report with review of the recent literature. *Gynecologic oncology reports*, 16, 47-50.
9. Godoy, H. E., Kesterson, J. P., Kasznica, J. M., & Lele, S. (2012). Malignant melanoma arising in mature cystic teratoma of the ovary. *Gynecologic oncology case reports*, 2(1), 14.
10. Boughton, R. S., Hughmanick, S., & Marin-Padilla, M. (1987). Malignant melanoma arising in an ovarian cystic teratoma in pregnancy. *Journal of the American Academy of Dermatology*, 17(5), 871-875.
11. Dhorigol, V. M., & Malur, P. R. (2005). Primary malignant melanoma of the ovary--a case report. *Indian journal of pathology & microbiology*, 48(2), 213-215.
12. Kudva, R., Ayachit, G. S., & Ayachit, A. (2015). Malignant melanoma arising in an ovarian mature cystic teratoma-a rare entity. *Journal of clinical and diagnostic research: JCDR*, 9(4), ED14.
13. Hyun, H. S., & Mun, S. T. (2013). Primary malignant melanoma arising in a cystic teratoma. *Obstetrics & gynecology science*, 56(3), 201-204.
14. Puzanov, I., & Flaherty, K. T. (2010, September). Targeted molecular therapy in melanoma. In *Seminars in cutaneous medicine and surgery* (Vol. 29, No. 3, pp. 196-201). Frontline Medical Communications.