

Original Research Article

Expression of Metallothionein in Oral dysplasia and Oral Squamous cell carcinoma: An Immunohistochemical Study

Dr. Shravan kumar DR*¹, Dr. Syed Afroz Ahmed²

¹Senior Lecturer, Department of Oral and Maxillofacial Pathology, Sri Sai College of Dental Surgery, Vikarabad, Telangana, India

²Professor & Head, Department of Oral and Maxillofacial Pathology, Sri Sai College of Dental Surgery, Vikarabad, Telangana, India

*Corresponding Author:

Dr. Shravan kumar DR

Email: sravankumar.dr@gmail.com

Abstract: Oral leukoplakia (OL) is the most common potentially malignant lesions of the oral cavity and Oral squamous cell carcinoma (OSCC) accounts more than 95% of all malignant neoplasms in the oral cavity. Therefore, the aim of this study to report the immunoeexpression of metallothionein in dysplastic lesions to correlate with histological grade and OSCC. Samples of 5 normal oral mucosa, 15 dysplastic cases was graded as: mild dysplasia, moderate dysplasia and severe dysplasia and 15 cases of OSCC. Immunohistochemistry for the metallothionein was performed and the Pearson Chi-Square test was used in statistical analysis. The metallothionein stain in all cases exhibits a mosaic pattern and predominantly in cytoplasm and nucleus simultaneously. The total stain was significantly higher in OSCC when compared with normal and dysplastic lesions. Metallothionein expression may play an important role in the conversion of potentially malignant oral lesion to oral carcinoma since its earlier stages.

Keywords: Oral leukoplakia, OSCC, metallothionein, immunohistochemistry.

INTRODUCTION

Worldwide, oral cancer is one of the most prevalent disease and tenth most common cause of death. As the hallmark of cancer is excessive proliferation of cells, this increase is helpful in understanding and grading their biological behavior [1]. Oral cancer lesions are usually preceded by potentially malignant lesions and conditions. However, the clinical aspects and histological study of these cannot predict precisely the rate of malignant transformation [2,3].

Many markers pertaining to the malignancy have been developed in the recent years and Metallothionein (MT) is one amongst them. MTs are ubiquitous proteins or polypeptides that have high affinity for heavy metal ions including Cd, Cu and Zn. It is known to participate in metal homeostasis and detoxification, protection against reactive forms of oxygen, intracellular repair process, growth and differentiation [4, 5].

In normal oral mucosa MT expression is restricted only to basal and parabasal cells with a mosaic cytoplasmic-nuclear expression pattern, whereas in dysplastic lesions an additional focus in the spinous layer was noted. In OSCC, it was observed in cells located at the periphery and at the centre of tumor

islands. However, in areas with keratin pearls it was restricted to the basal and parabasal layer [6, 7].

Since not many studies have been done to evaluate the expression of MT in dysplasia and OSCC, this study was undertaken to evaluate the histological assessment of dysplasia and OSCC and to use MT as an adjunct in the histological grading.

MATERIALS AND METHODS

The study group included 35 formalin-fixed, paraffin-embedded tissue blocks retrieved from the department of oral pathology. All these cases were diagnosed as leukoplakia / carcinoma by routine hematoxylin & eosin staining. These were then subjected to immunohistochemical staining for MT.

Lumerman H *et al* for the histological grading of oral leukoplakia (OL) were used. The histological degree of epithelial dysplasia was based on the proportion of the height of the epithelial layer that presents the dysplastic changes [3, 8].

The antibodies and reagents used for immunohistochemical technique were obtained from ABCAM Company (UK) and SCKTEK LAB (USA) ready to use kit which consist of

1. Primary antibody – mouse antihuman Metallothionein
2. Secondary antibody – antimouse IgG
3. Peroxidase Block
4. Conjugate – Horse Radish Peroxidase
5. Chromogen substrate – Diaminobenzidine tetra hydrochloride (DAB)

Sectioning

4 micron thick sections were taken onto poly-L-lysine adhesive coated slide and incubated for 3 hour at 50-60^ocentigrade in a slide warmer for proper adhesion of the section to the slide.

Evaluation of the staining for MT

Assessment of MT positive cells was performed using double headed light microscope at 10x and 40x. The criteria used to define MT antigen positive cells were brown: mosaic staining in dysplastic cells, within the nucleus and cytoplasm.

Presence of staining in the nucleus and cytoplasm of various layers of epithelium were graded as 1+ (weaker expression) when it involved basal and supra basal layer of epithelium and were graded as 2+ (moderate expression) when it involved up to middle third of epithelium and were graded as 3+ (strong expression) when it involved entire epithelium.

Statistical Analysis

Interpretation of MT expression was done by two independent observers and the results were subjected to statistical analysis. The inter examiner reliability in recording expression of MT was found to be 0.94 (Intra class correlation co-efficient) implying a good agreement between the two observers. Hence, the study was preceded with a single observer.

All calculations were performed using IBM SPSS statistical software package (SPSS 14.0 for Windows, SPSS Inc, Chicago, IL, USA). The obtained data was analyzed by Pearson Chi-Square test. The p-value < 0.05 were considered to be statistically significant.

RESULTS AND OBSERVATIONS

The study group included 30 tissue samples (n=30) of previously diagnosed cases of dysplasia and carcinoma comprising of 15 dysplasia, 15 OSCC. 5 tissue samples (n=5) of normal oral mucosa were obtained which served as controls.

In normal oral mucosa MT expression was restricted only to basal and parabasal cells with a mosaic cytoplasmic-nuclear expression pattern, whereas in cases of OL additional foci in the spinous layer were noted. In OSCC, it was observed in cells located at the periphery and at the centre of tumor islands. However, in areas with keratin pearls staining was restricted only to basal and parabasal layer (Fig-1).

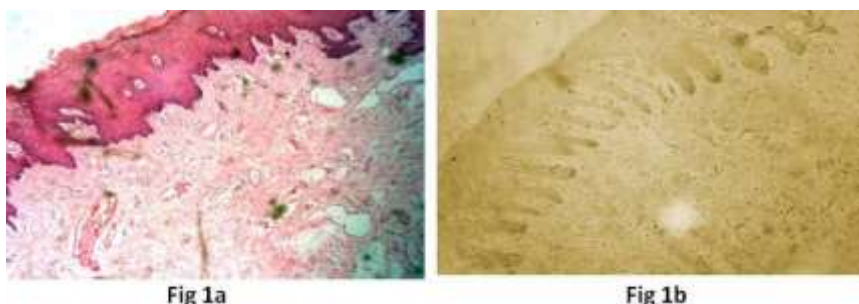

Fig-1: (a) H & E Staining (10x) of Normal mucosa; (b) Expression of Metallothionein in Normal mucosa.

The data obtained from the study was compiled, tabulated and subjected to statistical analysis. The results which were obtained are presented in the following manner: Cases of OL were graded histologically into mild dysplasia (7 cases), moderate

dysplasia (5 cases) and severe dysplasia (3 cases). The 15 cases of OSCC were also taken. The histological grading of OL among study group is given in Table 1 & Fig-2.

Table 1: Histological Grading among Study Group

Histological Diagnosis	No of cases (30)	Percent
Mild dysplasia	13	41.9
Moderate dysplasia	6	19.4
Severe dysplasia	4	12.9
OSCC	15	50

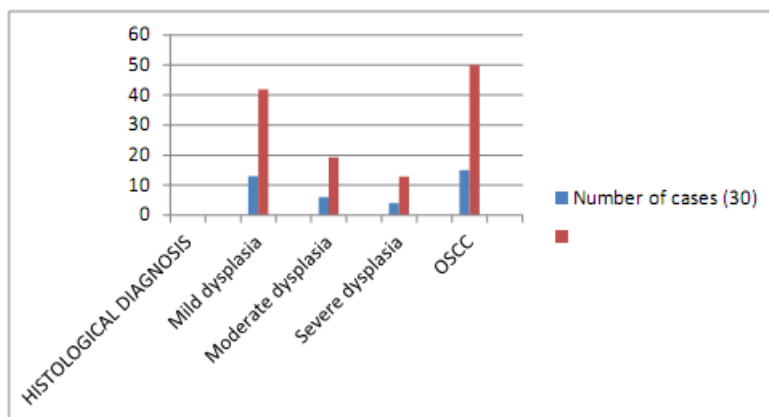


Fig-2: Histological Grading Among Study Group

The patient's age ranged from 21-70 years of age. They were divided into three groups as 21-30 years (Group A), 31-45 years (Group B) and 46-70 years

(Group C). The age wise distribution of study group is given in Table 2 & Fig-3.

Table 2: Age Distribution among Study Group

Group	Mild dysplasia	Moderate dysplasia	Severe dysplasia	OSCC	*P value
21-30	2	1	1	3	0.168
31-45	2	4	2	7	
46-70	3	0	0	5	
Total	7	5	3	15	

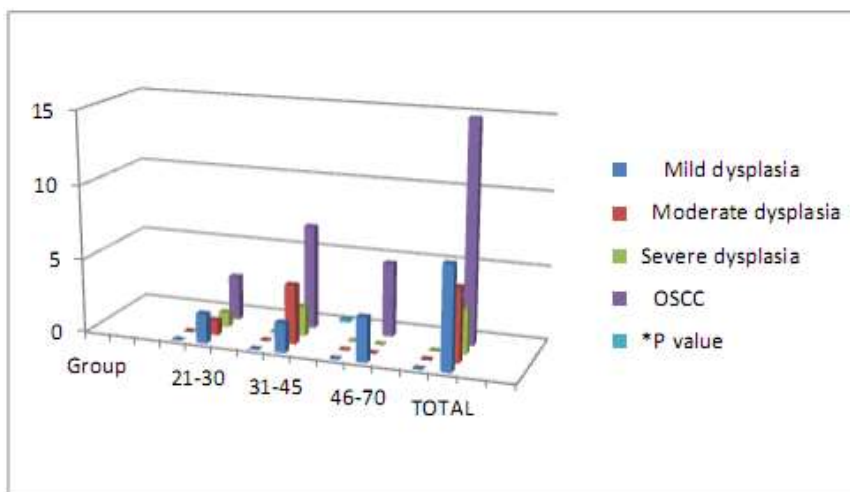


Fig-3: Age Distribution among Study Group

A total of 30 sections in which (n=15) cases of oral Leukoplakia, (n=15) cases of OSCC and (n=5) cases of normal mucosa were examined and compared for the immunohistochemical expression and distribution pattern of MT.

In the group mild dysplasia (n= 7 cases) , 3 cases showed a weak expression and scored as 1+, 2 cases showed a moderate expression and scored as 2+ and 2 cases showed a strong expression and were scored as 3+ (Fig-4).

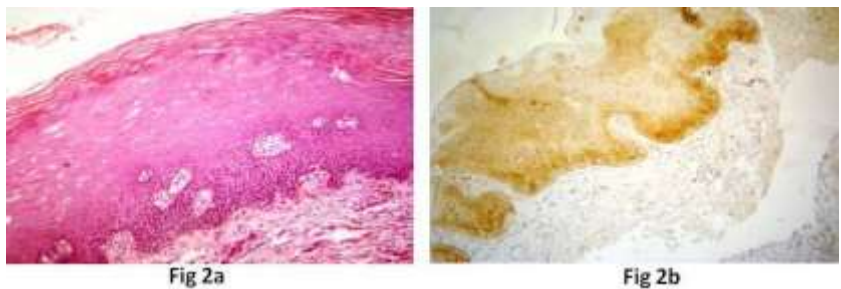


Fig-4: (a) H & E Staining (10x) of Mild dysplasia; (b) Expression of Metallothionein in Mild dysplasia

In the group moderate dysplasia (n=5), 1 case showed a weak expression and was given a score as 1+, 2 cases showed a moderate expression and were scored

as 2+ and 2 cases showed a strong expression and were scored as 3+ (Fig-5).

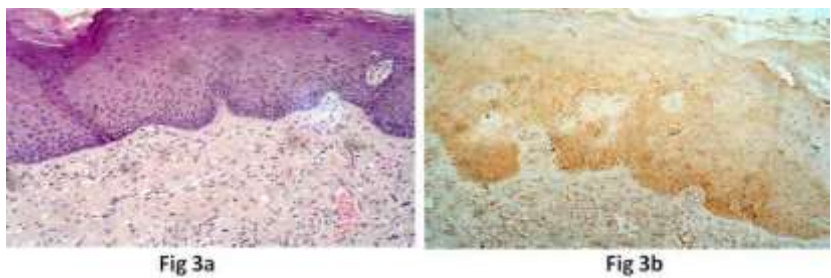


Fig-5: (a) H & E Staining (10x) of Moderate dysplasia; (b) Expression of Metallothionein in Moderate dysplasia

In the group severe dysplasia (n=3), all 3 cases showed a strong expression and were scored as 3+ (Fig-

6). In the group OSCC (n=15), all cases showed a strong expression and were scored as 3+ (Fig-7).

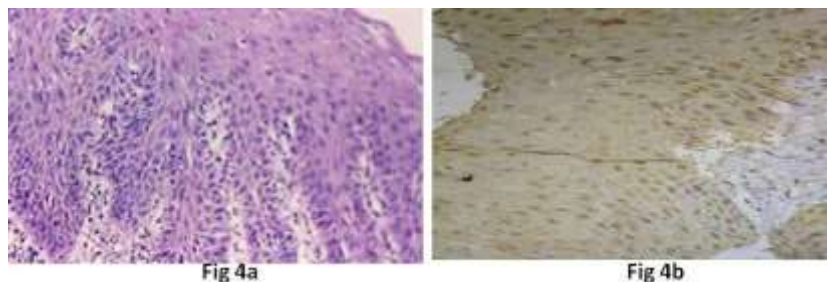


Fig-6: (a) H & E Staining (10x) of Severe dysplasia; (b) Expression of Metallothionein in Severe dysplasia

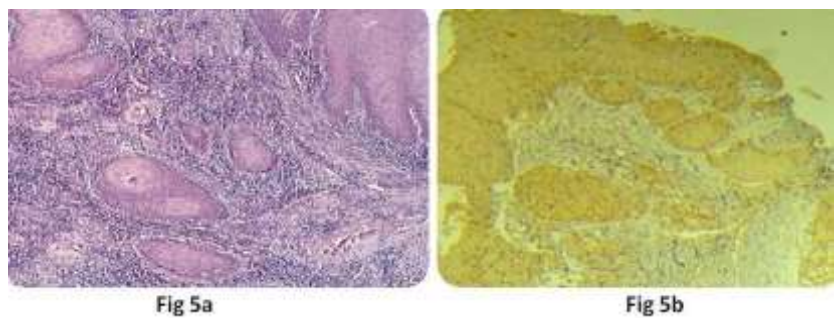


Fig-7: (a) H & E Staining (10x) of OSCC; (b) Expression of Metallothionein in OSCC

A statistical analysis was carried out using Pearson chi square test to compare the MT expression among the study and control group and it was found to

be stastically significant ($p < 0.05$) as given in Table 3 & Fig-8.

Table 3: Interobserver Variability of Metallothionein Expression among Different Histological Grades of Leukoplakia, Carcinoma and Normal Mucosa

	Types	1+	2+	3+	Total	*P Value	Intra-class Correlation coefficient
	OBSERVER 1	Normal Mucosa	5	0	0	5	0.016
Mild dysplasia		3	2	2	7		
Moderate dysplasia		1	2	2	5		
Severe dysplasia		0	0	3	3		
OSCC				15	15		
	Total	9	4	22	35		
OBSERVER 2	Mild dysplasia	3	1	3	7	0.021	
	Moderate dysplasia	1	3	1	5		
	Severe dysplasia	0	0	3	3		
	OSCC			15	15		
	Total	9	4	22	35		

Pearson chi-square test, $p < 0.05$ (significant)

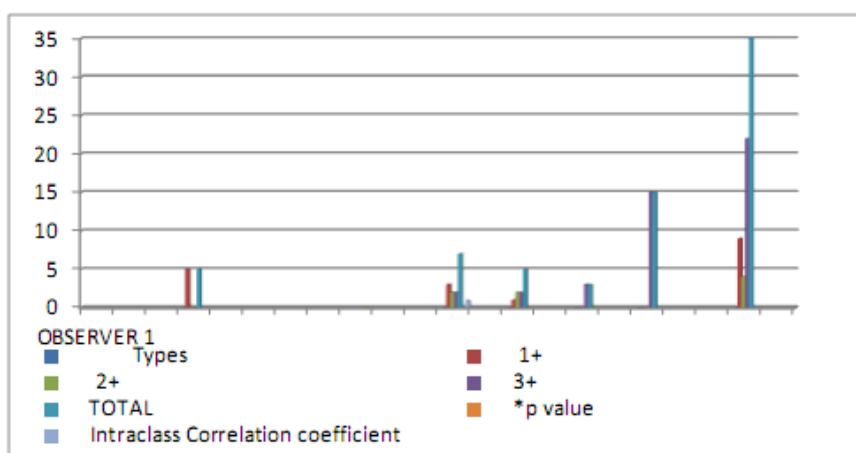


Fig-8: Metallothionein Expression among Different Histological Grades of Leukoplakia and Carcinoma

DISCUSSION

Oral Leukoplakia (OL) is a potentially malignant lesion of the oral mucosa and proceeds to OSCC in 16-62% of cases. On the basis of the degree of dysplastic cells and the thickness of dysplastic epithelium, this lesion is graded as mild, moderate and severe forms. Till now, in various oral mucosa lesions, different isoforms of the MT have been investigated for their immunoexpression [7, 9].

Our study showed the expression of MT in both the nucleus and cytoplasm of squamous cells of basal and parabasal layers in normal mucosa. However our results differed from those of Sundelin *et al* [10], Johann *et al* [6] and Pontes *et al* [1] who reported expression of MT only in cytoplasm of squamous cells of basal and parabasal layers in samples of normal mucosa. Although MT has been characterized as a cytoplasmic protein, it may cross the nuclear membrane by passive diffusion which is responsible for the expression of MT in the nuclear compartment of the cells. The significance of nuclei localization is a more effective biological protection against oxidative stress and genomic damage. In addition to its interference in genomic regulation and other proteins linked to DNA.

When OL slides were analyzed it was observed that the expression of MT was not only restricted to the cytoplasm but was observed in both cytoplasmic and nuclear compartment of squamous cells in the basal and parabasal layers cells with an additional foci in the spinous layers. Similar findings have been reported by many authors namely Sundelin *et al* [10], Ioachim *et al* [11], Johann *et al* [6] and Pontes *et al* [1].

When OSCC slides were analyzed it was observed in cells located at the periphery and at the center of the tumor islands. However, in areas with keratin pearls it was restricted to the basal and parabasal layer. Similar findings have been reported by many authors namely Theocharis *et al* [12] Cardoso *et al* [13] and Pontes *et al* [1].

The expression of MT pattern in the study group was observed among the three age groups and compared among different sub groups.

The expression pattern in sub group with mild dysplasia was compared among the three age groups.

There were two cases in group A, out of which one case showed a strong positive reaction and were scored as 3+ and the other case showed a weaker expression and were scored as 1+. There were two cases in group B, out of which one case showed a moderate expression and were scored as 2+ and the other case showed a strong expression and were scored as 3+. There were three cases in group C, out of which two cases showed a weaker expression and were scored as 1+ and other case showed a moderate expression and were scored as 2+.

The expression pattern in sub group with moderate dysplasia was compared among the three age groups. There is only one case in group A showed a strong expression and was scored as 3+. There were four cases in group B and out of which two cases showed a moderate expression and were scored as 2+ and two cases showed strong expression and were scored as 3+.

The expression pattern in sub group with severe dysplasia was compared among the three age groups. There is only one case in group A and two cases in group B showed a strong expression and was scored as 3+.

The expression pattern in sub group with OSCC was compared among the three age groups. There were 3 cases in group A, 7 cases in group B and 5 cases in group C showed a strong expression and were scored as 3+.

A statistical analysis was carried out using Pearson chi square test and it was not found to be statistically significant.

Our study showed highest expression of MT in OSCC with the lowest MT expression in mild dysplasia and the expression in severe and OSCC was more or less equal. Our results are not in accordance with the results obtained by Johann *et al* [6], Pontes *et al* [1] who noted MT was almost equal in cases of moderate and severe dysplasias when compared with normal oral mucosa, hyperkeratosis and mild dysplasia and concluded that the moderate dysplasia is the hallmark point in the process of carcinogenesis.

The literature reveals lesions with mild dysplasia also showed malignant transformation but the reasons for its transformation are not clear. Overexpressions of MT in 2 cases of mild dysplasia were observed in our study. Literature reveals that overexpression of MT may mean that the altered cells are more protected with more chances of survival, but it can also indicate alterations in genomic regulation and in other proteins linked to DNA, thus presenting its possible role in carcinogenesis. Hence, even cases of mild dysplasia should not be overlooked and should be kept under observation.

In the present study (n=30) cases of OL and OSCC, all cases showed a positive immunoreactivity. 9 cases showed a weaker expression and were scored as 1+, 4 cases showed a moderate expression and were scored as 2+ and 22 cases showed a strong expression and were scored as 3+. The overexpression of MT is variable in different grades of OL and this may be because of difference in phenotypic variation that are associated with dysplastic cells and might be worthy of a more meticulous investigation.

Overexpression noted as early as in mild dysplasia gives a clue regarding the initiation or promotion of carcinogenesis. Thus, this study suggests that MT can be one of the useful diagnostic marker for predicting the potential behavior of OL turning into oral squamous cell carcinoma.

CONCLUSION

The present study was undertaken to observe MT immunoreactivity in OL and OSCC. Expression of MT in cases of normal mucosa was confined to basal and parabasal layers whereas in cases of OL expression of MT was observed not only in the basal layer but also in the spinous layer, suggesting that MT possibly because of its chelating properties may contribute to delaying cells entering apoptosis. Our study revealed MT expression in cases of OSCC to be relatively more when compared with other cases like severe dysplasia, moderate dysplasia and mild dysplasia. In conclusion, the results of this study suggest that MT overexpression can be one of the useful diagnostic marker for predicting the potential behavior of OL turning into OSCC. Its overexpression gives a clue regarding the initiation or promotion of carcinogenesis. However, a large sample is required to predict the overexpression of MT in different histological grades of OL.

REFERENCES

1. Pontes, H. A. R., de Aquino Xavier, F. C., Da Silva, T. S. P., Fonseca, F. P., Paiva, H. B., Pontes, F. S. C., & dos Santos Pinto Jr, D. (2009). Metallothionein and p-Akt proteins in oral dysplasia and in oral squamous cell carcinoma: an immunohistochemical study. *Journal of Oral Pathology & Medicine*, 38(8), 644-650.
2. Warnakulasuriya, S. (2001). Histological grading of oral epithelial dysplasia: revisited. *The Journal of pathology*, 194(3), 294-297.
3. Axéll, T., Pindborg, J. J., Smith, C. J., & Waal, I. V. D. (1996). Oral white lesions with special reference to precancerous and tobacco-related lesions: conclusions of an international symposium held in Uppsala, Sweden, May 18–21 1994. *Journal of oral pathology & medicine*, 25(2), 49-54.
4. Kaegi, J. H., & Schaeffer, A. (1988). Biochemistry of metallothionein. *Biochemistry*, 27(23), 8509-8515.

5. Chattopadhyay, A., Ray, J. G., & Caplan, D. J. (2002). AgNOR count as objective marker for dysplastic features in oral leukoplakia. *Journal of oral pathology & medicine*, 31(9), 512-517.
6. Johann, A. C. B. R., Silveira-Junior, J. B., Souto, G. R., Horta, M. C. R., Aguiar, M. C. F., & Mesquita, R. A. (2008). Metallothionein immunoexpression in oral leukoplakia. *Medicina Oral Patología Oral y Cirugía Bucal*, 13(3), 156.
7. Grzegorzolka, J., Kurnol, K., Piotrow, P., Pula, B., Kobierzycki, C., Piotrowska, A., ... & Podhorska-Okolow, M. (2012). Hsp27 expression in invasive ductal breast carcinoma. *Age*, 50(31), 30-09.
8. Mishra, M., Mohanty, J., Sengupta, S., & Tripathy, S. (2005). Epidemiological and clinicopathological study of oral leukoplakia. *Indian Journal of Dermatology, Venereology, and Leprology*, 71(3), 161.
9. Warnakulasuriya, S. (2000). Lack of molecular markers to predict malignant potential of oral precancer. *The Journal of pathology*, 190(4), 407-409.
10. Sundelin, K., Jadner, M., Norberg-Spaak, L., Davidsson, A., & Hellquist, H. B. (1997). Metallothionein and Fas (CD95) are expressed in squamous cell carcinoma of the tongue. *European Journal of Cancer*, 33(11), 1860-1864.
11. Ioachim, E., Assimakopoulos, D., Peschos, D., Zissi, A., Skevas, A., & Agnantis, N. J. (1999). Immunohistochemical expression of metallothionein in benign premalignant and malignant epithelium of the larynx: correlation with p53 and proliferative cell nuclear antigen. *Pathology-Research and Practice*, 195(12), 809-814.
12. Theocharis, S., Karkantaris, C., Philipides, T., Agapitos, E., Gika, A., Margeli, A., ... & Koutselinis, A. (2002). Expression of metallothionein in lung carcinoma: correlation with histological type and grade. *Histopathology*, 40(2), 143-151.
13. Cardoso, S. V., Barbosa, H. M., Candellori, I. M., Loyola, A. M., & Aguiar, M. F. (2002). Prognostic impact of metallothionein on oral squamous cell carcinoma. *Virchows Archiv*, 441(2), 174-178.