

Class II Division 1 Malocclusion Treated with Two-Phase Orthodontic Approach

Riadh Rjili^{1*}, Samir Tobji², Wiem Ben Amor³, Ines Dallel², Adel Ben Amor⁴

¹Resident, University of Monastir, Faculty of Dental Medicine, Dento-Facial Orthopedics Department of Monastir Dental Clinic, Laboratory of Oral Health and Orofacial Rehabilitation, Tunisia

²Professor, PHD, Faculty of Dental Medicine, University of Monastir, BP 56 Avenue Taher Hadded, Monastir 5000, Tunisia

³Assistant Professor, Faculty of Dental Medicine, University of Monastir, BP 56 Avenue Taher Hadded, Monastir 5000, Tunisia

⁴Head of Dento-Facial Orthopedics Department of Monastir Dental Clinic, Tunisia

DOI: [10.36348/sjodr.2023.v08i08.007](https://doi.org/10.36348/sjodr.2023.v08i08.007)

| Received: 03.06.2023 | Accepted: 12.07.2023 | Published: 28.08.2023

*Corresponding author: Riadh Rjili

Resident, University of Monastir, Faculty of Dental Medicine, Dento-Facial Orthopedics Department of Monastir Dental Clinic, Laboratory of Oral Health and Orofacial Rehabilitation, Tunisia

Abstract

Enhancing facial aesthetics is a primary motivation for individuals with class II division 1 malocclusion seeking orthodontic treatment. Among the different techniques available to treat Class II malocclusions, a two-phase approach involving functional jaw orthopedics and fixed orthodontic treatment is commonly employed. In this case report, we present the treatment of a young male patient with a Class II Division 1 malocclusion. In the initial phase, the patient underwent growth modification and correction of overjet, overbite, and profile using the Andresen activator. Subsequently, a fixed orthodontic appliance was utilized in the second phase to achieve well-aligned arches and enhance both aesthetics and functionality.

Keywords: Enhancing facial aesthetics, orthodontic treatment, Andresen activator, Class II Division 1 malocclusion.

Copyright © 2023 The Author(s): This is an open-access article distributed under the terms of the Creative Commons Attribution 4.0 International License (CC BY-NC 4.0) which permits unrestricted use, distribution, and reproduction in any medium for non-commercial use provided the original author and source are credited.

INTRODUCTION

Class II division 1 malocclusion is a prevalent type of malocclusion in the human population, with a prevalence range of 13%-24% [1, 2]. It can be attributed to mandibular retrusion, maxillary protrusion, or a combination of both [3, 4]. According to Dr. McNamara [5], mandibular retrusion is the primary contributing factor to class II malocclusion.

Class II division 1 malocclusions are typically categorized based on dental, skeletal, or functional characteristics. The Class II is described by a distal relationship of the mandibular molar relative to the maxillary molar of more than one-half the width of the cusp. Class II division 1 is characterized by labially inclined maxillary incisors, an increased overjet and a relatively narrow maxillary arch.

The treatment approach for class II division 1 malocclusion depends on factors such as the patient's age, growth potential, severity of malocclusion, and treatment compliance [5, 6]. In growing individuals, growth modification procedures can be utilized to correct skeletal Class II malocclusion during the mixed or early stages of permanent dentition. The Andresen activator functional appliance, a monoblock device, promotes an anterior mandibular position during closure. Activator therapy has been shown to increase condylar growth and remodel the articular fossa.

This case report presents a two-phase orthodontic treatment using the Andresen activator followed by orthodontic fixed appliances for a patient with skeletal Class II malocclusion and mandibular retrusion.

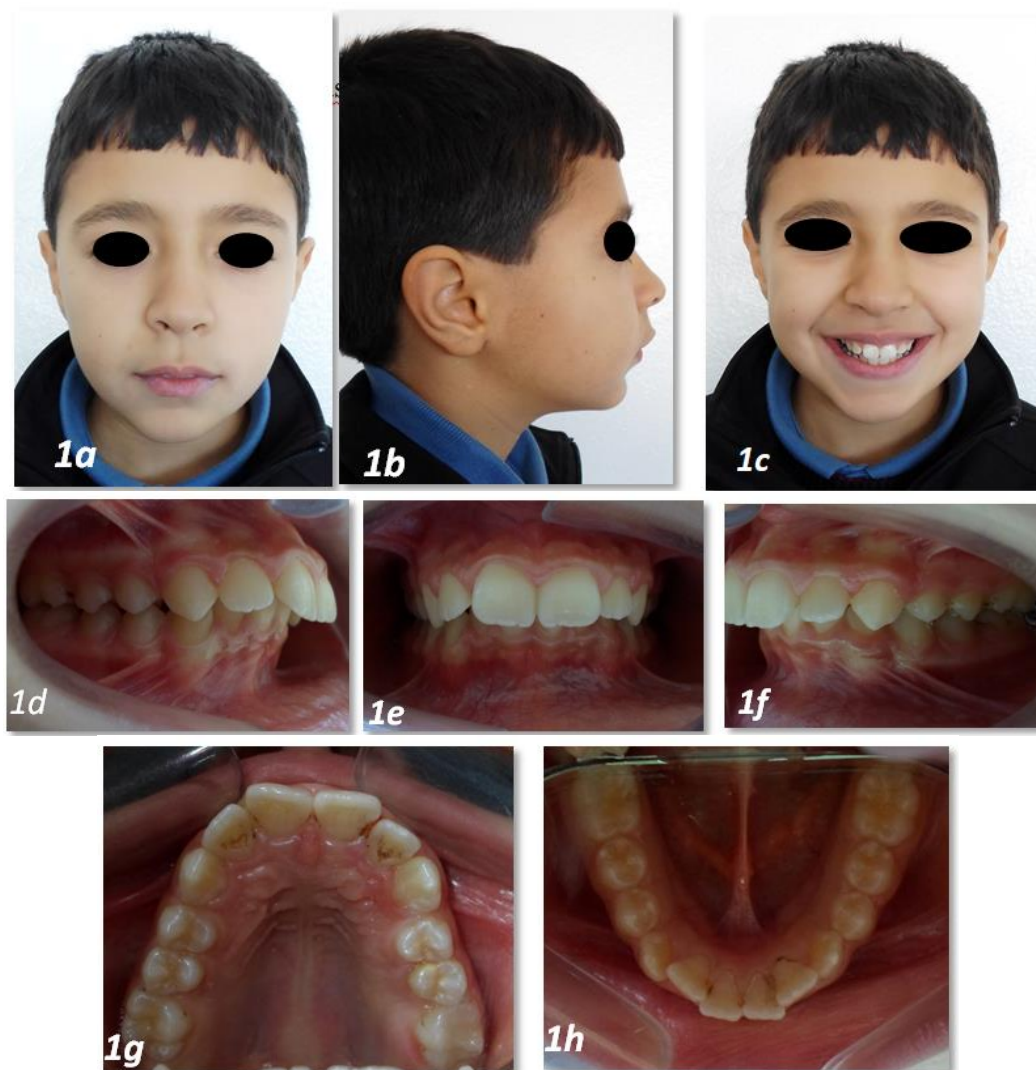

Figure 1(a-h): Pre-Treatment Photographs

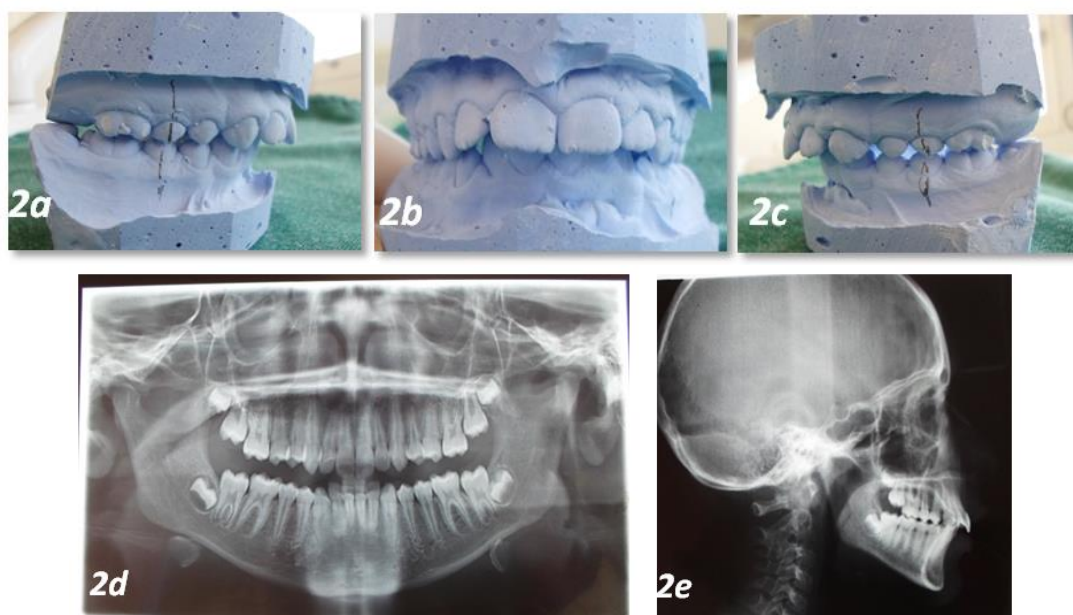


Figure 2(a-e): The pre-treatment radiographs and study models

CASE REPORT

Diagnosis and Etiology:

A 12-year-old male patient presented in this case, accompanied by his parents, sought treatment at our orthodontic department. His main concern was the protrusion of his upper front teeth and the unfavorable appearance. No medical history or allergies were reported.

Upon extraoral examination, facial asymmetry was observed with right-sided chin deviation, a convex profile, protrusion of the upper lip, eversion of the lower lip and incompetent lip closure. Intraoral examination revealed a permanent dentition except for the eruption of the second molars. In Occlusion, he had a Class II canine relationship by 5 mm on the right side, 6 mm on the left side, and a Class II molar relationship bilaterally by 5 mm. The patient also had an increased overjet of 8 mm and a deep bite of 5 mm.

The panoramic radiograph indicated normal development of the third molars without any significant abnormalities. Lateral cephalometric analysis revealed a Class II skeletal pattern with an ANB angle of 8°. The maxilla exhibited normal positioning relative to the cranial base with an SNA angle of 81°. However, the mandible was retrognathic, characterized by an SNB value of 73°. Additionally, there was dental biprotrusion, as evidenced by an I/F angle of 115° and an IMPA angle of 96°.

Based on these findings, the patient was diagnosed with skeletal Class II division 1 malocclusion

with a retrognathic mandible and a normodivergent facial profile.

Treatment Objectives :

The treatment objectives for this case were as follows:

- Correct the skeletal Class II malocclusion to achieve an aesthetically pleasing facial profile.
- Control the vertical dimension.
- Establish Class I molar and canine relationships.
- Achieving a normal overjet and overbite
- Align the upper and lower teeth.

Treatment Alternatives

The initial treatment option involved functional appliance therapy to enhance mandibular growth, followed by the use of fixed appliances. This approach offered several advantages, including the correction of mandibular retrognathism and improvement of the patient's profile. Fixed orthodontic treatment was employed to resolve residual crowding and to improve the occlusion of permanent teeth ensuring a Class I relationship.

An alternative option was the extraction of maxillary first premolars, which would reduce the overjet and deep overbite while establishing Class I canine relationships. However, this alternative would not lead to improvement in the patient's facial profile.

The treatment alternatives were thoroughly explained to the patient's parents, who expressed a preference for the first treatment option due to its potential for enhancing facial aesthetics through forward mandibular growth.

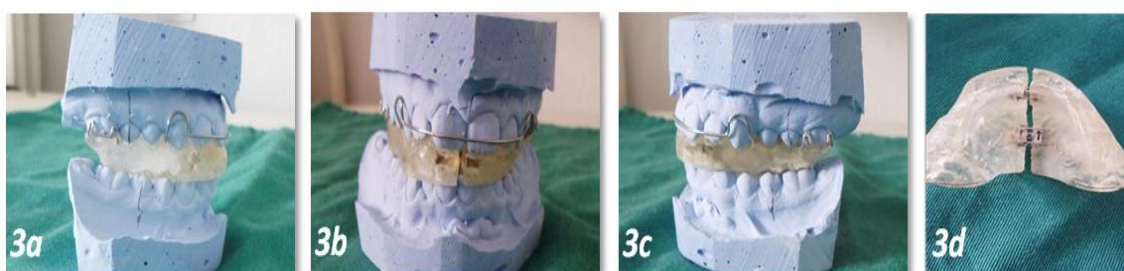
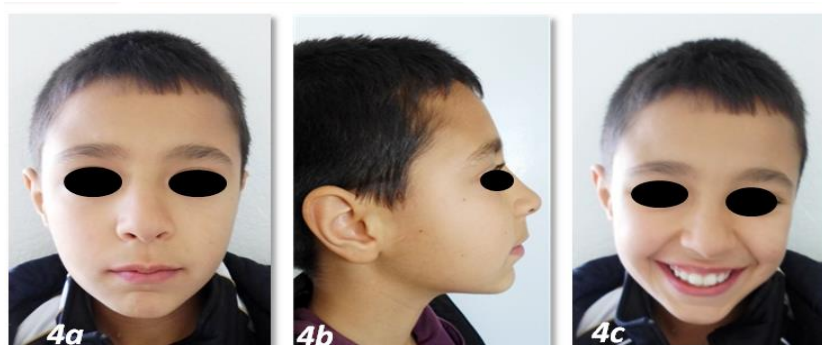


Figure 3(a-d): Andresen activator



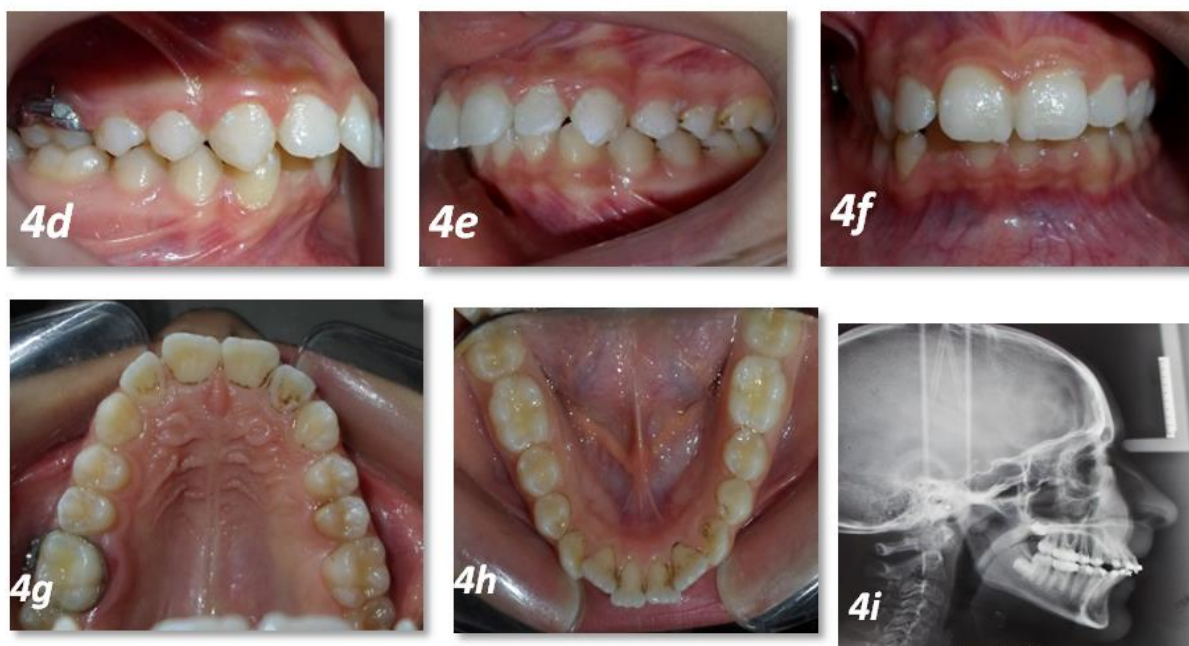


Figure 4(a-i): Phase I final and phase II pretreatment facial and intraoral photos and lateral cephalometric radiograph

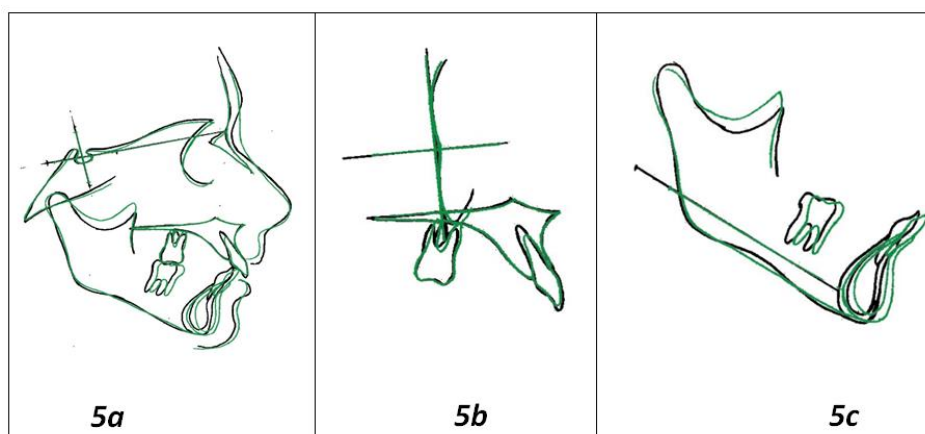


Figure 5(a-c): Superimposition of cephalometric tracings pretreatment (black), post activator therapy (green)

Treatment Progress

Our treatment plan involved utilizing the Andresen Activator to achieve anterior repositioning of the mandible and maximize its growth potential. The initial construction bite made was 5 mm sagittal to anterior, 4 mm vertical, and the lower midline was adjusted to align with the midline of the face.

To avoid dental interferences particularly transverse incoordination when the mandible is advanced for cl II correction, transversal expansion in upper jaw was needed. In this case, the functional appliance comprises of two expansion screw (one anterior and one posterior) by which selective expansion is possible. Expansion screws were activated once a week. Patient wore his appliance regularly, all night and during daytime as well. The Andresen

activator was used for a period of 10 months from 10 to 12 hours per day during afternoons and nights.

After 10 months of activator usage, the overjet was reduced to 3mm, and there was a significant change in the patient's profile. Molar and canine relationships on both sides achieved a Class I relationship.

Upon completion of Phase I, Phase II commenced immediately, involving the placement of 0.022 × 0.028 inch. Edgewise complete fixed appliances for a period of 1 year. An initial 0.014 nickel-titanium archwire was used for alignment and leveling purposes, gradually progressing to heavier archwires. After the alignment and leveling, coordinated 0.019" × 0.025" stainless steel wires were placed.

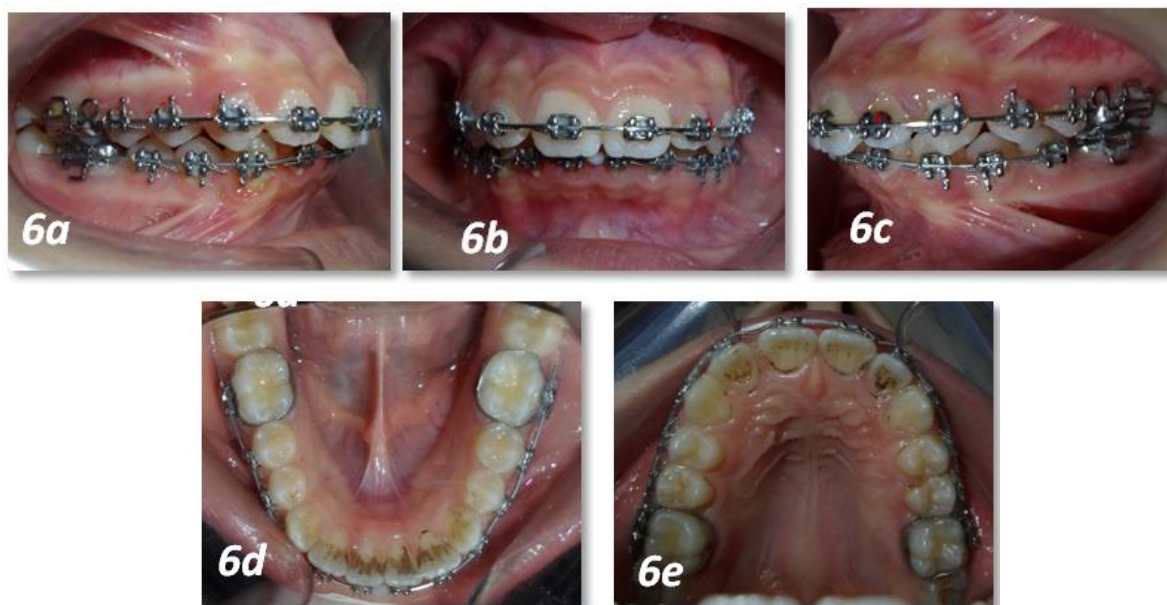


Figure 6(a-e): Fixed orthodontic appliance treatment

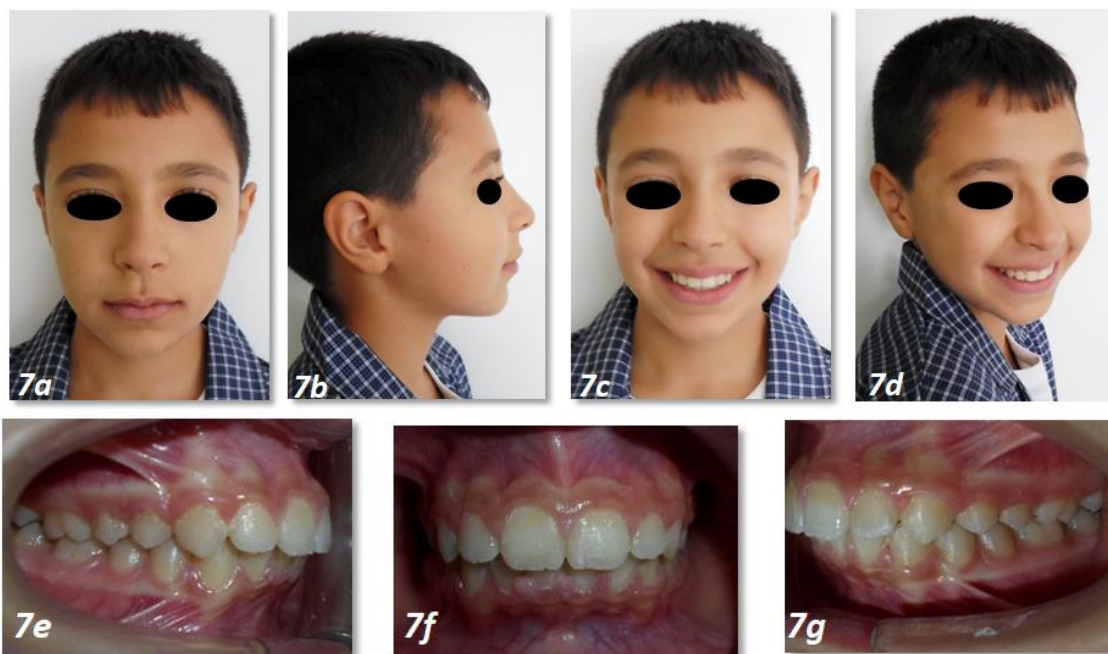
Treatment Result

The initial phase of treatment spanned 10 months, successfully achieving the goals of reducing the excessive overjet and deep overbite to normal parameters. The patient's profile exhibited significant improvement, characterized by a notable reduction in soft tissue facial convexity due to the forward growth of the mandible. Class I dental occlusion was established bilaterally.

Cephalometric measurements indicated that the changes primarily occurred within the dentoalveolar skeletal components. Post-treatment cephalometric tracing revealed a significant improvement in the

skeletal discrepancy (ANB angle : pretreatment 8°, posttreatment 5°; SNB angle: pretreatment 73°, posttreatment 76°), as well as the inclination of the maxillary and mandibular incisors (upper incisors to FH angle: pretreatment 115°, posttreatment 112°; IMPA angle: pretreatment 96°, posttreatment 100°).

Upon completion of Phase II, which involved the use of fixed appliances, regional superimpositions of the maxilla and mandible demonstrated that the maxillary incisors had been palatally uprighted, while the mandibular incisors exhibited a slight labial proclination.



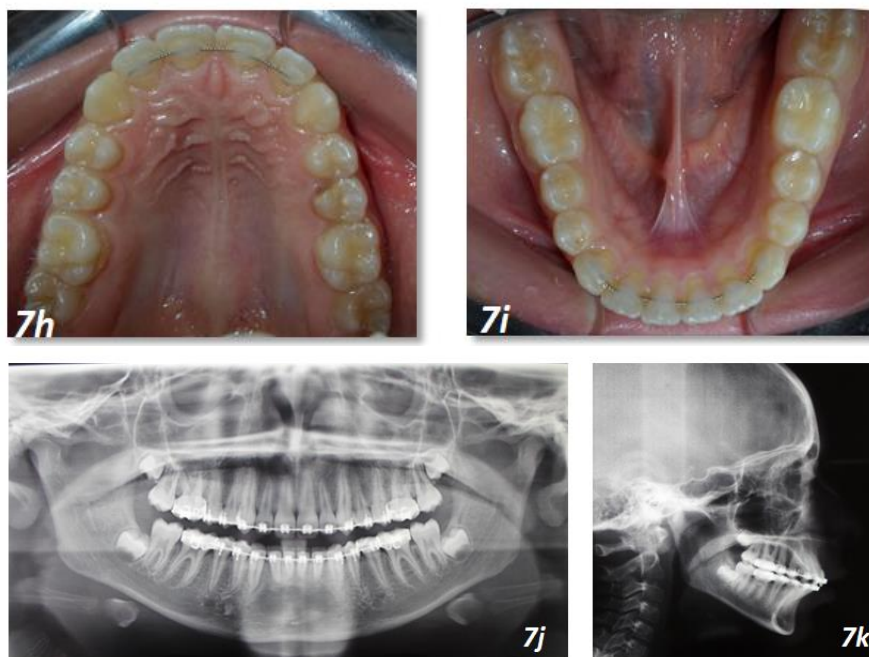


Figure 7(a-k): Posttreatment photos and radiographs

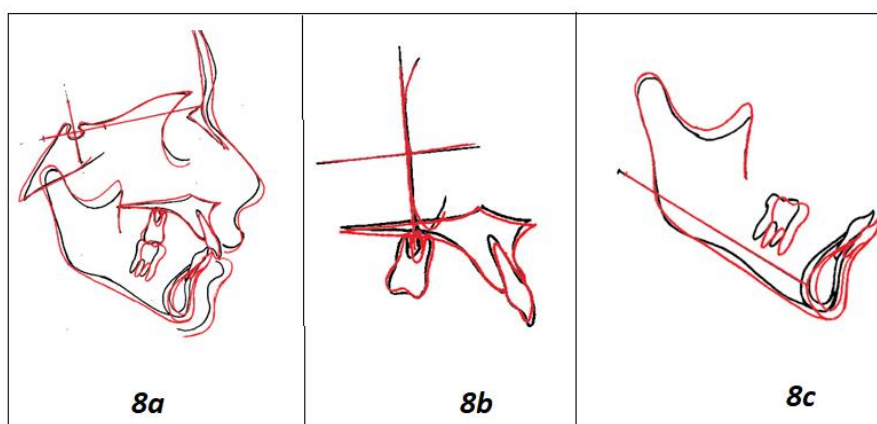


Figure 8(a-c): Superimposition of cephalometric tracings pretreatment (black) and posttreatment (red)

Table 1: Pretreatment, postmyofunctional, and posttreatment cephalometric data

Parameter	Average	Pretreatment	Postmyofunctional	Posttreatment
SNA (°)	82	81	81	81
SNB (°)	80	73	76	76
ANB (°)	2	8	5	5
FMA (°)	25	27	27	26
SN-GoGn (°)	32	36	37	37
U1-NA (angle)	22	23	22	21
U1-NA (linear)	4	5	5	4
U1-SN (°)	102	108	106	102
L1-NB (angle)	25	28	29	29
L1-NB (linear)	4	6	6	7
IMPA (°)	90	96	100	102
Nasolabial angle (°)	102	101	103	103
U1 exposure (mm)	3-5	8	8	7
NB-Pog	2±2	2	2	2

SNA: Sella Nasion Point A angle, SNB: Sella Nasion Point B angle, ANB: Point A Nasion Point B angle, FMA: Frankfort horizontal to Mandibular plane angle, IMPA: Incisor Mandibular plane Angle.

DISCUSSION

The primary objective of Class II Division 1 therapy is to achieve a Class I molar and canine relationship, reduce the overjet, improve the deep bite, and ensure proper functional outcomes. Additionally, Class II Division 1 therapy should also aim to resolve dentoskeletal disharmony in order to obtain a favorable facial appearance

Using two-phase approach to treatment has proven effective in managing growing patients, significantly enhancing both function and aesthetics [7]. The initial stage requires patient compliance and involves the use of a removable functional device. The second phase is carried out using a fixed appliances.

According to Pancherz *et al.*, [8], functional therapy stimulates mandibular growth while slowing down maxillary growth. Functional devices have demonstrated effectiveness in treating Class II skeletal malocclusion, particularly in cases with a retrognathic mandible. These appliances are most beneficial when utilized during active growth stages.

In this, the muscular forces generated by mandibular propulsion were transferred to the teeth through the acrylic body and labial arch. These forces, transmitted from the teeth to the bone, contributed to limiting maxillary growth while stimulating mandibular growth and inducing dentoalveolar adaptation [9, 10].

However, functional devices have limited ability for individual dental movement compared with fixed orthodontic devices. A treatment with removable functional device can therefore be followed by an orthodontic treatment with fixed appliances to produce individual dental movements and improve occlusion.

CONCLUSION

This case report highlighted the effectiveness of utilizing Andresen activator therapy to correct a severe skeletal Class II malocclusion. Functional appliances have shown success in treating skeletal Class II malocclusions, particularly in growing and cooperative patients. The ideal case for this treatment approach involves Class II Division I malocclusion with a retrognathic mandible and upright or lingually tipped lower incisors. However, it is crucial to carefully consider the etiology of skeletal anomalies, the optimal timing for initiating treatment, the selection of appropriate functional devices, and the patient's compliance when determining the treatment modality. Such considerations are vital to ensure the achievement of successful outcomes.

REFERENCES

1. De Ridder, L., Aleksieva, A., Willems, G., Declerck, D., & Cadenas de Llano-Pérula, M. (2022). Prevalence of orthodontic malocclusions in healthy children and adolescents: a systematic review. *International Journal of Environmental Research and Public Health*, 19(12), 7446. doi:10.3390/ijerph19127446
2. Gudipaneni, R. K., Aldahmeshi, R. F., Patil, S. R., & Alam, M. K. (2018). The prevalence of malocclusion and the need for orthodontic treatment among adolescents in the northern border region of Saudi Arabia: An epidemiological study. *BMC oral health*, 18(1), 1-6. doi:10.1186/s12903-018-0476-8
3. Moyers, R. E., Riolo, M. L., Guire, K. E., Wainright, R. L., & Bookstein, F. L. (1980). Differential diagnosis of Class II malocclusions: Part 1. Facial types associated with Class II malocclusions. *American journal of orthodontics*, 78(5), 477-494. doi: 10.1016/0002-9416(80)90299-7
4. Bishara, S. E. (2006, March). Class II malocclusions: diagnostic and clinical considerations with and without treatment. In *Seminars in orthodontics*, 12(1), pp. 11-24. WB Saunders. doi:10.1053/j.sodo.2005.10.005
5. McNamara Jr, J. A. (1981). Components of Class II malocclusion in children 8–10 years of age. *The Angle Orthodontist*, 51(3), 177-202. doi:10.1043/0003-3219(1981)051<0177:COCIMI>2.0.CO;2
6. Tulloch, J. C., Proffit, W. R., & Phillips, C. (1997). Influences on the outcome of early treatment for Class II malocclusion. *American Journal of Orthodontics and Dentofacial Orthopedics*, 111(5), 533-542. doi:10.1016/s0889-5406(97)70290-7
7. Tallgren, A., Christiansen, R. L., Ash Jr, M. M., & Miller, R. L. (1998). Effects of a myofunctional appliance on orofacial muscle activity and structures. *The Angle Orthodontist*, 68(3), 249-258. doi:10.1043/0003-3219(1998)068<0249:EOAMAO>2.3.CO;2
8. Pancherz, H., Ruf, S., & Kohlhas, P. (1998). “Effective condylar growth” and chin position changes in Herbst treatment: a cephalometric roentgenographic long-term study. *American journal of orthodontics and dentofacial orthopedics*, 114(4), 437-446. doi:10.1016/s0889-5406(98)70190-8
9. Basciftci, F. A., Uysal, T., Büyükerkmen, A., & Sari, Z. (2003). The effects of activator treatment on the craniofacial structures of Class II division I patients. *The European Journal of Orthodontics*, 25(1), 87-93. doi:10.1093/ejo/25.1.87
10. Harvold, E. P., & Vargervik, K. (1971). Morphogenetic response to activator treatment. *American Journal of Orthodontics*, 60(5), 478-490. doi:10.1016/0002-9416(71)90114-X