

Two-Stage Mandibular Ridge Split with Transitional Implants in Cases of Extreme Bone Atrophy (Residual Bone Width \leq 3 Mm): Retrospective Study with a Follow-Up Time of 10 Years

Eduardo Anitua^{1,2,3*}

¹DDS, MD, PhD, Private Practice in Oral Implantology, Eduardo Anitua Institute, Vitoria, Spain

²Clinical Researcher, Eduardo Anitua Foundation, Vitoria, Spain

³University Institute for Regenerative Medicine and Oral Implantology - UIRMI (UPV/EHU-Fundación Eduardo Anitua), Vitoria, Spain

DOI: [10.36348/sjodr.2022.v07i09.007](https://doi.org/10.36348/sjodr.2022.v07i09.007)

| Received: 14.08.2022 | Accepted: 20.09.2022 | Published: 30.09.2022

*Corresponding author: Eduardo Anitua

DDS, MD, PhD, Private Practice in Oral Implantology, Eduardo Anitua Institute, Vitoria, Spain

Abstract

Vertical bone atrophy in the mandible is a challenge when inserting dental implants. In situations where less than 3 mm of residual bone is present but both vestibular tables remain intact, a mandibular split technique can be used. It is a highly predictable and easy to perform technique although borderline situations such as those shown in the present clinical case series with less than 3 mm bone width may be less unpredictable in terms of outcome and long-term implant survival. Therefore, we show a series of extreme cases treated with a technique of splitting, biological reaming and matching of the implant to the recipient bed, which achieves lasting results ten years later.

Keywords: split crest, bone atrophy, dental implant.

Copyright © 2022 The Author(s): This is an open-access article distributed under the terms of the Creative Commons Attribution 4.0 International License (CC BY-NC 4.0) which permits unrestricted use, distribution, and reproduction in any medium for non-commercial use provided the original author and source are credited.

INTRODUCTION

Horizontal extreme bone atrophies (3 mm in width or less) in both the mandible and maxilla are complex cases that must be approached with a carefully designed treatment protocol that will generate sufficient residual bone volume for the successful insertion of implants [1-4]. To recover this volume, different surgical techniques with greater or lesser complexity are available, with less invasive approaches being gradually developed. The main techniques used for this purpose in the case of horizontal atrophies are guided bone regeneration techniques, ridge expansion, split crest technique, block grafts and, in very complex cases, bone distraction [5, 6]. Each of the techniques has its own indications, and sometimes several of them may be needed in the same patient to achieve a complete regeneration or at least to allow the insertion of implants in a predictable way. There are substantial variations in the quality and quantity of bone volume within the same arch of the same patient, as well as areas where, in addition to width, bone blocks have been completely or partially lost, which changes the approach to the technique to be implemented [7-10]. In general, the technique selected as associated with lower

morbidity and shorter waiting time for the resolution of the case in situations of horizontal atrophy is the ridge split, although it should be considered that the presence of the two bone plates (vestibular and lingual) must be preserved intact [11-14]. This technique consists of the mechanical separation of both corticals, thereby creating a space in the trabecular between the two plates, which is then displaced for the insertion of an implant in this area [15-19]. Once the implant is inserted, the resulting gap or space between the plates that is not occupied by the titanium of the implant can be filled with different osteoinductive or conductive materials, generally to achieve new bone formation in this area [20, 21]. It is also a highly predictable technique, since the formation of new bone in the gap generated by the expansion procedure, is considered a favorable defect, since one cortical cortex is only a few millimeters away from the other and the fracture has a high osteogenic potential [21-24]. For this reason, it is often used with a high frequency in situations of atrophy, especially in areas such as the mandible where other more complex approaches often fail due to the presence of less vascularization and cellularity in the residual bone, which hinders the integration of block

grafts or bone neof ormation in guided regeneration techniques [25].

Most of the published studies on the survival of implants placed by this technique state that they have a similar survival to implants inserted in a conventional way without accessory techniques [12, 26].

Mandible cases are less frequent and when performed in the posterior sector (molar area) where the bone is less distensible, they usually have a worse prognosis because cortical fractures are much more frequent [27, 28]. To avoid this side effect that compromises the technique and the survival of the implants, the two-stage split technique has sometimes been described, which allows a controlled expansion in two minimally invasive surgical procedures. This technique described by our study group has shown good results even in areas with extreme horizontal atrophy [29, 30]. For this purpose, a first expansion is performed by placing a transitional implant that maintains a minimum level of separation between plates and allows the formation of new bone in this gap. Subsequently, the implant is removed, and a second expansion is performed. If this expansion were to be performed only once, the risk of the critical defect being large enough to obtain poor results in the genesis of new bone, as well as complications of the forced separation of the plates that would generate fracture would be high. For this reason and to achieve an improvement in the insertion axis of the secondary implant, the two-stage split technique is an alternative for the most extreme cases 3 mm or less of bone crest [29, 30].

The present study aims to retrospectively analyze implants placed in mandibular posterior sectors using the two-stage ridge split technique in areas with residual bone volume ≤ 3 mm with a follow-up time of 10 years.

MATERIAL AND METHODS

A retrospective case series of patients treated in the dental clinic in the period 2009-2010 were analyzed in which implants were placed in posterior mandibular sectors using the two-stage split crest technique and the residual bone volume was ≤ 3 mm. All patients were evaluated prior to implant insertion by means of diagnostic models, intraoral examination, and dental CT (Cone-beam), subsequently analyzed by means of specific software (BTI-Scan II). Before the insertion of the implants, an antibiotic pre-medication consisting of amoxicillin 2g orally one hour before the procedure and paracetamol 1g orally (as an analgesic) was used. Subsequently, patients were treated with amoxicillin 500-750 mg orally every 8 hours (according to weight) for 5 days. The surgical technique was the same for all patients, consisting of: Anesthesia, elevation of a full thickness mucoperiosteal flap, initial drill at high revolutions with irrigation for marking the

area where the implant will be placed, and subsequent attachment of the initial incisions with ultrasound (ultrasonic scalpel). Subsequently, expansion is performed to separate the ridges (vestibular and lingual) with the motorized expanders. This generates enough space for the insertion of the transitional implant. Finally, the gap located between the plates is filled with freshly activated PRGF-endoret fraction 2 (clot) and a vestibular overcorrection can be performed with autologous bone obtained from the drilling if available or obtained with a bone scraper, embedded in PRGF-Endoret. When the overcorrection and the transitional implant are placed, everything is covered with activated and retracted PRGF-Endoret fraction 1 fibrin membranes. Once the integration time has elapsed, the transitional implant is removed, and the definitive implant is placed in the same bed and with angulation correction (Figure 1).

Data collection was performed by two independent examiners (different from those responsible for the prosthetic or surgical phase). All the data were entered into a database that was managed by computer for statistical analysis.

The implant was the unit of analysis for descriptive statistics in terms of location, implant dimensions, and radiographic measurements. The patient was the unit of measurement for the analysis of age, sex, and medical history. The primary outcome was implant survival and secondary variables were mesial and distal bone loss and final bone crest height achieved after insertion and loading of the implants. In addition, the bone gain achieved was analyzed. For this purpose, the initial ridge was measured in a dental cone-beam performed in the planning phase. Thereby, a line was established from the most apical area of the ridge to the junction between the basal and the alveolar bone. This line divided the residual ridge into two symmetrical segments in the anterior-posterior direction. In the central area of this line, a line was set perpendicular to the first line where the initial measurement of the ridge was taken. This procedure was subsequently repeated in the Cone-beam performed after the integration of the transitional implant and before the insertion of the definitive one. A Shapiro-Wilk test was performed on the obtained data to confirm the normal distribution of the sample.

For the analysis of the difference between the initial and final measurements, a t-student test was performed for paired samples. The significance level was established for a $p < 0.05$. Implant survival was calculated using the Kaplan-Meier method. Data were analyzed with SPSS v15.0 for windows (SPSS Inc., Chicago, IL, USA).

RESULTS

A total of 12 patients were recruited and 16 implants were inserted with the ridge split technique

and width of ≤ 3 mm. Forty percent of the patients were women, with a mean age of 69 ± 5.3 years (range 57 to 72 years). None of the patients were smokers or suffered from pathologies that could have negative repercussions on the bone expansion surgery or on the survival of the implants. The mean initial ridge width was 2.59 mm (± 0.3). The length of the implants studied ranged from 7.5 to 11 mm, the most frequent lengths being 8.5, 10 and 11 mm, with 25% of the cases each one. The diameter of the implants studied ranged from 2.50 to 3.75 mm, the most frequent being 3, 3.3 and 3.5 mm with a ratio of 25% for each of them. Regarding the implant insertion position, the most frequent one was the 34th piece with 25% of the cases, followed by the 35th position with 18.8%. The bone type of most of the implant insertion sites was type II in

81.3% of the cases, and type III for the rest of them. The mean mesial bone loss for all implants was 0.9 mm (± 0.8) and the mean distal bone loss was 1.2 mm (± 0.9). The follow-up time of the implants studied was 128 months (± 8 months), with no implant or prosthesis failures observed during the follow-up time.

The final width of the ridge in the areas studied was 4.7 mm (± 0.9), which represents an increase in width of twice the initial one in 80% of the cases. The remaining 20% represents an increase of the initial 1.5%.

Images 2- 12 show one of the cases included in the study.

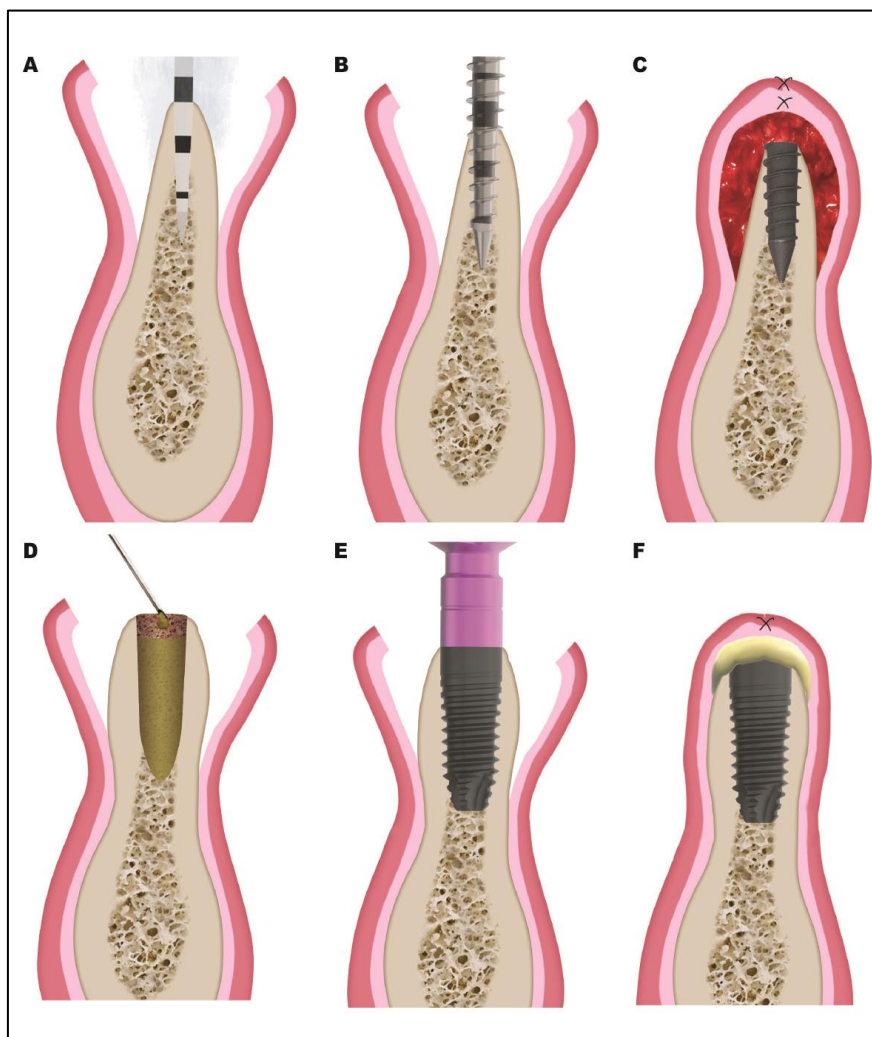


Figure 1: Two-stage ridge split technique. A) Marking with the initial drill on the ridge. This drill is used at high rpm with irrigation. B) Use of the motorized expander to generate a bone bed for the transitional implant. C) Insertion of the transitional implant and overcorrection with autologous bone embedded in PRGF-Endoret. D) Once the receptor bone has matured, the transitional implant is removed. The post-extraction socket is irrigated with PRGF-Endoret before placing the new definitive implant. E) Placement of the definitive implant. F) Inserted implant and application of autologous fibrin membranes covering the surgical site.

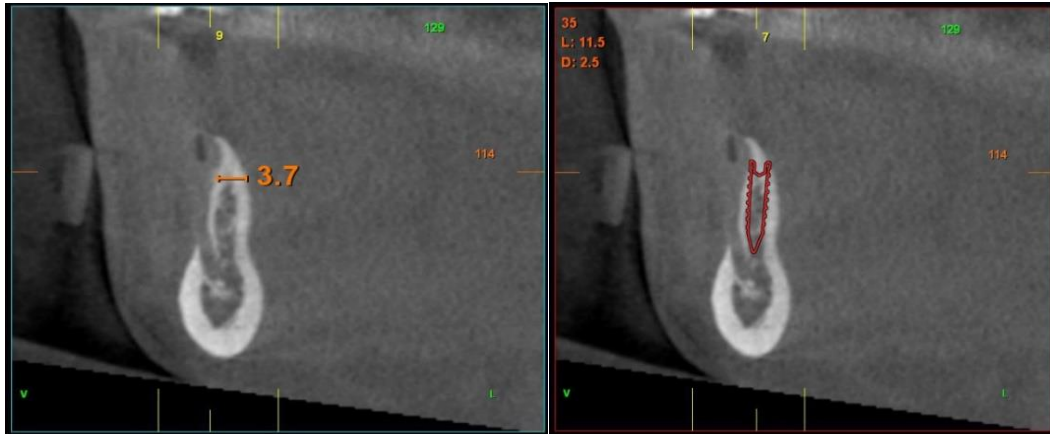

Figure 2

Figure 3

Figures 2 & 3: Dental cone beam planning images of the area corresponding to the lower mandibular first premolars of the case. An extreme horizontal atrophy can be observed, and the insertion of transitional implants is planned after an initial split.

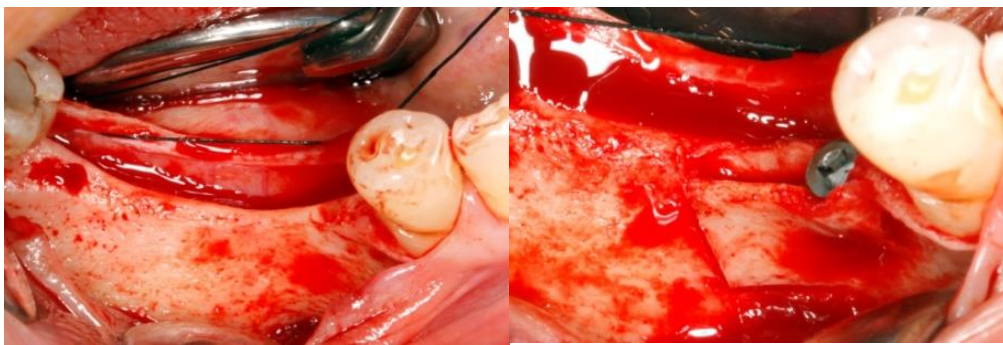


Figure 4

Figure 5

Figures 4 & 5: Images of the initial split with the placement of the transitional implant

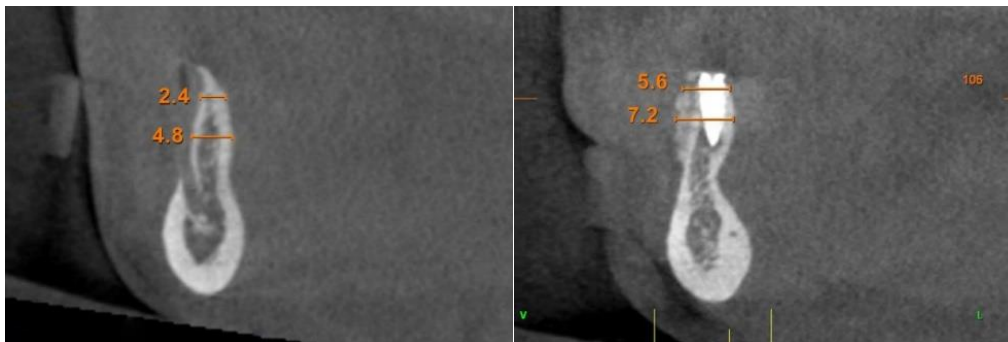


Figure 6

Figure 7

Figures 6 & 7: Initial and final image of the two-stage expansion sites after first-stage consolidation with the transitional implant and overcorrection with autologous bone

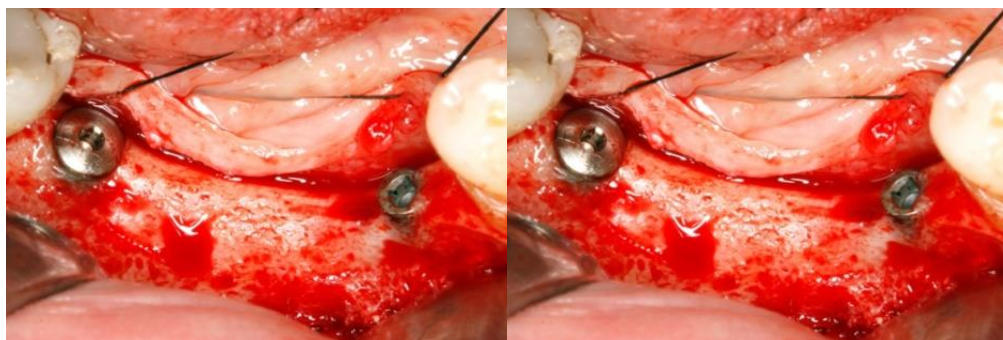


Figure 8

Figure 9

Figures 8 & 9: Clinical image of re-entry in which both soft and hard tissues with a complete controlled expansion can be observed. At this point the implant is replaced

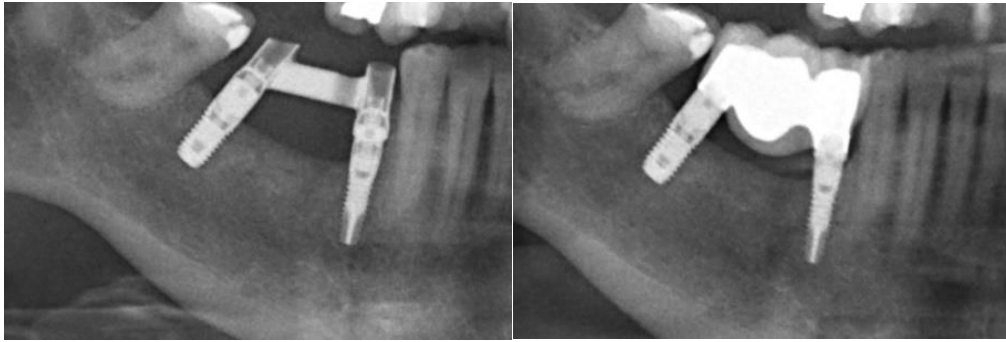

Figure 10

Figure 11

Figures 10 &11: X-ray of the progressive loading prosthesis after insertion of the definitive implant and placement of the definitive prosthesis at 3 months

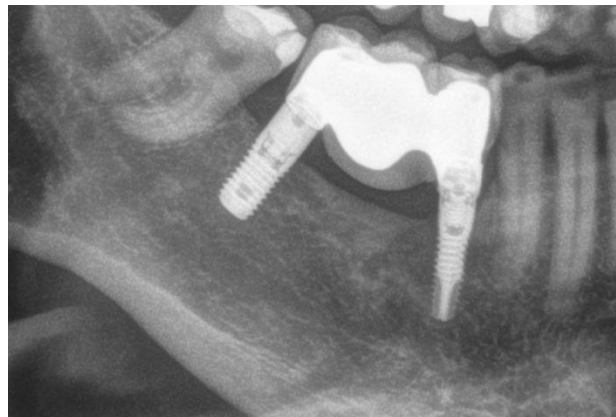

Figure 12: X-ray at 10 years. The stability of the treatment can be observed

DISCUSSION

The Split-crest technique for the rehabilitation of sectors with horizontal bone atrophy is widely used in implant dentistry nowadays, being the mandibular posterior areas the most difficult to rehabilitate due to a corticalized bone with less possibility of distension and less vascularization to generate the union between the two corticals once the technique has been carried out [5]. When the cortex is fractured during the process, there is a risk of fragment detachment and associated crestal bone loss. When this happens, the mobile or detached fragment can be immobilized by means of osteosynthesis screws, but the risk of bone loss in the implants or reduced bone gain in width is increased [27]. As a result of this limitation and the rehabilitation axis of the implants inserted by means of the conventional split, the two- stage expansion technique was developed by means of a transitional implant described by our study group [29, 30]. With this technique, horizontal expansion of the bone volume in two phases is achieved, being predictable and obtaining favorable bone crests for the insertion of a definitive implant and preservation of the peri-implant bone after surgery and loading [29, 30].

Implants inserted using the conventional ridge split technique in mandibular posterior sectors, such as the cases reported in this study, have a survival rate of around 95% [4, 5, 16, 22], the same as those inserted using two-stage expansion, such as those published by

our study group, which are in the 98-100% range [29, 30].

This study has also reported a final ridge of 4.7 mm like that of the conventional split technique or to other regeneration procedures in horizontal atrophies, such as the branch block graft, although this technique presents greater complications [5, 31, 32].

The absence of failures during the follow-up period, in this case 10 years, indicates that the two-stage split is a predictable technique, which can be used in cases of extreme horizontal resorption even in the mandible and posterior sector as the cases shown.

CONCLUSIONS

In cases of extreme bone atrophy in posterior mandibular sectors, a technique that can guarantee sufficient width gain to ensure the integrity of the implants placed, such as the two-stage split, can be an option. In addition to ensuring a correct axis of insertion of the final implant, this technique provides simplicity in handling and excellent predictability.

BIBLIOGRAPHY

1. Mardinger, O., Minkow, B., & Tulchinsky, Z. (2002). Augmentation of narrow ridges for implants rehabilitation--a review. *Refu'at Ha-peh Veha-shinayim* (1993), 19(3), 62-70.

2. Gurler, G., Delilbasi, C., Garip, H., & Tufekcioglu, S. (2017). Comparison of alveolar ridge splitting and autogenous onlay bone grafting to enable implant placement in patients with atrophic jaw bones. *Saudi Medical Journal*, 38(12), 1207-1212.
3. De Groot, R. J., Oomens, M. A. E. M., Forouzanfar, T., & Schulten, E. A. J. M. (2018). Bone augmentation followed by implant surgery in the edentulous mandible: a systematic review. *Journal of Oral Rehabilitation*, 45(4), 334-343.
4. Toti, P., Marchionni, S., Menchini-Fabris, G. B., Marconcini, S., Covani, U., & Barone, A. (2017). Surgical techniques used in the rehabilitation of partially edentulous patients with atrophic posterior mandibles: A systematic review and meta-analysis of randomized controlled clinical trials. *Journal of Cranio-Maxillofacial Surgery*, 45(8), 1236-1245.
5. Blus, C., Szmukler-Moncler, S., Voza, I., Rispoli, L., & Polastri, C. (2010). Split-crest and immediate implant placement with ultrasonic bone surgery (piezosurgery): 3-year follow-up of 180 treated implant sites. *Quintessence international*, 41(6), 463-469.
6. Toti, P., Marchionni, S., Menchini-Fabris, G. B., Marconcini, S., Covani, U., & Barone, A. (2017). Surgical techniques used in the rehabilitation of partially edentulous patients with atrophic posterior mandibles: A systematic review and meta-analysis of randomized controlled clinical trials. *Journal of Cranio-Maxillofacial Surgery*, 45(8), 1236-1245.
7. Tolstunov, L., Hamrick, J. F. E., Broumand, V., Shilo, D., & Rachmiel, A. (2019). Bone augmentation techniques for horizontal and vertical alveolar ridge deficiency in oral implantology. *Oral and Maxillofacial Surgery Clinics*, 31(2), 163-191.
8. Elnayef, B., Porta, C., Del Amo, F. S. L., Mordini, L., Gargallo-Albiol, J., & Hernández-Alfaro, F. (2018). The Fate of Lateral Ridge Augmentation: A Systematic Review and Meta-Analysis. *International Journal of Oral & Maxillofacial Implants*, 33(3), 622-635.
9. Esposito, M., Grusovin, M. G., Felice, P., Karatzopoulos, G., Worthington, H. V., & Coulthard, P. (2010). The efficacy of horizontal and vertical bone augmentation procedures for dental implants: a Cochrane systematic review. *Evidence-based practice: Toward optimizing clinical outcomes*, 195-218.
10. Sanz-Sánchez, I., Ortiz-Vigón, A., Sanz-Martín, I., Figuero, E., & Sanz, M. (2015). Effectiveness of lateral bone augmentation on the alveolar crest dimension: a systematic review and meta-analysis. *Journal of dental research*, 94(9_suppl), 128S-142S.
11. Danza, M., Guidi, R., & Carinci, F. (2009). Comparison between implants inserted into piezo split and unsplit alveolar crests. *Journal of Oral and Maxillofacial Surgery*, 67(11), 2460-2465.
12. Cortese, A., Pantaleo, G., Amato, M., & Claudio, P. P. (2016). Ridge expansion by flapless split crest and immediate implant placement: evolution of the technique. *Journal of Craniofacial Surgery*, 27(2), e123-e128.
13. Jensen, O. T., Cullum, D. R., & Baer, D. (2009). Marginal bone stability using 3 different flap approaches for alveolar split expansion for dental implants—a 1-year clinical study. *Journal of Oral and Maxillofacial Surgery*, 67(9), 1921-1930.
14. Holtzclaw, D. J., Toscano, N. J., & Rosen, P. S. (2010). Reconstruction of posterior mandibular alveolar ridge deficiencies with the piezoelectric hinge-assisted ridge split technique: a retrospective observational report. *Journal of periodontology*, 81(11), 1580-1586.
15. Moses, O., Blasbalg, Y., & Herzberg, R. (2011). Split crest to enlarge horizontal dimension of alveolar ridge. An overview of techniques and case demonstration. *Refu'at Ha-peh Veha-shinayim (1993)*, 28(1), 46-53.
16. Chiapasco, M., Ferrini, F., Casentini, P., Accardi, S., & Zaniboni, M. (2006). Dental implants placed in expanded narrow edentulous ridges with the Extension Crest® device: A 1–3-year multicenter follow-up study. *Clinical Oral Implants Research*, 17(3), 265-272.
17. Scipioni, A., Bruschi, G. B., & Calesini, G. (1994). The edentulous ridge expansion technique: a five-year study. *International Journal of Periodontics & Restorative Dentistry*, 14(5), 451e-459.
18. Sethi, A., & Kaus, T. (2000). Maxillary ridge expansion with simultaneous implant placement: 5-year results of an ongoing clinical study. *International Journal of Oral & Maxillofacial Implants*, 15(4), 491e-499.
19. Anitua, E. (2001). Expansión de cresta con osteotomos: Estado actual. Utilización del plasma rico en factores de crecimiento (PRGF). *Rev Esp Cirug Oral y Maxilofacial*, 23, 158-62.
20. Ella, B., Laurentjoye, M., Sedarat, C., Coutant, J. C., Masson, E., & Rouas, A. (2014). Mandibular ridge expansion using a horizontal bone-splitting technique and synthetic bone substitute: an alternative to bone block grafting?. *International Journal of Oral & Maxillofacial Implants*, 29(1), 135-140.
21. Bassetti, M. A., Bassetti, R. G., & Bosshardt, D. D. (2016). The alveolar ridge splitting/expansion technique: a systematic review. *Clinical oral implants research*, 27(3), 310-324.
22. Korsakova, A. I., Zhadobova, I. A., Klochkov, A. S., Durnovo, S. A., Kochubeynik, A. V., & Durnovo, E. A. (2020). Modified Two-Stage Split Technique for Controlled Ridge Augmentation in Horizontally Atrophic Posterior Mandible: the First Stage of Research. *Современные технологии в медицине*, 12(4 (eng)), 40-46.
23. Anitua, E., Begoña, L., & Orive, G. (2013). Clinical evaluation of split-crest technique with

- ultrasonic bone surgery for narrow ridge expansion: status of soft and hard tissues and implant success. *Clinical implant dentistry and related research*, 15(2), 176-187.
24. Garcez-Filho, J., Tolentino, L., Sukekava, F., Seabra, M., Cesar-Neto, J. B., & Araújo, M. G. (2015). Long-term outcomes from implants installed by using split-crest technique in posterior maxillae: 10 years of follow-up. *Clinical Oral Implants Research*, 26(3), 326-331.
 25. Mahmoud, Z. T., Wainwright, M., & Troedhan, A. (2020). Flapless piezotome crest split achieves comparable outcomes to autologous onlay grafts with significant less patient morbidity and complications—A randomized clinical study. *Journal of Oral and Maxillofacial Surgery*, 78(11), 1953-1964.
 26. Waechter, J., Leite, F. R., Nascimento, G. G., Carmo Filho, L. C., & Faot, F. (2017). The split crest technique and dental implants: a systematic review and meta-analysis. *International journal of oral and maxillofacial surgery*, 46(1), 116-128.
 27. Shibuya, Y., Yabase, A., Ishida, S., Kobayashi, M., & Komori, T. (2014). Outcomes and treatments of mal fractures caused by the split-crest technique in the mandible. *Kobe J Med Sci*, 60(2), E37-42.
 28. Aarabi, M., Tabrizi, R., Hekmat, M., Shahidi, S., & Puzesh, A. (2014). Relationship between mandibular anatomy and the occurrence of a bad split upon sagittal split osteotomy. *Journal of Oral and Maxillofacial Surgery*, 72(12), 2508-2513.
 29. Anitua, E., Begoña, L., & Orive, G. (2012). Controlled ridge expansion using a two-stage split-crest technique with ultrasonic bone surgery. *Implant dentistry*, 21(3), 163-170.
 30. Anitua, E., Begoña, L., & Orive, G. (2011). Two-stage split-crest technique with ultrasonic bone surgery for controlled ridge expansion: a novel modified technique. *Oral surgery, oral medicine, oral pathology, oral radiology, and endodontics*, 112(6), 708-710.
 31. Demarosi, F., Leghissa, G. C., Sardella, A., Lodi, G., & Carrassi, A. (2009). Localised maxillary ridge expansion with simultaneous implant placement: a case series. *British Journal of Oral and Maxillofacial Surgery*, 47(7), 535-540.
 32. Basa, S., Varol, A., & Turker, N. (2004). Alternative bone expansion technique for immediate placement of implants in the edentulous posterior mandibular ridge: a clinical report. *International Journal of Oral & Maxillofacial Implants*, 19(4), 554-558.