

Osteomyelitis of Maxilla – A Clinical Approach and Management

Dr. S. Jayachandran¹, Dr. Sophia Jeba Priya², Dr. E. Pichandavar^{3*}

¹MDS, PhD, FAMS, MBA, MSc, FDS RCPS (Glasgow), FDS RCS (England), Professor and Head of the Department, Department of Oral Medicine and Radiology, Tamil Nadu Government Dental College and Hospital, Chennai – 03, India

²MDS, Assistant Professor, Department of Oral Medicine and Radiology, Tamil Nadu Government Dental College and Hospital, Chennai – 03, India

³BDS, Postgraduate Student, Department of Oral Medicine and Radiology, Tamil Nadu Government Dental College and Hospital, Chennai – 03, India

DOI: [10.36348/sjodr.2022.v07i09.006](https://doi.org/10.36348/sjodr.2022.v07i09.006)

| Received: 17.04.2022 | Accepted: 21.05.2022 | Published: 25.09.2022

*Corresponding author: Dr. E. Pichandavar

BDS, Postgraduate Student, Department of Oral Medicine and Radiology, Tamil Nadu Government Dental College and Hospital, Chennai – 03, India

Abstract

Osteomyelitis is inflammation of the bone which begins as an infection of the medullary cavity with rapid involvement of the haversian systems and extension to the periosteum. Various etiological factors are involved in origin of the disease, among them fungal origin is rare. Specific feature in fungal osteomyelitis is involvement of maxillary sinus. Maxillary osteomyelitis can be classified based on the following causes: traumatic, rhinogenic, and odontogenic. I hereby report a case of fungal osteomyelitis involving maxilla in a 50-year-old man with uncontrolled diabetes mellitus. This specific case was necrosed bone with analysed using Energy dispersive Xray and Scanning electron microscope analysis. This case report highlights the need of oral physician to rule out fungal origin in osteomyelitis.

Keywords: Fungal osteomyelitis, actinomycosis, maxilla, mucormycosis, Scanning Electronic Microscopy, diabetes mellitus.

Copyright © 2022 The Author(s): This is an open-access article distributed under the terms of the Creative Commons Attribution 4.0 International License (CC BY-NC 4.0) which permits unrestricted use, distribution, and reproduction in any medium for non-commercial use provided the original author and source are credited.

INTRODUCTION

The term 'osteomyelitis' is reserved for infections which spread through the bone to a larger extent [1]. It causes compression of blood vessels in the bone, leads to thrombosis and obstruction of blood flow, resulting in necrosis of the bone. Fungal infections like mucormycosis (otherwise termed phycomycosis or zygomycosis) and actinomycosis are rare opportunistic infection affecting more commonly immunocompromised, uncontrolled diabetics and patients under long-term corticosteroid therapy can lead to life-threatening complications if left untreated. This paper aims to enlighten a rare scenario of Osteomyelitis of maxilla with concomitant infection of Mucormycosis and Actinomycosis.

CASE REPORT

A 50 year old male patient reported to the department of Oral Medicine and Radiology with a chief complaint of pain in the left upper back teeth region for past 2 months. The past medical and family history was non-contributory. On general examination,

the patient was moderately built and moderately nourished. Extra-orally, there was pain on palpation over zygomatic buttress and cheek region. Mouth opening was normal. Intra-oral examination revealed greyish yellow necrotic alveolar bone in relation to 16,17,18 region with mixed fluid discharge and mobility of alveolar bone on palpation. Grade III mobility observed in relation to 15, grade II mobility in relation to 14. calculus and stains were present. The patient was advised for CBCT and CBCT section of sagittal and axial view revealed a breach in the floor of the maxillary sinus with soft tissue intensity suggestive of mucosal thickening. 3D reconstructive section shows sequestra in the left maxillary posterior region. CBCT of Coronal section shows loss of trabecular pattern in the center with internal round radiolucent resorptive tracts. Thus, from the CBCT findings osteomyelitis of left maxilla was confirmed. Then planned for excisional biopsy and specimen was sent for histopathologic examination under 10x. Histopathologic report revealed the presence of necrotic bone with empty lacunae, numerous radiating basophilic filaments of bacterial colonies which shows sun ray appearance and fungal

hyphae resembles ribbon like non-separate hyphae with wider branching suggestive of osteomyelitis of maxilla with mixed mucormycosis and actinomycotic fungal infection.

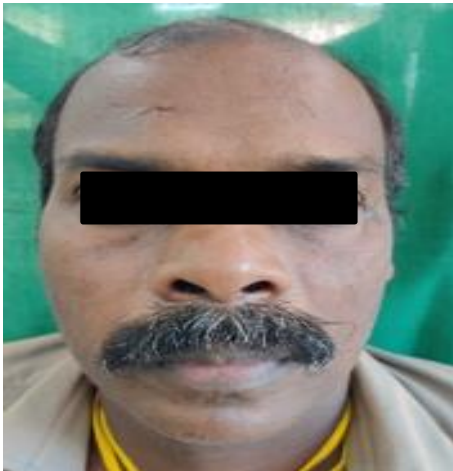

Fig 1: Extraoral photograph

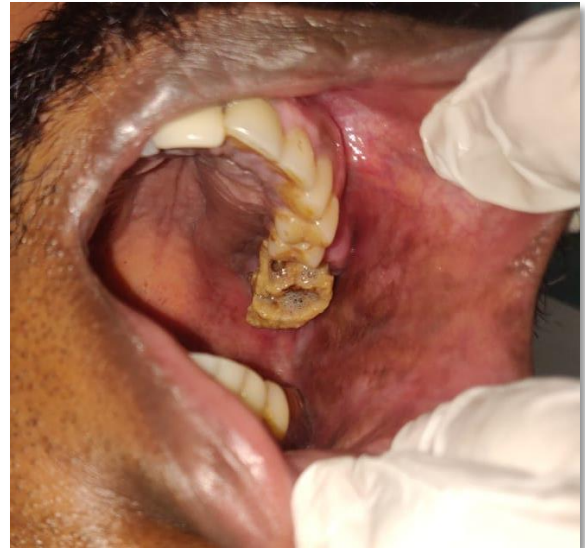

Fig 2: Intraoral picture showing greyish yellow necrotic alveolar bone present

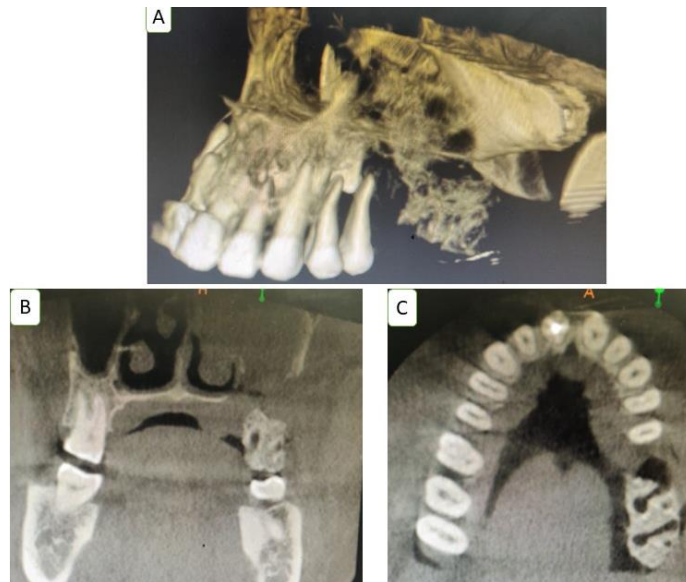


Fig 3: CBCT (A) Showing sequester present left maxilla (B) Showing floor of maxillary sinus breached with soft tissue intensity suggestive of mucosal thickening

DISCUSSION

The term Osteomyelitis was coined by Nalaton in 1844. Various factors are involved in the development of the disease such as trauma, surgical therapy, bacteremia, fungal infection, and systemic diseases that decrease host defence mechanism such as diabetes, malignancy, anemia, radiation, malnutrition, osteoporosis, osteopetrosis and Paget's disease [2]. Drugs which could cause osteomyelitis as a complication on long term use are steroids, Bisphosphonates and chemotherapeutic agents. On exploring the existing literature unveils that *Candida* and *Aspergillosis* were most common causative agents of fungal infections [3] with origin from the dental extraction. In our case, though the patients gave history of extraction of 26, 27 and mucormycetes and

actinomyces were found to be the etiologic agents of fungal infection with osteomyelitis. Despite important medical and surgical advances in the management of patients with osteomyelitis, this disease remains extremely difficult to treat. The relapse rate can be as high as 20%. The usual goal of therapy is the eradication of the infection and restoration of function. Treatment of established osteomyelitis requires aggressive surgical debridement and prolonged antimicrobial therapy in the majority of cases [4]. Treatment of osteomyelitis include surgical debridement combined with antibiotics. The present case of osteomyelitis with fungal infections has been treated by Excisional biopsy with bony curettage along with Beta-lactam antibiotics for two weeks.

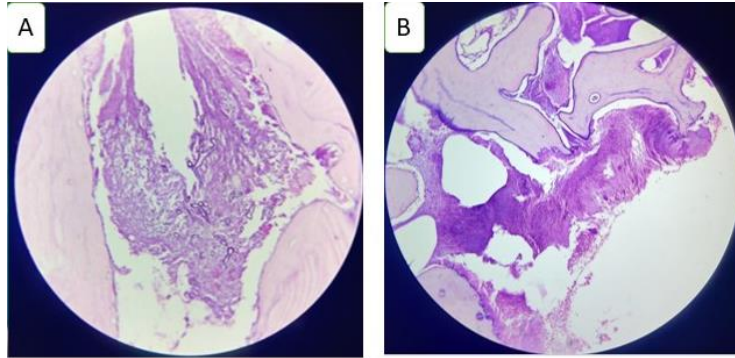


Fig 4: Histopathology picture (A) showing necrotic bone with empty lacunae, numerous radiating basophilic filaments of bacterial colonies which shows sunrays appearance

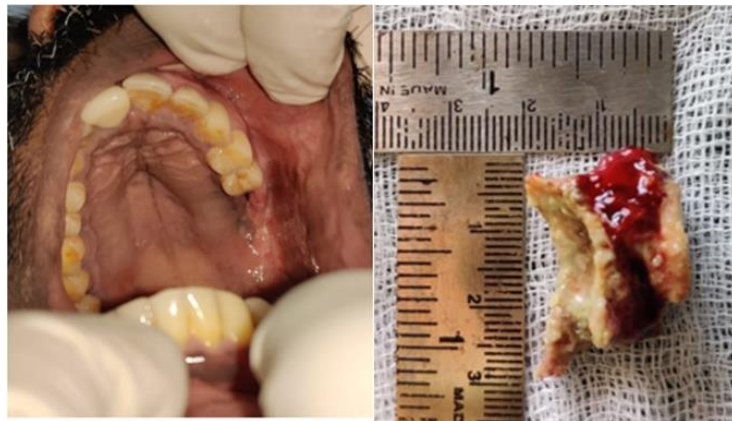

Fig 4: Removal of necrotic bone

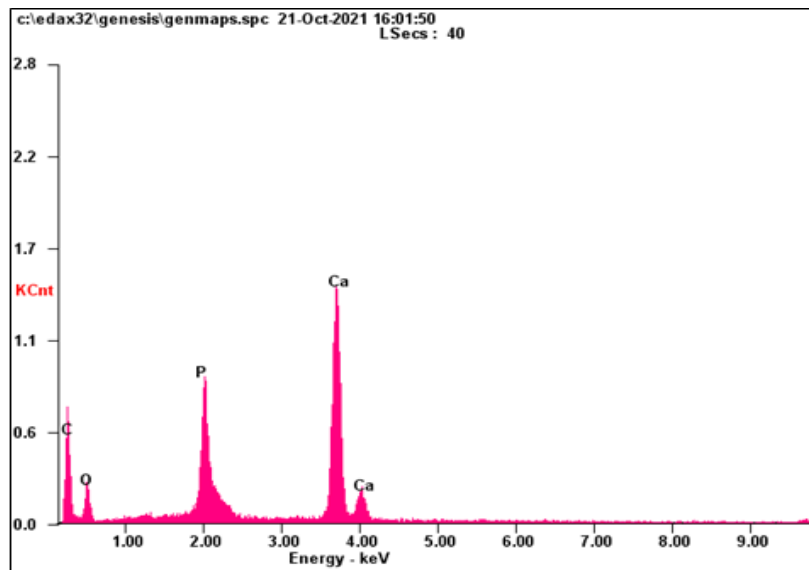


Figure 5

<i>Element</i>	<i>Wt%</i>	<i>At%</i>
<i>CK</i>	58.86	72.76
<i>OK</i>	20.19	18.73
<i>PK</i>	06.81	03.27
<i>CaK</i>	14.14	05.24
<i>Matrix</i>	Correction	ZAF

Figure 6: SEM-EDX analysis

Hallmark of mucormycosis is vascular invasion resulting in thrombosis and tissue infarction/necrosis. In most cases, the infection is relentlessly progressive and results in death unless treatment with a combination of surgical debridement and antifungal therapy is initiated [5]. Maxillary necrosis can occur due to bacterial infections such as osteomyelitis, viral infections such as herpes zoster or fungal infections such as mucormycosis, aspergillosis. Other causes other than infections include trauma, radiation, use of long-term corticosteroids, disorders of lipid metabolism such as Gaucher's disease [6]. Macbeth in 1952 classified the etiology of osteomyelitis of maxilla into traumatic, rhinogenic and odontogenic [4]. This case belongs to the last group [7]. Actinomycosis is chronic, rare granulomatous disease, caused by anaerobic or microaerophilic Gram positive filamentous bacilli, from the Actinomycetaceae family (genus *Actinomyces*) [8]. More than 30 species has been isolated, among which *A israelii* has been detected as the most common human commensal as well as pathogen [9]. They comprise the oral microbiota within gingival crevices, periodontal pockets, dental plaque, carious teeth, tonsillar crypts [10]. Actinomycosis produces a localised inflammatory reaction which is a granuloma with central suppuration having peripherally giant cells and fibroblasts. The abscess in the centre contains yellow sulphur granules with radiating filaments (Splendore-Hoepli phenomenon) mimicking *ray fungus*, a misnomer [11]. In the oral cavity, actinomycosis can mimic an abscess of periodontal origin, gingival abscess or chronic periodontitis. Thus, a prudent diagnosis is required as the treatment is quite demanding. The tradition of treatment revolves around penicillin in high doses and prolonged periods after adjunct surgical intervention [12].

Treatment modality of fungal osteomyelitis includes control of the underlying risk factors, antifungal therapy, surgical debridement, supportive therapy and surgical or prosthetic rehabilitation (RECONSTRUCTION) is very important because of the restoration of quality of life to the pre-morbid state.

CONCLUSION

Osteomyelitis of maxilla is a rare entity requiring timely diagnosis and management. If left untreated leads to complications requiring surgical

reconstruction. It also has higher chances of recurrence if failed to follow up on regular basis.

REFERENCE

1. Shafer, textbook of oral pathology, seventh edition.
2. Klenerman, L. (2007). A history of osteomyelitis from the Journal of Bone and Joint Surgery: 1948 to 2006. *The Journal of bone and joint surgery. British volume*, 89(5), 667-670.
3. Arani, R., Shareef, S. N. H., & Khanam, H. M. (2019). Mucormycotic osteomyelitis involving the maxilla: A rare case report and review of the literature. *Case reports in infectious diseases*, 2019.
4. Singh, M., Singh, S., Jain, J., & Singh, K. T. (2010). Chronic suppurative osteomyelitis of maxilla mimicking actinomycotic osteomyelitis: a rare case report. *National Journal of Maxillofacial Surgery*, 1(2), 153.
5. Spellberg, B., Edwards Jr, J., & Ibrahim, A. (2005). Novel perspectives on mucormycosis: pathophysiology, presentation, and management. *Clinical microbiology reviews*, 18(3), 556-569.
6. Kumar, J. A., Babu, P., Prabu, K., & Kumar, P. (2013). Mucormycosis in maxilla: Rehabilitation of facial defects using interim removable prostheses: A clinical case report. *Journal of pharmacy & bioallied sciences*, 5(Suppl 2), S163-165.
7. Shamanna, K., Rao, R., & Banu, A. (2014). Osteomyelitis of Maxilla: A Rare Case, *J Pub Health Med Res*, 2(1), 50-52.
8. Bonnefond, S., Catroux, M., Melenotte, C., Karkowski, L., Rolland, L., Trouillier, S., & Raffray, L. (2016). Clinical features of actinomycosis: A retrospective, multicenter study of 28 cases of miscellaneous presentations. *Medicine*, 95(24).
9. Wong, V. K., Turmezei, T. D., & Weston, V. C. (2011). Actinomycosis. *Bmj*, 343, d6099.
10. Mohan, H. (2002). Granulomatous Inflammation. *Essential Pathology for Dental Students*. 2nd ed. Jaypee; pp. 123-124.
11. Amrita, S. Actinomycosis affecting the maxilla: A case report of rare occurrence.
12. Mendhe, D., Wankhede, P., Wanjari, M., & Alwadkar, S. (2021). Mucormycotic osteomyelitis of maxilla post-COVID patient: a case report. *The Pan African Medical Journal*, 39.