

## Orthodontic-Surgical Approach for Treating Skeletal Class III Malocclusion: About A Case Report

Ghassen Kallel<sup>1\*</sup>, Wiem Ben Amor<sup>2</sup>, Karima Dabbar<sup>1</sup>, Ines Dallel<sup>3</sup>, Samir Tobji<sup>3</sup>, Adel Ben Amor<sup>3</sup>

<sup>1</sup>Resident, Department of Orthodontics, Dental Clinic of Monastir, Tunisia

<sup>2</sup>Assistant Professor, Department of Orthodontics, Dental Clinic of Monastir, Tunisia

<sup>3</sup>Professor, Department of Orthodontics, Dental Clinic of Monastir, Tunisia

DOI: [10.36348/sjodr.2022.v07i09.003](https://doi.org/10.36348/sjodr.2022.v07i09.003)

| Received: 18.07.2022 | Accepted: 30.08.2022 | Published: 03.09.2022

\*Corresponding author: Ghassen Kallel

Resident, Department of Orthodontics, Dental Clinic of Monastir, Tunisia

### Abstract

Class III skeletal malocclusions are considered to be ones of the most challenging deformities for orthodontists, they may present several forms, among which maxillary deficiency is the most frequent. This type of malocclusion is usually treated with combination of orthodontics and orthognathic surgery in order to obtain an adequate occlusion and facial esthetics. This report presents the treatment of a young female patient aged 16 years and 4 months with Class III skeletal malocclusion, and a severe anterior crowding with palatal displacement of the maxillary lateral incisors and ectopic canines, as well as an Angle Class I molar relationship occlusion on both sides associated with significant dento-alveolar compensation: The upper incisors were proclined while the lower incisors were vertical, and a maxillary midline shift. Clinical examination has also revealed a retrusive maxilla, underdeveloped cheekbones, and a flat facial profile. The treatment was performed in three phases: first, presurgical orthodontic preparation including extraction of the maxillary first premolars and mandibular second premolars in order to perform the orthodontic decompensation, secondly, orthognathic surgery which consists of maxillary advancement to improve soft-tissue projection of the midface, and finally, orthodontic finishing for the conclusion of the case. At the end of the treatment, the main objectives were successfully achieved, providing the patient with adequate masticatory function, pleasant facial esthetics and especially better self-esteem.

**Keywords:** Class III malocclusion, skeletal discrepancy, orthodontic treatment, orthognathic surgery.

**Copyright © 2022 The Author(s):** This is an open-access article distributed under the terms of the Creative Commons Attribution 4.0 International License (CC BY-NC 4.0) which permits unrestricted use, distribution, and reproduction in any medium for non-commercial use provided the original author and source are credited.

### INTRODUCTION

Skeletal class III malocclusion is defined by an advanced position of the mandible in relation to the maxilla. It constitutes 9.3% of the total cases managed according to a recent study in the Tunisian population [1]. The diagnosis of skeletal class III malocclusion is based on lateral cephalometric radiograph: ANB angle  $< 0^\circ$  and AoBo measurement  $< -2$  mm. This malocclusion can be manifested either by a mandibular prognathism, a maxillary retrusion or both [2].

Maxillary deficiency is the most frequent, accounting for 60% to 63% of this type of malocclusion [3]. Clinically, these patients have a concave facial profile associated with a deficiency in the middle third of the face, flattening cheekbones, and often a protruding lower lip relative to the upper lip; the basal bone deficiency is mirrored in the facial soft tissues

causing a poor esthetic appearance that affects the patient's self-image. Intraoral observation reveals a narrow maxillary arch relative to the mandibular arch, as well as an excessive buccal inclination of the upper incisors and lingual inclination of the lower incisors in an attempt to compensate for actual maxillomandibular discrepancy [4].

Although skeletal Class III malocclusion are not the most numerous, they are considered among the most difficult to manage, and they are often a source of multiple concerns even for the most experienced clinicians. There are generally three main treatment alternatives: growth modification by orthopedic early treatment for patients under the pubertal growth spurt, and dentoalveolar compensation (camouflage treatment) or orthodontic- surgical approach for adult patients.

This case report presents the treatment of a class III malocclusion with skeletal sagittal and vertical discrepancies whose magnitude required an orthodontic-surgical treatment for reestablishment of normal and functional occlusion and adequate facial esthetics.

## PRESENTATION OF THE CASE

### Clinical examination and diagnosis

A female patient aged 16 years and 4 months consulted with the Dento-Facial Orthopedics Department at the dental medicine clinic of Monastir, Faculty of Dental Medicine, University of Monastir, Tunisia, for a palatally displaced maxillary right lateral incisor and unpleasant facial appearance. No systemic or medical abnormalities were described.

\*The extraoral examination showed from the frontal view a symmetrical face with a parallelism at the horizontal lines of the face and a straight medial sagittal plane, underdeveloped cheekbones, and a flat nasolabial fold as a result of a retrusive maxilla. She also presented a passive lip competence with poor volume, an inadequate lip vermilion, especially at the upper lip, as well as a narrow smile (Figure 1A).

The profile analysis showed a flat profile, in addition to a Class III aspect consequent to maxillary and zygomatic deficiencies. She also presented, an erased labiomental fold, a retruded upper lip and a well

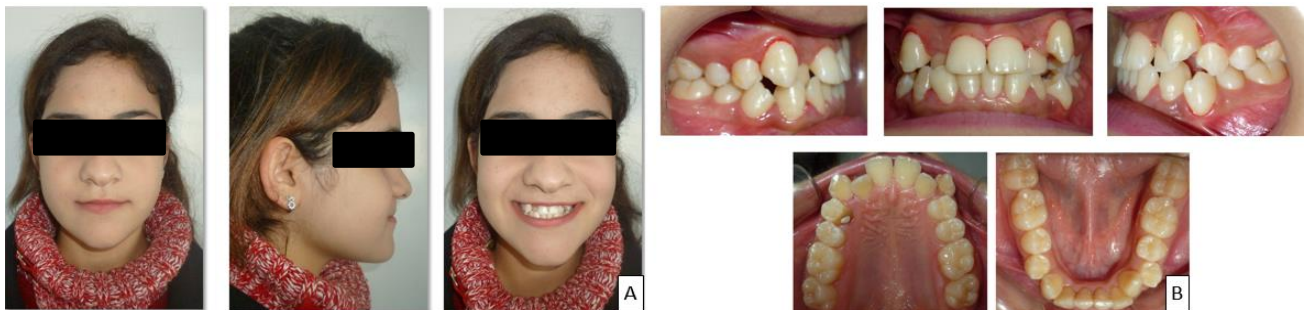positioned lower lip. Furthermore, the chin-neck line was appropriate, and the chin appearance was satisfactory (Figure 1A).

\*The intra-oral examination showed an unsatisfactory oral hygiene, and a healthy periodontal status, with no bleeding on probing but with thin periodontal tissues (class III : according to Maynard and Wilson classification). The upper dental arch showed a severe anterior crowding with palatal displacement of the maxillary lateral incisors and ectopic canines. The lower dental arch exhibited moderate crowding in the premolar area (Figure 1B).

Moreover, the occlusal examination revealed an Angle Class I molar relationship occlusion on both sides associated with significant dental compensation : The upper incisors were proclined while the lower incisors were vertical. Also, the maxillary midline was deviated 3 mm towards the left of the midsagittal plane (Figure 1B).

Furthermore, no symptoms or signs of any temporo-mandibular joint (TMJ) disorder were observed, and maximal opening and lateral and anterior movements were within normal limits.

\*The functional examination revealed a mixed ventilation with mouth breathing predominance, and lingual thrust during speech and swallowing.

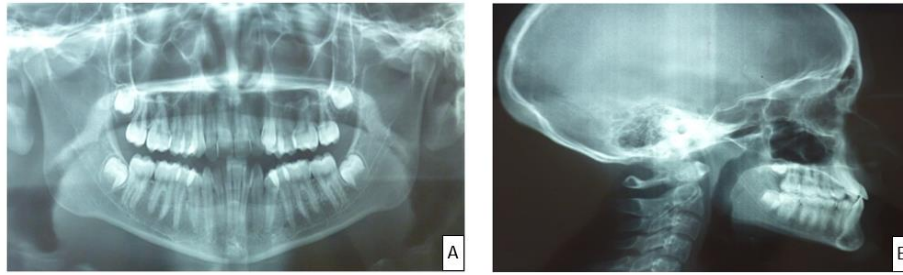


**Fig 1: Pretreatment photographs. A, facial photographs. B, intra-oral photographs**

\*The analysis of plaster models showed negative dentoalveolar discrepancy in the mandibular arch (-14.0 mm) and confirmed the maxillary midline shift 3 mm to the left. The overjet was irregular (-1 to 2 mm).

\*The panoramic radiograph showed that all teeth were present with the third molars under development. There were no supernumerary teeth. The crown-root ratios were normal with good alveolar bone levels, no bone pathology and no root resorption. In addition, the mandibular condyles, nasal floor and maxillary sinuses appeared normal (Figure 2A).

\*The lateral cephalometric radiograph revealed a Class III skeletal malocclusion ( $ANB = -3^\circ$ ) ( $AoBo = -5\text{mm}$ ) with a maxillary retrusion ( $SNA = 79^\circ$ ) and a normal positioned mandible ( $SNB = 82^\circ$ ) in relation to the anterior skull base. Additionally, a hypodivergent vertical skeletal pattern was noted ( $SN/GoGn = 28^\circ$  and  $FMA = 14^\circ$ ). Furthermore, The maxillary incisors presented increased axial inclination and were protruded in relation to their alveolar base ( $I/F = 130^\circ$ ) while the mandibular incisors presented decreased axial inclination and were retruded in relation to their alveolar base ( $IMPA = 86^\circ$ ) (Figure 2B).



**Fig 2: Pretreatment radiographs. A, panoramic radiograph. B, lateral cephalometric radiograph**

**Treatment goals**

The treatment goals for this patient were as follows : (1) To obtain pure nasal breathing and functional swallowing. (2) To correct the skeletal Class III pattern. (3) To resolve the dental crowding and the alveolar compensation created by the malocclusion. (4) To correct the maxillary dental midline deviation. (5) To establish normal Class I canine and molar relationships with normal overjet and overbite. (6) To Improve facial esthetics and smile.

**Treatment Alternative**

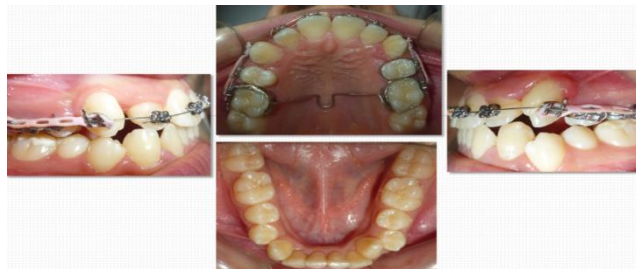The chosen treatment was: a combined orthodontic surgical approach involving the extraction of the maxillary first premolars and mandibular second premolars in order to perform the orthodontic

decompensation. Then, the surgical approach would consist of maxillary advancement to improve the midface soft-tissue projection, completed with a post-surgical finishing phase.

**Treatment Progress**

Initially, the maxillary first premolars were extracted followed by placement of the orthodontic fixed appliances with Roth prescription brackets (slot 0.022” x 0.028”) up to the second molars and reinforcement of the maxillary anchorage with a transpalatal arch.

Then, the upper canines were retracted on a 0.018” stainless steel archwire (Figure 3).

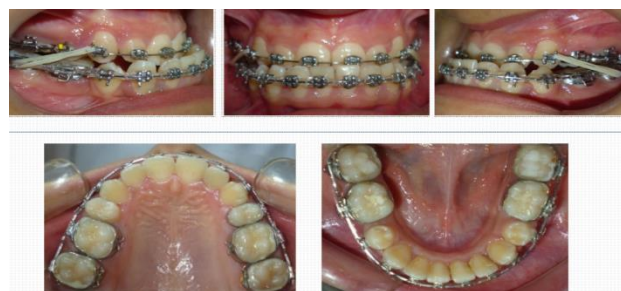

**Fig 3: Progress photographs : Upper canines retraction on a 0.018” ss archwire**

Afterwards, the mandibular second premolars were extracted followed by placement of the orthodontic fixed appliances up to the second molars. Then, dental leveling and alignment of the maxillary and the mandibular dental arches were performed using the following orthodontic archwire sequence : 0.014”, 0.016”, 0.018” and 0.017” x 0.025” Nickel Titanium archwire followed by 0.017” x 0.025” and 0.018” x 0.025” stainless steel archwire.

After leveling and alignment, the maxillary anterior teeth were retracted on a 0.018” x 0.025” stainless steel archwire, maintaining the anchorage by using class II intermaxillary elastic mechanics.

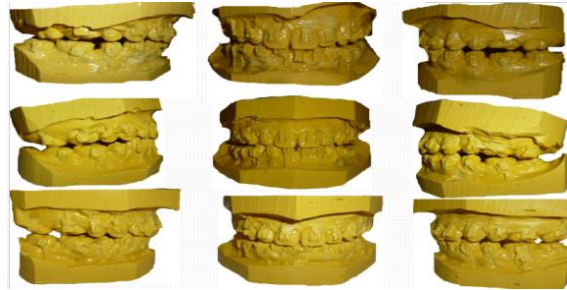After that, dental decompensation was completed by aggravation of the Class III malocclusion by Class II mechanics (Figure 4).



**Fig 4: Progress photographs : aggravation of the cl III malocclusion by using class II intermaxillary elastics**

Next, the mandibular arch was slightly contracted by increasing the buccal root torque to the molars. In the maxillary arch, buccal crown torque to the molars was increased, thus contributing to the correction of the transverse relationship between the dental arches.

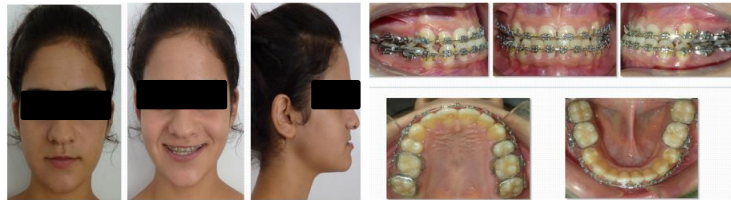At this phase, dental impressions were taken to help in the presurgical preparation. The intercuspitation was checked by occluding the plaster models that were periodically obtained until satisfactory occlusion was attained for performing the surgery (Figure 5).



**Fig 5: Presurgical dental casts**

In sequence, surgical 0.019” x 0.025” stainless steel archwires with welded hooks were installed and the patient was referred to orthognathic surgery, which

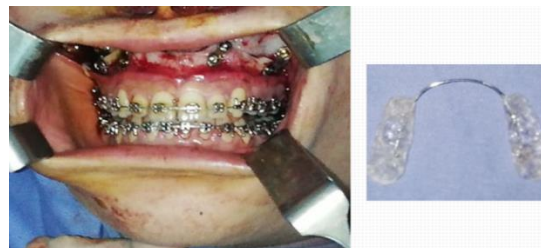was planned according to facial analysis, predictive cephalometric tracing, and preparation of the surgical guide (Figure 6).



**Fig 6: Presurgical photographs showing upper and lower surgical 0.019” x 0.025” stainless steel archwires for intermaxillary fixation**

At this stage, the surgical procedure, including maxillary advancement of 6 mm by a Lefort I osteotomy, was completed and the patient returned for orthodontic finishing comprising closing minor

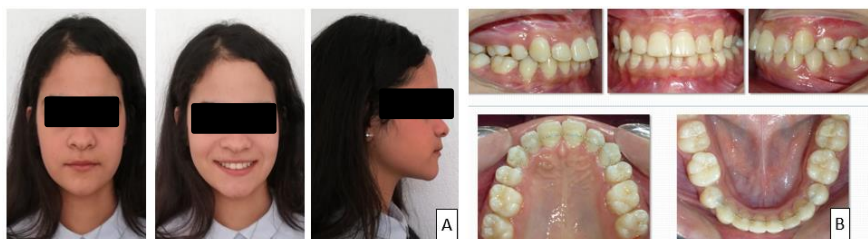diastemas, wearing intermaxillary elastics, performing wire artistic bends and Occlusal equilibration for the conclusion of the case (Figure 7).



**Fig 7: Surgical stage**

Finally, after the active treatment phase, all appliances were removed, retention was performed with a bonded stainless steel lingual premolar-to-premolar

fixed retainer in both the maxillary and the mandibular arches and posttreatment records were taken (Figure 8).



**Fig 8: Post-treatment photographs. A, facial photographs. B, intra-oral photographs**

**Treatment Results**

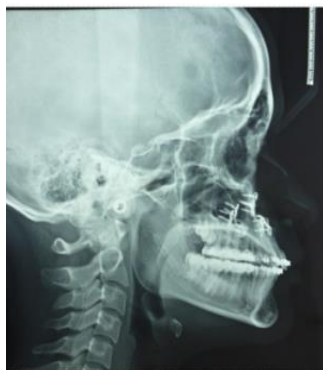Correction of skeletal and dental problems allowed the occlusal, functional, and esthetic goals to be achieved:

A significant improvement was seen in facial esthetics. The facial profile become more harmonious: with a proper naso-labial angle, a raised nose tip, and an improvement of the zygomatic prominence. Also, a good lip contour with passive lip seal as well as a pleasant smile were acquired (Figure 8A).

Furthermore, class I Angle relationship with good alignment of the teeth, a proper overjet and overbite were achieved, and coincident midlines were

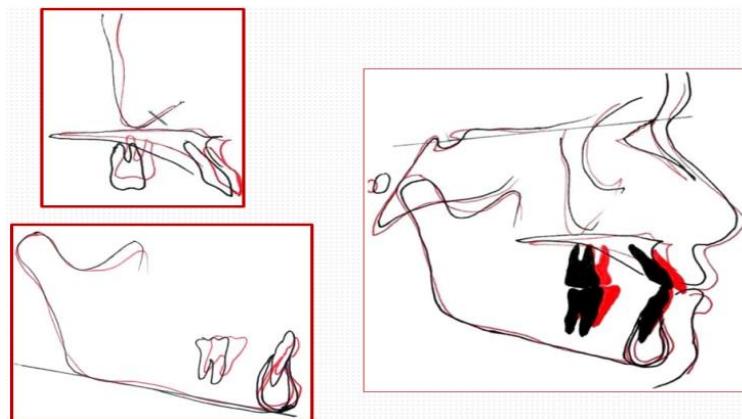
acquired. Additionally, functional dynamic occlusion was procured with lateral movement guided by the canines and protrusive movement by the incisors (Figure 8B).

Moreover, final cephalometric analysis showed a class I relationship with a change in values of the ANB angle from  $-3^\circ$  to ideal  $2^\circ$ . The maxillary incisors were retruded and lingually tipped, and the mandibular incisors were protruded and had their axial inclination increased (Figure 9). Total and partial superimposition of initial and final cephalometric tracings revealed the changes occurred with the treatment (Figure 10).



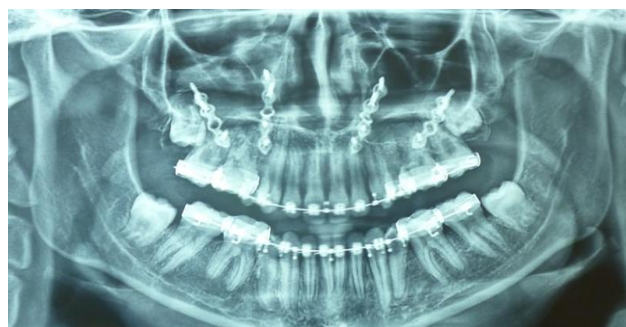Cephalometric values	Initial values	Final values
SNA	$79^\circ$	$85^\circ$
SNB	$82^\circ$	$82^\circ$
ANB	$-3^\circ$	$2^\circ$
AOBO	-5 mm	2mm
FMIA	$82^\circ$	$71^\circ$
IMPA	$86^\circ$	$95^\circ$
FMA	$14^\circ$	$15^\circ$
GOGn/SN	$28^\circ$	$28^\circ$
I/i	$130^\circ$	$132^\circ$
I/F	$130^\circ$	$116^\circ$

**Fig 9: Final cephalometric analysis**



**Fig 10: Total and partial superimposition of initial and final cephalometric tracings**

Lastly, a panoramic radiograph shows satisfying root parallelism and good bone healing (Figure 11).



**Fig 11: Post-treatment panoramic radiograph**

## DISCUSSION

The Class III malocclusions may present a variable severity, with different levels of treatment difficulty. The orthodontic treatment usually becomes more complex when skeletal involvement is more important [5].

For growing patients, orthopedic early treatment can be carried out to coordinate maxillomandibular development [6, 7].

However, for adult patients, there are two main options: Essentially, camouflage treatment can be planned for patients who are more interested in less invasive interventions and who do not present esthetic complaints, or an orthodontic-surgical approach can be established for the cases with severe skeletal vertical and anteroposterior discrepancies [8].

In the case presented in this report, the patient chief complaint was not only the dental crowding, but also the facial appearance, especially the middle third deficiency resulting in a significant psychosocial impact. For this reason, dentoalveolar compensation approach cannot be suggested for this patient as this could lead to many complications comprising periodontal lesions, damage to the temporomandibular joint, inability to entirely correct the malocclusion, and, principally, patient dissatisfaction with the treatment result [4].

Therefore, an orthodontic-surgical treatment was well indicated for this case to manage skeletal malocclusion and to improve facial esthetics.

The surgical correction of class III malocclusion can be managed by several methods: by the Obwegeser osteotomy set-back or by the Lefort I osteotomy to advance the maxilla, or both. For the case described, sagittal skeletal discrepancy was moderate, so Lefort I osteotomy was selected. Furthermore, it was demonstrated that this type of osteotomy can widen the upper airways, which promotes nasal breathing [9].

Nevertheless, chronologically, the surgical phase can be done either after orthodontic preparation or before starting the orthodontic treatment: the « surgery first approach » is an interesting alternative which allows short-term treatment and a better psychological aspect as it avoids dental decompensation which is poorly accepted by patients [10, 11]. That option was not an appropriate approach in this case since we could not obtain a stable occlusion and because the patient had an Angle classe I relationship; therefore, the decompensation must be achieved first.

Finally, the treatment outcomes were very favorable, all objectives were fulfilled: there was significant improvement in facial profile and esthetics with adequate maxillary advancement to

sufficiently protrude the upper lip, fill in the facial middle third, and elevate the nose tip, in addition to the obtention of functional and balanced occlusion.

## CONCLUSION

Class III skeletal malocclusion is a great challenge for orthodontists; A detailed diagnosis with a rigorous analysis of the occlusal, skeletal and soft tissue components has to be performed. Also, a correct planning as well as an adequate execution of the treatment plan are determinant factors for a successful result and long-term stability.

In the case described, achieving planned treatment goals was so much challenging. A multidisciplinary approach was needed in front of such severe skeletal malocclusion, and a good communication between orthodontist and maxillofacial surgeon was performed in order to succeed orthodontic-surgical treatment.

**Declaration of patient consent:** The authors certify that they have obtained all appropriate patient consent.

## REFERENCES

1. Harakati, I., Hadded, O., Jemmali, F., Yemni, A., & Boughzala, A. (2016). Frequency of malocclusions in 1383 cases of children supported by the National Health Insurance Fund. *Revue Méditerranéenne d'Odonto-Stomatologie (R.M.O.S)*, 3.
2. Delaire, J. (1997). Maxillary development revisited: relevance to the orthopaedic treatment of Class III malocclusions. *European Journal of Orthodontics*, 19(3), 289-311.
3. Turley, P. K. (1988). Orthopedic correction of Class III malocclusion with palatal expansion and custom protraction headgear. *Journal of clinical orthodontics: JCO*, 22(5), 314-325.
4. Janson, M., Janson, G., Santana, E., de Castro, R. C. F. R., & de Freitas, M. R. (2010). Orthodontic-surgical treatment of Class III malocclusion with extraction of an impacted canine and multi-segmented maxillary surgery. *American journal of orthodontics and dentofacial orthopedics*, 137(6), 840-849.
5. Baccetti, T., McGill, J. S., Franchi, L., McNamara Jr, J. A., & Tollaro, I. (1998). Skeletal effects of early treatment of Class III malocclusion with maxillary expansion and face-mask therapy. *American Journal of Orthodontics and Dentofacial Orthopedics*, 113(3), 333-343.
6. Anne Mandall, N., Cousley, R., DiBiase, A., Dyer, F., Littlewood, S., Mattick, R., ... & Worthington, H. (2012). Is early class III protraction facemask treatment effective? A multicentre, randomized, controlled trial: 3-year follow-up. *Journal of orthodontics*, 39(3), 176-185.

7. Xu, Y., Zhu, P., Le, L., & Cai, B. (2014). Conservative treatment for a growing patient with a severe, developing skeletal Class III malocclusion and open bite. *American Journal of Orthodontics and Dentofacial Orthopedics*, 145(6), 807-816.
8. Janson, G., & Maranhão, O. B. V. (2017). Compensatory Class III malocclusion treatment associated with mandibular canine extractions. *Dental press journal of orthodontics*, 22, 86-98.
9. Fındık, Y., Büyükçavuş, M. H., Koçer, G., Yazıcı, T., & Baykul, T. (2021). Comparison of psychosocial and aesthetic features of class III malocclusion after orthognathic surgery: Conventional approach versus surgery-first approach. *Journal of Stomatology, Oral and Maxillofacial Surgery*.
10. Barrabé, A., Meyer, C., Bonomi, H., Weber, E., Sigaux, N., & Louvrier, A. (2018). Surgically assisted rapid palatal expansion in class III malocclusion: Our experience. *Journal of stomatology, oral and maxillofacial surgery*, 119(5), 384-388.
11. He, J., Wang, Y., Hu, H., Liao, Q., Zhang, W., Xiang, X., & Fan, X. (2017). Impact on the upper airway space of different types of orthognathic surgery for the correction of skeletal class III malocclusion: A systematic review and meta-analysis. *International Journal of Surgery*, 38, 31-40.