

A Systematic Review of Traditional Radiology: Conservative Therapy in Endodontics

Nezar Boreak^{1*}, Alshaymaa Hakami¹, Shaker Hakami¹, Hussain Nahari¹, Maan Alhakami¹, Ahmad Alrajhi¹, Mohammed Al Dira¹, Hamood Mahdali¹, Abdulmajeed Kariri¹, Fatima Sultana¹

¹Jazan University, Jazan, Saudi Arabia

DOI: [10.36348/sjodr.2022.v07i12.001](https://doi.org/10.36348/sjodr.2022.v07i12.001)

| Received: 06.10.2022 | Accepted: 11.11.2022 | Published: 03.12.2022

*Corresponding author: Nezar Boreak
Jazan University, Jazan, Saudi Arabia

Abstract

Introduction: Conservative endodontics advocates sparingly altering standard procedures in order to preserve tooth structure if possible. Every bit of structure that is saved is a benefit, according to conservative endodontics. As a result, conservative endodontics may be performed by both endodontists and general dentists. **Aim and Objective:** The comprehensive evaluation of conventional radiology employed in endodontic conservative therapy has as its primary goal the endodontic conservative therapy. **Methodology:** The electronic databases that underwent rigorous individual searches were Embase, Google Scholar, LILACS and MEDLINE using the Ebsco search engine, PubMed, Science Direct, Scopus, and Web of Science. **Results:** Conventional radiography (CR) is without a doubt the most widely used imaging method for evaluating root canals due to its availability, affordability, and convenience. Digital Radiography (DR) has gained popularity as a replacement for CR because it offers better image quality and enables the dentist to do radiographic exams with less radiation exposure. **Conclusion:** For root canal treatment, radiographic diagnostic value is essential. Additionally, this technique is utilized to find procedural errors, resorptive defects, and fractures. Radiographic examinations are important because they provide details on how difficult the therapy is.

Keywords: Traditional radiography, conservative radiography, conservative endodontic therapy, root canal treatment, X ray radiography.

Copyright © 2022 The Author(s): This is an open-access article distributed under the terms of the Creative Commons Attribution 4.0 International License (CC BY-NC 4.0) which permits unrestricted use, distribution, and reproduction in any medium for non-commercial use provided the original author and source are credited.

INTRODUCTION

Endodontics

The department of dentistry known as endodontics deals with the dental pulp and the tissues that surround a tooth's roots. Dentistry's field of endodontics deals with the diagnosis, treatment, and prevention of conditions affecting the dental pulp and its surrounding tissues. The nerve, blood and lymphatic vessels, and connective tissue are all found in the soft dental pulp, which is located in the tooth's center [1].

Greek words "endo" and "odont" are used to denote "within" and "tooth," respectively. The delicate pulp tissue inside the tooth is treated by endodontic therapy, often known as root canal therapy. The root canal therapy involves extracting infected tooth pulp and replacing it with filling material. This is the main focus of endodontic practice [2].

The connected blood arteries in the jaw continue to sustain the tooth after the pulp has been

removed. Even if the fibers holding the tooth in the jawbone are still active, the tooth is thus thought to be dead. Local anesthetic is used to do operations on the pulp. A natural tooth implanted in the jaw maintains the integrity of the dental arch and can tolerate around ten times more pressure than artificial teeth, therefore maintaining the natural tooth in this way benefits both aesthetics and functionality [3].

Endodontist

A dentist with a focus on tooth preservation is known as an endodontist. After graduating from dentistry school, endodontists undergo a minimum of two years of professional training in the field. They carry out both simple and complicated endodontic operations, such as root canal therapy, endodontic surgery, and specialized techniques to save teeth after severe dental damage. Endodontists are skilled in effectively treating a variety of complicated endodontic disorders because they concentrate their practice on particular treatments such root canal therapy, surgery,

and trauma. Endodontists employ cutting-edge technologies and specific procedures that offer them a highly precise image of the interior of the tooth and enable speedy and comfortable treatment [4].

Endodontic Therapy

The "*protection and restoration of apical periodontitis*" is the proclaimed aim of endodontic therapy. Much of the endodontic study conducted in the last 60 years has been concentrated on finding effective treatments for apical periodontitis (AP). A clinical component that centers on patient complaints and a time-dependent radiographic examination of changes in bone volume around root apices make up the two components of the monitoring of AP development [5].

Endodontist have had to make clinical choices amid a lot of ambiguity throughout the years. The radiographic restoration of periapical tissues is highly valued by physicians, although asymptomatic individuals who want their teeth to last a long time may not care about this outcome measure. A result that is focused on the process refers to how the operator uses their dexterity to meet the technical requirements of a technique, whether it be surgical or non-surgical. Many process-centered outcomes in endodontics are evaluated based on how the post-operative radiograph 'looks' [6].

The first step of a root canal operation is usually to create a glide path using a manual K-file. Little, if any, tooth structure is removed because the idea is to follow the canal. For the safest operation and to avoid file fracture and fragmentation, first-generation NiTi files, even heat-treated files, needed straight line access. In order to make the coronal third larger and the file straighter as it entered the canal, the rotary file "brushed" along the canal wall. The next generation heat treatment method is used in NiTi files made for conservative endodontics to create flexible files that keep their sharpness. As a result, there is little dentin loss while the file may precisely mimic the structure of the canals. Tooth structure is kept and brushing is not required [7].

Conservative Endodontic Therapy

Conservative endodontics is a concept that supports preserving tooth structure wherever feasible by making only minor adjustments to conventional methods. According to conservative endodontic, every quantity of structure preserved is a net gain. As a result, both endodontists and general dentists can conduct conservative endodontics. The crucial component of conservative endodontics is a rotary file made specifically for the procedure. Sharp enough to function well while remaining adaptable enough to avoid separation danger. A microscope is unabashedly recommended [8].

A desirable dental goal is to practice conservative dentistry, which involves removing as

little good tooth material as possible throughout the restoration procedure. The finest dental materials now available are still natural enamel and natural dentin, therefore minimally intrusive treatments that preserve more of the original, sound tooth structure are preferred. Restorative dentistry has frequently been referred to and taught as "conservative dentistry" around the world. Traditional techniques and materials, on the other hand, have been aggressive and immensely intrusive, necessitating the evacuation of otherwise healthy enamel and dentin for a variety of reasons, such as lengthening a cavity to ensure the retention of the final restoration and lengthening a preparation to prevent recurrent decay [9].

Thankfully, modern dentistry has seen the development of novel materials, methods, and tools that make conservative dentistry and ultra-conservative dentistry a reality.

Complications after the Endodontic Therapy

The endodontist may encounter a variety of intra-operative complications while performing routine cases, including missed canals, unusually complex root canal anatomy and its variations, fractured equipment, undiagnosed non-healing periapical and resorptive lesions, incisions, root fissures, cortically fractured bones, the presence of apico- marginal communication, development of lesions into the maxillary sinus and thickening of the sinus membrane, and poor root canal obturation. It is also widely known that post-operative consequences might include lingering discomfort and edema in the soft tissue spaces around the treated tooth [10].

The density, contrast, and radiation geometry of radiographs showing the pre-treatment, post-treatment, and follow-up stages in endodontics must be uniform. The fourth dimension, time, is equally important. For a set of radiographs to be comparable throughout time, the aforementioned three parameters should be standardized. In some circumstances, poorly standardized radiographs might result in an incorrect assessment of the degree of healing. All of this is challenging to do with traditional planar imaging techniques, which is why new approaches have to be brought into dentistry [11].

This study targets to systematically review all the suitable articles available on the database related to the traditional radiology followed during the conservative therapy in endodontics.

AIM AND OBJECTIVE

The main objective of the systematic review of the traditional radiology used in the conservative therapy in Endodontics.

Specific Objectives

- ✓ To access the different endodontic conservative therapy utilizing conventional radiology.
- ✓ To evaluate the conventional radiology methods now in use for endodontics worldwide.
- ✓ To comprehend these traditional radiology procedures' advantages and disadvantages.

METHODOLOGY

All authors agreed on the method used in these investigations, which followed PRISMA criteria. Researchers searched the Cochrane Library database, SCOPUS database, and MEDLINE database to find publications that may be taken into consideration (via PubMed). To find the relevant publications, search terms including "conventional radiology," "conservative therapy," "endodontics," "endodontic therapy," and "endodontic treatment" were used.

Inclusion Criteria

To confirm that the studies satisfied the inclusion criteria, the reviewer independently obtained and read the full-text versions of the pertinent publications. The following were the inclusion requirements:

- ✓ Randomized controlled trials, prospective and retrospective research, and cross-sectional studies are investigations determining the conventional radiology employed in the conservative treatment of endodontics.
- ✓ Research studies in full text that established the radiological methods applied in endodontics.
- ✓ Both in-vitro and in-vivo research.
- ✓ Studies that are exclusively published in English.

Exclusion Criteria

The following were the exclusion requirements:

- × Articles of review, comments, abstracts, and summaries.
- × Research that covered radiology methods applied to various dental treatments.
- × Studies that were published in languages other than English to avoid translator bias.

Research Resources

Embase, Google Scholar, LILACS, MEDLINE utilizing the Ovid search engine, PubMed, Science Direct, Scopus, and Web of Science were among the electronic databases that underwent thorough individual searches. To find any more incomplete gray literature references that could have been overlooked, Ebsco was searched. The day of all searches was September 22, 2022. A manual search was conducted in addition to the computer search, and the reference lists of the chosen papers were scrutinized.

Statistical Analysis

In order to find any pertinent research, references for the textbook and a few papers were checked. The author participated independently in this study's procedure and gathered the essential data. The relevancy of each title and abstract to the study was recognized, scanned, and evaluated. The reviewer carefully examined full-text articles whenever the title and abstract's material left questions about the paper's relevancy.

RESULTS

The steps taken to retrieve and screen the studies used for this systematic review. 372 items in total were found after a preliminary search. Only 120 of the titles and abstracts were determined to be relevant. The other studies were disregarded because some of them had duplicate information, were irrelevant, or failed to meet the criteria for inclusion. After that, 22 research that were full-text papers were independently examined for eligibility. Finally, the review identified 8 papers that satisfied all the inclusion criteria.

Traditional Radiology in Endodontics

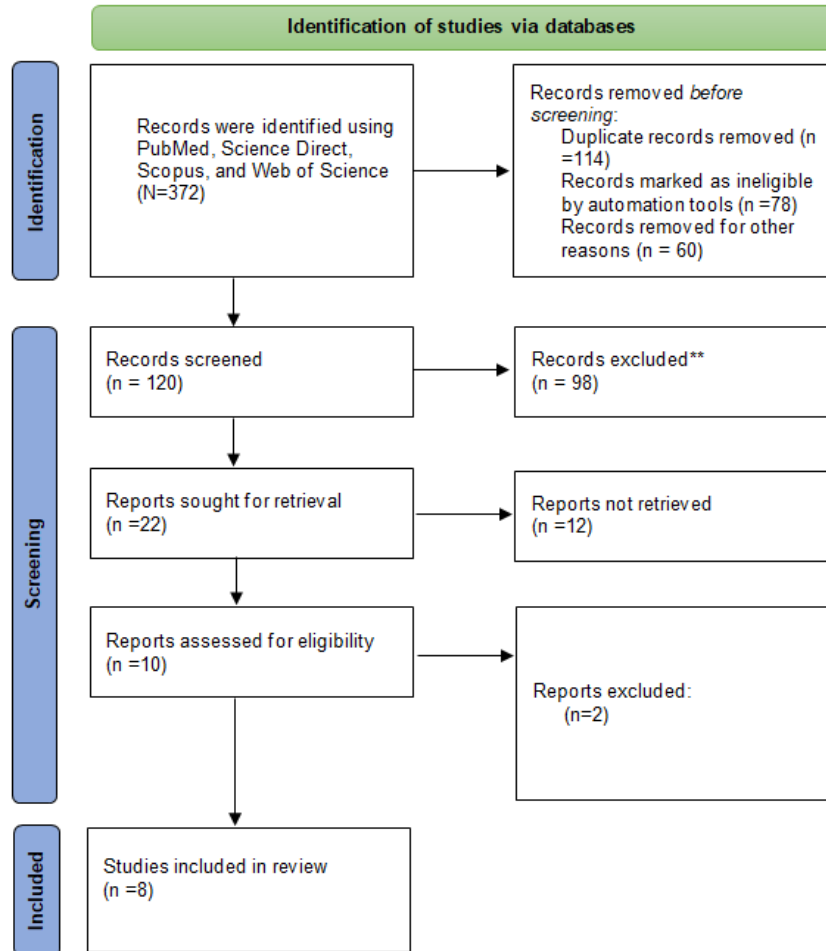
Endodontics must include radiography in their practice. Radiographs are used for diagnosis, therapy, follow-up, and prevention. Dr. Edmund Kells was the one who first identified endodontic working in 1895, shortly after Dr. Otto Walkhoff obtained the first dental radiograph of his teeth in 1899. In the year 1900, Dr. Weston Price proposed for first time that radiography is employed to assess the effectiveness of root canal fillings.

Periapical radiographs with the bisecting technique, which is particularly suitable for visualization of the apex; intraoral radiograph performed in the beta-wing or paralleling technique; partial extra-oral radiograph (rotational narrow beam); and panoramic radiography are the traditional radiographic assessments used in dental restorations and endodontics. In order to assess the extent of primary caries, detect secondary and interproximal beginning decays, and, if necessary, allow the therapist to estimate the biological width, radiology is a helpful diagnostic tool. Cervical burnout, the Mach band effect, internal and external resorption, restorative materials for fillings and sub-bases, and abrasions and/or erosions are some of the elements that affect how caries is interpreted on radiographs.

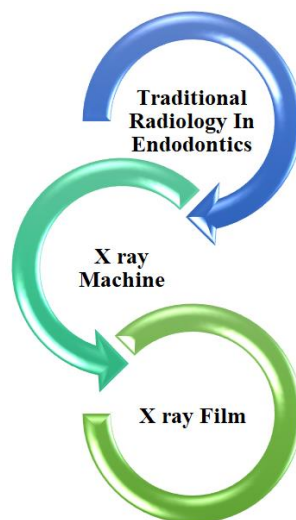
Radiology enables the detection of congenital and acquired dental anomalies, which may affect the course of therapy. When evaluating the outcomes of restorative dentistry, radiographs are crucial for identifying fractures, congruous contact sites, and precise margins. Additionally, it facilitates measurements during treatment, gives the endodontic treatments important diagnostic data, and supplies both short- and long-term assessments.

The most common type of radiographs utilized for endodontic therapy are periapical ones. Before beginning treatment, bitewing radiographs are frequently obtained to assess restorability or to look for coronal leakage and decay. After dental and facial injuries, occlusal and lateral cephalometric radiographs

are utilized to determine. Providing more views than periapical or lateral views, root or alveolar fractures 360-degree radiography. It is currently frequently used in place of some conventional imaging methods, such as occlusal radiographs, or in addition to periapical radiographs.



Flow Chart showing identification of studies via databases



In traditional dental radiology, images are captured using an image receptor, such as an X-ray film, and an X-ray equipment that produces X-rays.

X-Ray Device

The anode and cathode-containing X-ray tube, the power supply, and the timer make up the traditional X-ray machine. Bremsstrahlung and characteristic radiation are the main sources of X-ray production. The point at which the high energy electron collides to emit a photon is where they diverge. The tube current, tube voltage, exposure period, filtration, and collimation are the variables that regulate the X-ray beam. Coherent and Compton scattering and photoelectric absorption are two ways that X-rays interact with material.

X-Ray Film

Silver halide crystals and sulfur compounds make up the emulsion of X-ray film, which also includes a polyester polyethylene terephthalate base that is covered in an overcoat for protection. X-ray films come in a variety of sizes for usage in various contexts.

Periapical view films are available in three sizes, which may be selected based on the application. In order of increasing size, the other films are for occlusal view, panoramic view, and cephalometric view.

The intensifying screen, which provides an image receptor ten to sixty times more sensitive than the film alone, is a vital addition to the X-ray film in extra oral radiography. It is composed up of a protective coat, a polyester plastic substrate, and a phosphor layer. The sharpness of the picture may be changed, and the amount of dispersed radiation that leaves a subject and hits the film can be decreased by using grids consisting of alternating lead strips and radiolucent material [12, 13].

Validity of Radiographs

Image size and form distortion are elements that might impair an image's quality; they must be kept to a minimum to show the object's true size and shape. The method and angulation employed in dental radiology affect accuracy.

Table showing other radiology in Endodontics

OTHER RADIOLOGY IN ENDODONTICS	DETAILS
Cone-beam computed tomography (CBCT); Cone beam volumetric tomography (CBVT) [17]	In endodontics, CBCT has helped with the following: Diagnosis of periapical lesion caused by pulpal inflammation; Canal visualization; Canal elucidation; Detecting a root fracture. Patient convenience and painlessness Low radiation (much less than typical CT scan); Support the creation of the treatment strategy and technique; Assess the danger; Deeper analysis of the location and direction of nearby structures (including nerves, roots, and sinuses); Economical; Safe for individuals of all ages Inadequate contrast resolution, emission of radiation, and potential for streaking and motion artifacts
Micro Computed Tomography (MCT) [13]	The simplicity with which this technology may be used in endodontic investigations in particular enables identification of the morphology of the root canals, verification of preparation, assessment of fillings, and inspections following treatment. Both mineralized hard tissues and soft tissues and materials may be imaged with micro-CT. The fact that the measurements may be repeated and the utilized samples are not harmed is the main benefit. It offers extremely precise three-dimensional pictures of samples. In comparison to other techniques, Micro-CT scanning and reconstruction are expensive, time-consuming, and need computer skills. In addition, the use of micro-CT in therapeutic settings is prohibited by excessive radiation doses.
Radiovisiography (RVG) [8]	Using radiovisiography, carious lesions may be diagnosed, root lengths can be measured, and periapical pathology and root fractures can be found. lowering of the radiation dosage significantly; production of immediate pictures; Control of contrast; the ability to expand certain regions for use in locating instruments during endodontic treatment; the ability to save pictures in a computer and transmit them later Loss of resolution while printing screen images; Small sensor size; Thickness that is more than that of ordinary films.
Ultrasound (US) [14]	In dentistry, ultrasound is used to identify facial fractures, identify parotid lesions during fine needle aspiration cytology, and determine the nature of the lesions prior to surgery. However, owing of the thick cortical plate in the posterior portion of the mouth cavity, US is challenging to employ there. Ultrasound waves cannot readily pass through this area.

DISCUSSION

The most popular imaging technique for assessing root canals is unquestionably conventional

radiography (CR) since it is convenient, affordable, and available. Because it provides for improved picture quality and allows the dentist to do radiographic examinations with less radiation exposure, Digital

radiography (DR) has grown in favor as a substitute for CR [14].

The digital radiograph picture clearly outperforms the traditional film. A simpler photo preservation and communication system may be developed thanks to digitized images. Digital pictures can improve the circumstances of dental diagnosis, treatment planning, and follow-up because of the technical opportunities provided by digital software [15].

Numerous researches have been done to compare the quality of digital radiographs to their analog equivalents, but the outcomes of these investigations have been inconsistent. Digital pictures and traditional films were evaluated by Fuge *et al.*, for the clarity of the endodontic file in relation to the radiographic apex [15]. They discovered that when it came to establishing the end point of size 6 K-files in molar root canals, digital pictures performed worse than traditional radiography.

Our research, however, revealed that in terms of clarity and diagnostic quality, digitally scanned photos and traditional films are comparable. The employment of different scanning tools in the digitalization of radiographs may be the cause of this dispute. In the current investigation, the periapical conventional films were digitalized using the MD300 USB X-ray Reader; this reader can magnify the X-ray film by up to 50 times. Using this device, X-rays may be instantly transformed to digital pictures and sent through a USB cable to PCs. Any conventional dental X-ray film may be viewed by this device, and the contrast, brightness, and color can all be changed. Images may be sharpened, inverted, blurred, or artificially colored. The reader may also upload related information to a storage device [16].

Digital pictures' quality and diagnostic utility in contrast to traditional intraoral radiographs were examined by Malleshi *et al.*, [17]. They showed that digitized photos produced greater image clarity and diagnostic quality; however the current study did not support their conclusions. The usage of various software programs that allow digitally scanned images to be changed in brightness and contrast may be the cause of this inconsistency.

There are several observations of the advantages of Computed Tomography in the literature, especially in endodontics. The location and identification of broken tools, non-healing root canals requiring retreatment, root resorption, root fractures, comprehension of canal shape, trauma, detection of periapical lesions, and the amount of extruded root canal material are all endodontic applications. The technique has gained widespread acceptance and is being utilized in both clinical and research settings [18].

Patients with endodontic issues can be extremely difficult to diagnose and arrange treatment for. When a patient may experience symptoms without exhibiting any further radiographic periapical illness, the precise issue is sometimes difficult to determine. For the reasons mentioned above, it is crucial to accurately identify the issue and make plans in accordance with it. Two-dimensional radiographs have a number of drawbacks, including the superimposition of three-dimensional anatomy and potential exposure or geometry mistakes [19].

All stages of endodontic therapy, including diagnosis, treatment, and postoperative assessment or follow-up, need the use of radiographs. The primary intraoral radiographs used in endodontics are periapical radiographs, which have been used in root canal therapy for more than ten years. The pictures, which are typical film-based radiographs, must be created by chemically processing the films after they have been subjected to an X-ray radiation source. However, to address several issues with traditional radiographs, digital radiography has been adopted as clinical dentistry has advanced.

Radiographic digitization and scanning can be done in a number of ways, such as through video capture, a digital camera, a hard scanner, or a flatbed scanner. Dental X-ray films have recently been converted into digital pictures using a specialized scanner called a dental X-ray film reader. Through a universal serial bus (USB) cable, these scanned pictures may be sent from the film reader to a personal computer.

Using the MD300 USB X-ray Reader to digitize traditional dental radiographs led to pictures that were just as clear and diagnostic as traditional radiographs. The MD300 USB X-ray Reader appears to be a suitable instrument for digitizing traditional films in light of these findings. To optimize the advantages of X-ray digitization, more research on the instruments for enhancing scanning X-ray systems is necessary.

CONCLUSION

Tooth x-rays, often known as traditional radiographs, are used to detect cavities, bone loss, and hidden dental structures. Radiography is a technique used to get information about an object's internal structure in both clinical and non-invasive settings. The diagnostic usefulness of radiographs is crucial for root canal therapy. This method is also used to detect fractures, resorptive flaws, and procedural mistakes. Radiographic examinations are crucial because they reveal information about the treatment's complexity. Additionally, it appears that transitioning from film to digital imaging saves time.

ETHICAL CONSIDERATION**Ethical Approval**

This is systematic review of the systematically review the studies that reported about the traditional radiology used in the conservative therapy in Endodontics.

Conflict of Interest

The writers have no business ties that may put the information given in this communication in jeopardy or establish one. No part of this work was sponsored by internal or external funding.

REFERENCES

1. Santos-Junior, A. O., Pinto, L. D. C., Mateo-Castillo, J. F., & Pinheiro, C. R. (2019). Success or failure of endodontic treatments: A retrospective study. *Journal of conservative dentistry: JCD*, 22(2), 129-132.
2. Levine, M. (1988). Root-canal therapy: a means of treating oral pain and infection. *Canadian Family Physician*, 34, 1357-1365. PMID: 21253195; PMCID: PMC2219109.
3. Tabassum, S., & Khan, F. R. (2016). Failure of endodontic treatment: The usual suspects. *European journal of dentistry*, 10(01), 144-147. doi: 10.4103/1305-7456.175682. PMID: 27011754; PMCID: PMC4784145.
4. Ashley, M., & Harris, I. (2001). The assessment of the endodontically treated tooth. *Dental update*, 28(5), 247-252. Stavropoulou, A. F., & Koidis, P. T. (2007). A systematic review of single crowns on endodontically treated teeth. *Journal of dentistry*, 35(10), 761-767.
5. de Chevigny, C., Dao, T. T., Basrani, B. R., Marquis, V., Farzaneh, M., Abitbol, S., & Friedman, S. (2008). Treatment outcome in endodontics: the Toronto study—phase 4: initial treatment. *Journal of endodontics*, 34(3), 258-263.
6. Mohamed, A., & Steier, L. (2017). Uncertain Decision-Making in Primary Root Canal Treatment. *Journal of Evidence Based Dental Practice*, 17(3), 205-215.
7. Whites, E. (2007). Fperiapical radiography.in essentials of dental radiology and radiography. 4th ed Elsevier.
8. Ilić, D., & Stojanović, L. (2012). Application of radiovisiography (digital radiology) in dental clinical practice. *Vojnosanitetski pregled*, 69(1), 81-84. PMID: 22397301.
9. Setzer, F. C., & Lee, S. M. (2021). Radiology in Endodontics. *Dental Clinics*, 65(3), 475-486. doi: 10.1016/j.cden.2021.02.004. Epub 2021 May 3. PMID: 34051926.
10. Goldman, M., Pearson, A. H., & Darzenta, N. (1972). Endodontic success—who's reading the radiograph?. *Oral Surgery, Oral Medicine, Oral Pathology*, 33(3), 432-437.
11. Nair, M. K., & Nair, U. P. (2007). Digital and advanced imaging in endodontics: a review. *Journal of endodontics*, 33(1), 1-6.
12. Aggarwal, V., Logani, A., & Shah, N. (2008). The Evaluation of computed tomography scans and ultrasounds in the differential diagnosis of periapical lesion. *J Endod*, 34, 1312-1315.
13. Nielsen, R. B., Alyassin, A. M., Peters, D. D., Carnes, D. L., & Lancaster, J. (1995). Microcomputed tomography: an advanced system for detailed endodontic research. *Journal of endodontics*, 21(11), 561-568.
14. Rajendran, N., & Sundaresan, B. (2007). Efficacy of ultrasound and color power Doppler as a monitoring tool in the healing of endodontic periapical lesions. *Journal of endodontics*, 33(2), 181-186.
15. Sullivan Jr, J. E., Di Fiore, P. M., & Koerber, A. (2000). Radiovisiography in the detection of periapical lesions. *Journal of endodontics*, 26(1), 32-35.
16. Ellingsen, M. A., Harrington, G. W., Hollender, L. G., & Odont, D. (1995). Radiovisiography versus conventional radiography for detection of small instruments in endodontic length determination. Part 1. In vitro evaluation. *Journal of Endodontics*, 21(6), 326-331.
17. Worthington, P., Rubenstein, J., & Hatcher, D. C. (2010). The role of cone-beam computed tomography in the planning and placement of implants. *The Journal of the American Dental Association*, 141, 19S-24S.
18. Hanzelka, T., Dusek, J., Ocasek, F., Kucera, J., Sedy, J., Benes, J., ... & Foltan, R. (2013). Movement of the patient and the cone beam computed tomography scanner: objectives and possible solutions. *Oral surgery, oral medicine, oral pathology and oral radiology*, 116(6), 769-773.
19. American dental association council on scientific affairs. (2012). The use of CBCT in dentistry. *The journal of the American dental association*, 143, 899-902.