

Periapical Surgery with Biodentine™ as a Root-End Filling Material

Chaima Bouhajja^{1*}, Mayada Jemâa², Hend Ouertani², Hela Ben Cheikh Ahmed³, Mohamed Bassem Khattech⁴

¹Resident, Department of Dental Medicine, Military Principal Hospital of Instruction, Tunis, Tunisia
Laboratory of Dento-Facial Clinical and Biological Approach (ABCDF) LR12ES10, Tunisia

²Associate Professor, Department of Dental Medicine, Military Principal Hospital of Instruction, Tunis, Tunisia
Faculty of Dental Medicine, University of Monastir, Avicenne Avenue, Monastir 5019, Tunisia

³General Dentist, Germany

Laboratory of oral Health and oro-facial Rehabilitation laboratory research (LR12ES11), Faculty of Dental Medicine, University of Monastir, Avicenne Avenue, Monastir 5019, Tunisia

⁴Professor, Department of Dental Medicine, Military Principal Hospital of Instruction, Tunis, Tunisia
Oral Diseases in the military UR17DN04, Tunisia

DOI: [10.36348/sjodr.2022.v07i11.003](https://doi.org/10.36348/sjodr.2022.v07i11.003)

| Received: 16.09.2022 | Accepted: 21.10.2022 | Published: 03.11.2022

*Corresponding author: Chaima Bouhajja

Resident, Department of Dental Medicine, Military Principal Hospital of Instruction, Tunis, Tunisia
Laboratory of Dento-Facial Clinical and Biological Approach (ABCDF) LR12ES10, Tunisia
Email: Chaima.bouhajja@gmail.com

Abstract

MTA[®] is considered as the biomaterial of choice because of its excellent characteristics. Biodentine™ has been introduced into periapical surgery and has proven its efficacy in sealing root-end cavities. Despite of the desirable properties of Biodentine™, there are limited published cases that described the use of Biodentine™ in periapical surgery.

Keywords: Periapical surgery, MTA[®], Biodentine™, root-end filling, case report.

Copyright © 2022 The Author(s): This is an open-access article distributed under the terms of the Creative Commons Attribution 4.0 International License (CC BY-NC 4.0) which permits unrestricted use, distribution, and reproduction in any medium for non-commercial use provided the original author and source are credited.

INTRODUCTION

The periapical surgery is widely used as the last resort to rescue an affected tooth [1].

The purpose of endodontic surgery is to remove all necrotic tissues from and around the apical lesion (the root, soft tissues and bone), to seal the root canal system and to regenerate the periodontium [1, 2].

The root-end filling material is used as a hermetic seal between the root canal space and the periapical tissues.

Various retrofilling materials were indicated for this purpose. Mineral Trioxide Aggregate MTA[®] is considered the preferred choice for root-end filling in periapical surgery due to its seal ability, biocompatibility and periodontium inductivity with high success rate [3].

However, a new tri-calcium silicate-based material (Biodentine™) has been recognized as a promising material in endodontic surgery [4].

The present case shows successful surgical management of a periapical lesion, and the Biodentine™ was used as a retrograde root-end filling material.

CASE PRESENTATION

A 46-year-old male patient reported to the service of Dental Medicine in the Military Hospital of Tunis. The patient complained of pain with recurrent episodes of swelling in the upper left molar area.

There was no significant medical history, but the patient reported an allergy to Penicillin.

The clinical examination revealed a fluctuant swelling in the apical region of the maxillary left first premolar #24 and the maxillary left second premolar #25. The teeth were tender to percussion and palpation. The patient presented negative responses to the thermal pulp tests in relation to #24, #25 and #26. The other posterior teeth had normal responses.

The radiographic observations showed previous endodontic treatment of tooth #25 and tooth #26 with inadequate root canal therapy. A homogeneous well-defined periapical radiolucent image of 2cm in diameter encompassing the apices of the #24 and #25 (Fig 1).

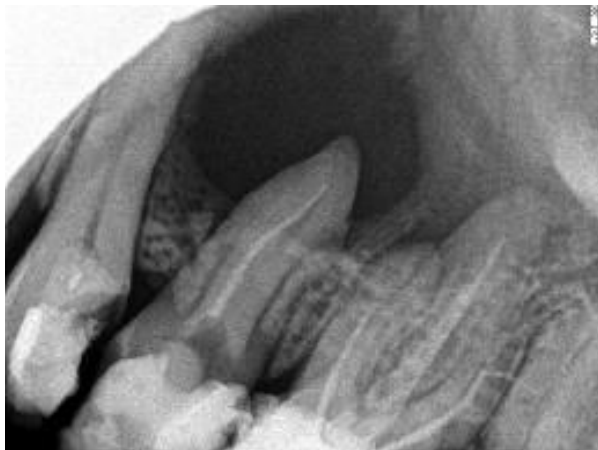


Fig. 1: Periapical radiograph showing well-defined radiolucent lesion involving apices of upper left first premolar #24 and upper left second premolar #25. It also revealed inadequate endodontic treatment in the upper left first molar and in the upper left second premolar

A preoperative Cone Beam Computed Tomography (CBCT) examination was indicated in order to assess the extent of the lesion and its exact relationships to dental roots and the maxillary sinus. It revealed significant bone destruction, with disruption of the vestibular and palatal cortical bones (Fig 2).

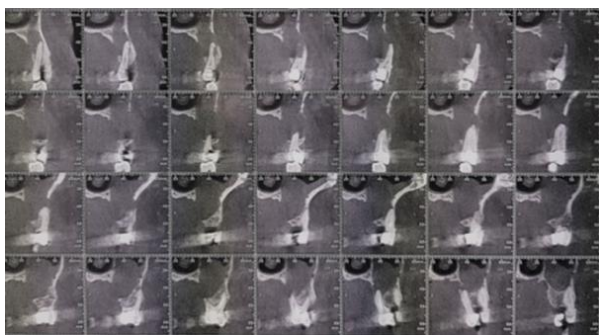


Fig. 2: Cone Beam Computed Tomography showed bone destruction at the apical region of #24 and #25 with vestibular and palatal cortical bone disruptions

The clinical and radiographic findings suggested periapical pathology extending from the upper left first premolar to the upper left second premolar regions. Thereafter, the treatment plan was endodontic treatment of #24, endodontic retreatment of #25 and #26, followed by endodontic surgery of the periapical lesion.

Between the appointments, a corono-radicular fracture of the #25 occurred leading to its extraction during the periapical surgery.

The surgical procedure, the risks and benefits were explained to the patient.

After extra and intra-oral antisepsis, the operating site was anesthetized with 2% mepivacaine with epinephrine. A sulcular incision from the region of mesial upper left canine to the region of distal upper left first molar was performed, and a mucoperiosteal flap was raised (Fig 3).

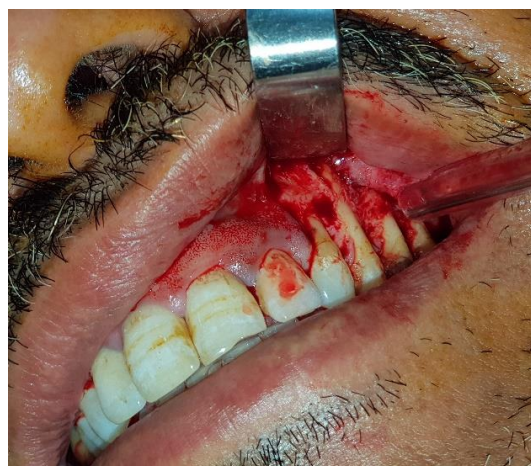

Fig. 3: Bony defect was observed during the periapical surgical procedure and cortical bone disruption was confirmed

The extraction of the upper left second premolar was done during the surgical procedure (Fig 4).

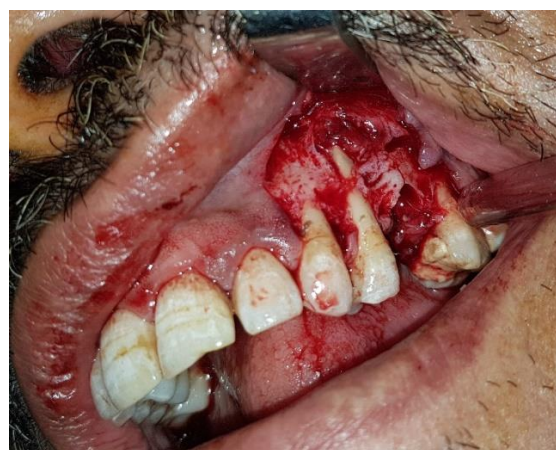

Fig. 4: Extraction of the tooth #25

A straight fissure carbide bur was used to enlarge the bony defect to a buccal window and the granulation tissue was removed with the aid of a curette. The surgical specimen was sent to the histopathology laboratory in the Hospital for histopathological examination (Fig 5).

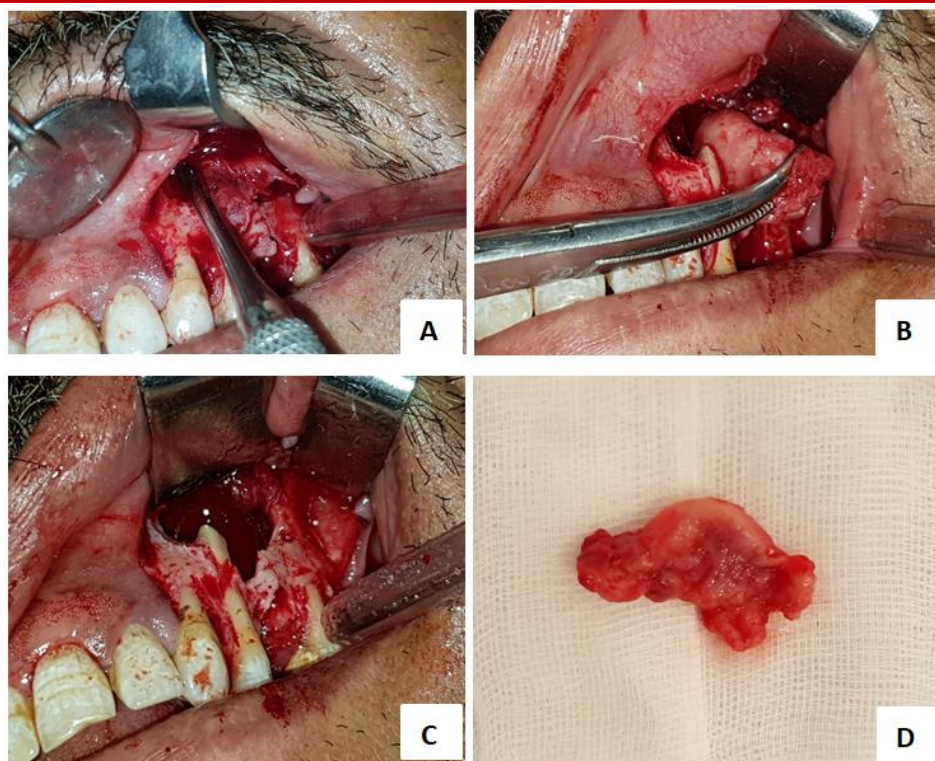


Fig. 5: (A, B, C) Enucleation of the periapical lesion; (D) The specimen

After lesion removal, the apicoectomy was performed with the aid of the Zekrya drill by cutting 3 mm length from vestibular and palatal apical root tips of the upper left first premolar. The resection was done at 90°, which means the bur was directed perpendicular to the long axis of each root. A saline irrigation was made to clean the cavity and to remove the necrotic debris, debris of gutta percha and root apex (Fig 6).

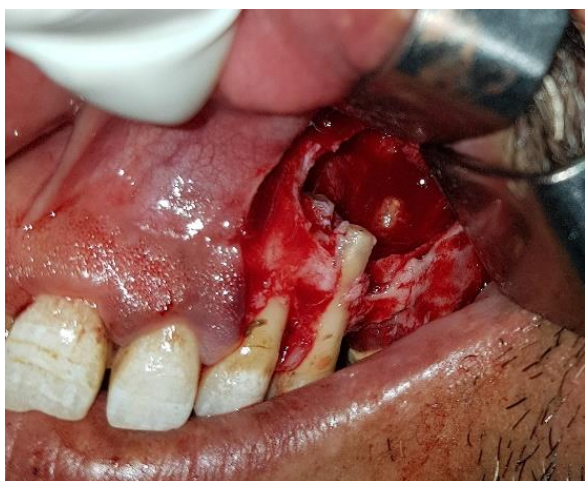

Fig. 6: Root-end resection

The root-end cavities were prepared to a depth of 3 mm with the aid of an ultrasound and using an angled ultrasonic tip, parallel to the canal and intense irrigation with saline solution was performed for cooling (Fig 7, 8).

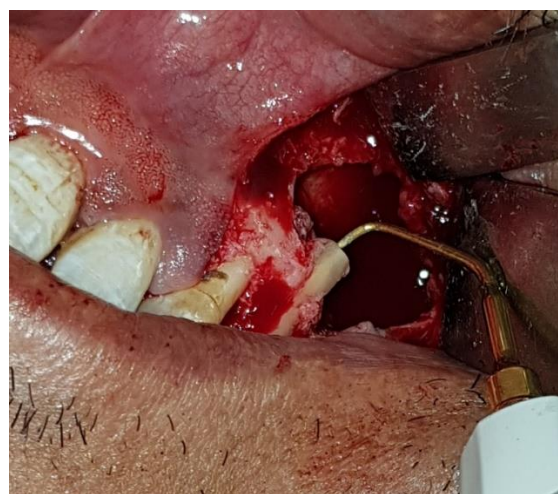

Fig. 7: 3mm root-end preparation with angled ultrasonic tip (Mectron ultrasonic insert)




Fig. 8: Mectron ultrasonic retro-preparation tips kit

After removal of gutta percha, the prepared root-end cavities were retro filled with Biodentine™ and the flap was repositioned and sutured (Fig 9).

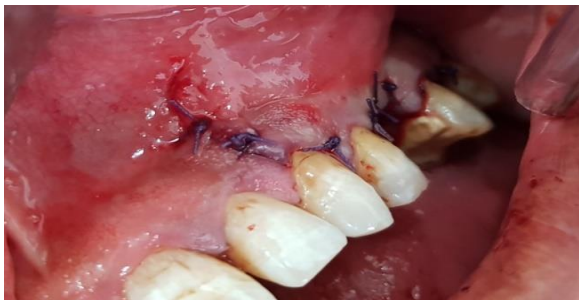

Fig. 9: The flap was repositioned and sutured

The patient received post-surgical care instructions and prescription of Birodogyl® 1.5MUI, Unidex® 4mg, Klipal® 300mg and 0.12% chlorhexidine digluconate rinses.

Histopathological examination confirmed the periapical cyst diagnosis.

The sutures were removed after a week and the patient had no complaint. A post-operative radiograph was taken (Fig 10).

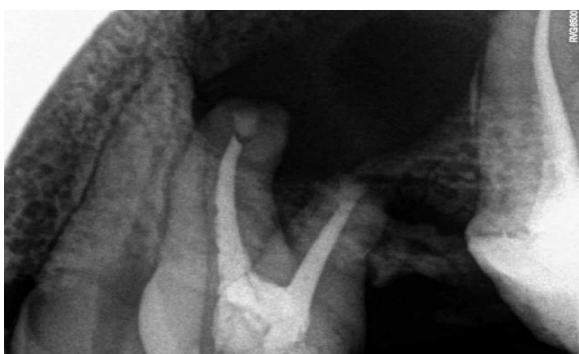

Fig. 10: Post-operative radiograph after one week

After 9 months follow-up, the radiograph revealed the beginning of bone formation. From a clinical point of view, the tooth was asymptomatic (Fig 11).

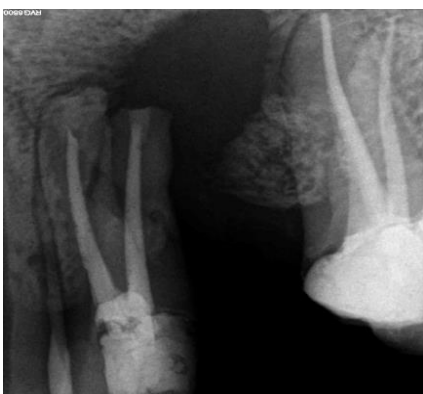

Fig. 11: Post-operative radiograph at 9 months follow-up

At 3 years postoperative, clinical and radiological examinations showed the absence of clinical symptomatology and complete reossification of the lesion site with absence of bone regeneration at the site of the extracted #25 (Fig 12).

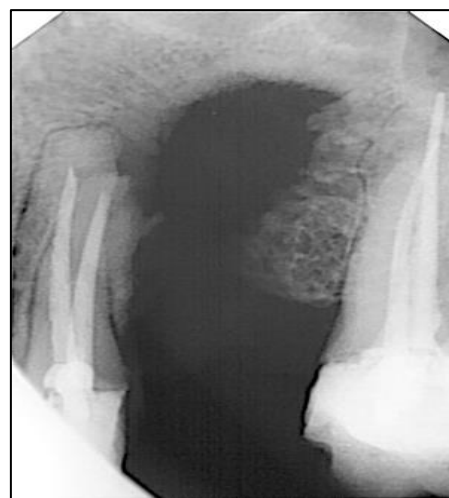

Fig. 12: Post-operative radiograph at 3 years follow-up showing a favorable healing lesion

DISCUSSION

The periapical surgery procedure requires multiple steps: flap reflection, osteotomy to expose the root apex, root-end resection, root-end preparation, root-end filling and flap closure. The introduction of new instruments and materials to endodontic surgery has improved its prognosis in recent years [2].

Intraoral radiographic images are the most used method to evaluate the size of periapical lesion before the periapical surgery [5].

Recently, Cone Beam Computerized Tomography CBCT provides three-dimensional images and it started to be introduced for the evaluation of periapical bone lesions, and their repair after surgical endodontic treatment [5].

In the present case, the radiograph revealed satisfactory bone regeneration after 3 years. Long-term follow-up of the clinical case is essential to evaluate the treatment outcome.

The apical resection provides an access to the canal system of the tooth to be treated. A root-end resection of 3 mm approximately has been performed in order to eliminate the apical area with the highest incidence of accessory canals [6].

The roots were resected perpendicular to the longitudinal axis of each root to reduce the number of exposed dentinal tubules [6].

Root-end preparations with the aid of an ultrasonic tip to a depth of 3 mm were performed

parallel to the long axis of each root and centered within each root canal [7].

Traditionally, periapical surgery was performed with the aid of surgical burs for root-end preparation [8]. Conventional rotary burs may be the cause of many errors as preparation outside the long axis of the tooth, missed isthmuses and require a bigger osteotomy. However, ultrasonic tips allow a more conservative osteotomy and provide a cleaner and deeper apical root-end preparation [7].

According to a recent meta-analysis, root-end cavity preparation with ultrasonics was significantly superior in achieving high clinical success rates comparing with traditional root-end cavity preparation with burs [8].

The root-end cavity was filled with Biodentine™ in order to seal the root canal system.

An efficient apical seal is essential for enhancing endodontic success and the choice of the material may influence the final outcome of the procedure [9, 10].

Numerous materials for root-end filling have been used in periapical surgery such as amalgam, intermediate restorative material (IRM), glass-ionomer cement and super ethoxy benzoic acid (super-EBA) [9]. All of these materials are compatible with tissue cicatrisation and reconstitution of peri-apical alveolar bone, but none of them is able to induce cementum formation and full periodontal ligament repair.

In 1993, mineral trioxide aggregate MTA, a calcium silicate-based biomaterial was introduced as a root-end filling material [8].

Nowadays, it is considered the gold standard thanks to its bioactive properties, its osseo-inductive and conductive power that favors tissue regeneration, its high sealing capacity, and its antimicrobial effect. Furthermore, it is easy to detect MTA on radiographs due to its radiopacity [10].

However, MTA has some drawbacks such as long setting time, low resistance to compression and flexion, expensiveness and difficult handling [9, 10].

Recently, many bioceramics have been developed in order to correct some of the disadvantages of MTA. These new biomaterials have mostly similar constituents to MTA [8].

Biodentine™ is a new tri-calcium silicate-based cement material that was introduced in 2009. Biodentine™ powder is mainly composed of tri-calcium silicate and calcium carbonate which are the main components of MTA. The liquid has an aqueous

solution of calcium chloride and an admixture of polycarboxylate [9].

Biodentine™ produces calcium hydroxide during the setting time. Hence, it has similar properties to those of MTA [9].

When used as a root-end filling material, Biodentine™ showed significantly better sealing capacity, in comparison to MTA and intermediate restorative material IRM [4].

According to a systemic review carried out in 2020, the sealing ability of Biodentine™ is greater than that of MTA during the first 24 hours, though both materials prove equal after one week [10].

As regards to mechanical characteristics, Biodentine™ presents physical improved properties compared to MTA in a clinical application [3].

Additionally, Biodentine™ has shown reduced time setting and easy handling but with poor radiopacity [3].

Its lack of radiopacity on radiographs limitates the visualization of the retrograde obturation [3].

The new tri-calcium silicate-based materials maintain the desirable properties of prior bioceramic materials and overcome their disadvantages [11].

MTA is widely used as a root-end filling material. The available literature on MTA is extensive [10].

Although few studies and cases have been published to describe the use of Biodentine™ in periapical surgery, it can be concluded that Biodentine™ is a good alternative to MTA in periapical surgery.

The introduction of new tools, instruments and materials increase the number of successful cases of endodontic surgery [7]. This new surgical approach is called “Endodontic microsurgery”.

Endodontic microsurgery integrates the use of operative microscope, or an endoscope that allows a high power magnification and illumination, root-end cavity preparation with ultrasonic tips, and more biocompatible root-end filling materials [11].

With the advancements in endodontic surgery, the success rate of modern endodontic surgery has been reported to be as high as 94% compared with a moderate success rate of approximately 60% with traditional root-end surgery techniques [12].

Recently, it has been shown that the probability of success for endodontic microsurgery was 1.58 times higher than that for traditional root-end surgery [12].

CONCLUSION

Regarding periapical lesions associated with endodontic pathology, the periapical surgery has proven its effectiveness in healing these lesions. The success of periapical surgery is strongly linked to how to seal root-end cavities and to prevent bacterial contamination of the root canal system. Biodentine™ was used as a root-end filling material in this clinical case. However, there are limited published cases that described the use of Biodentine™ for this purpose.

Author's Declaration

The authors declare that there is no conflict of interest regarding the publication of this article.

Written informed consent was obtained from the patient to publish this report in accordance with the journal's patient consent policy.

REFERENCES

1. Krastev, B., & Filipov, I. (2020). Periapical Surgery. Epidemiology, indications and contraindications. Review. *Journal of IMAB–Annual Proceeding Scientific Papers*, 26(2), 3114-3121. Doi: 10.5272/jimab.2020262.3114
2. Serrano-Giménez, M., Sánchez-Torres, A., & Gay-Escoda, C. (2015). Prognostic factors on periapical surgery: A systematic review. *Medicina oral, patología oral y cirugía bucal*, 20(6), e715-22. doi: 10.4317/medoral.20613. PMID: 26449431; PMCID: PMC4670252.
3. Caron, G., Azérad, J., Faure, M. O., Machtou, P., & Boucher, Y. (2014). Use of a new retrograde filling material (Biodentine) for endodontic surgery: two case reports. *International journal of oral science*, 6(4), 250-253. doi: 10.1038/ijos.2014.25. Epub 2014 May 9. PMID: 24810806; PMCID: PMC5153583.
4. Zafar, K., Jamal, S., & Ghafoor, R. (2020). Bio-active cements-Mineral Trioxide Aggregate based calcium silicate materials: a narrative review. *JPMA. The Journal of the Pakistan Medical Association*, 70(3), 497-504. doi: 10.5455/JPMA.16942. PMID: 32207434.
5. Jorge, É. G., Tanomaru-Filho, M., Guerreiro-Tanomaru, J. M., Reis, J. M. D. S. N., Spin-Neto, R., & Gonçalves, M. (2015). Periapical repair following endodontic surgery: two-and three-dimensional imaging evaluation methods. *Brazilian Dental Journal*, 26, 69-74. doi: 10.1590/0103-6440201300252. PMID: 25672388.
6. Kacarska, M. (2017). Clinical evaluation of root end resection bevel in periapical surgery. *prilozi*, 38(1), 113-118. doi: 10.1515/prilozi-2017-0015. PMID: 28593898.
7. Palma, P. J., Marques, J. A., Casau, M., Santos, A., Caramelo, F., Falacho, R. I., & Santos, J. M. (2020). Evaluation of root-end preparation with two different endodontic microsurgery ultrasonic tips. *Biomedicines*, 8(10), 383. doi: 10.3390/biomedicines8100383. PMID: 32998221; PMCID: PMC7601836.
8. Küçükkaya Eren, S., & Parashos, P. (2019). Adaptation of mineral trioxide aggregate to dentine walls compared with other root-end filling materials: A systematic review. *Australian Endodontic Journal*, 45(1), 111-121. doi: 10.1111/aej.12259. Epub 2018 Feb 16. PMID: 29450937.
9. Nabeel, M., Tawfik, H. M., Abu-Seida, A. M., & Elgendy, A. A. (2019). Sealing ability of Biodentine versus ProRoot mineral trioxide aggregate as root-end filling materials. *The Saudi dental journal*, 31(1), 16-22. doi: 10.1016/j.sdentj.2018.08.001. Epub 2018 Sep 12. PMID: 30723363; PMCID: PMC6349993.
10. Paños-Crespo, A., Sánchez-Torres, A., & Gay-Escoda, C. (2021). Retrograde filling material in periapical surgery: a systematic review. *Medicina oral, patología oral y cirugía bucal*, 26(4), e422-62. doi: 10.4317/medoral.24262. Epub ahead of print. PMID: 33340080.
11. Pinto, D., Marques, A., Pereira, J. F., Palma, P. J., & Santos, J. M. (2020). Long-term prognosis of endodontic microsurgery—a systematic review and meta-analysis. *Medicina*, 56(9), 447. doi: 10.3390/medicina56090447. PMID: 32899437; PMCID: PMC7558840.
12. Shinbori, N., Grama, A. M., Patel, Y., Woodmansey, K., & He, J. (2015). Clinical outcome of endodontic microsurgery that uses EndoSequence BC root repair material as the root-end filling material. *Journal of Endodontics*, 41(5), 607-612. doi: 10.1016/j.joen.2014.12.028. Epub 2015 Feb 18. PMID: 25702859.