

Maxillary Alveolar Bone Dimensional Changes of Post – Extraction Sockets in Humans

Dr. Mohammad Naffizuddin M.D.S^{1*}, Dr. Bharani Krishna.T M.D.S², Dr. D. Lokanathan Balaji M.D.S³, Dr. Ch.Ram Sunil M.D.S⁴, Dr. V.Sujana M.D.S⁵, Dr. K.Madhu Kiran Naik M.D.S⁶, Dr. V.Shivakumar M.D.S⁷

¹Assistant Professor Department of Oral & Maxillofacial Surgery, Dr.N.T.R. University of Health Sciences Vijayawada, Andhra Pradesh, India

²Assistant Professor Department of Oral Medicine and Radiology, Dr.N.T.R. University of Health Sciences Vijayawada, Andhra Pradesh, India

³Assistant Professor Department of Prosthodontics, Dr.N.T.R. University of Health Sciences Vijayawada, Andhra Pradesh, India

⁴Professor Department of Conservative Dentistry and Endodontics, Dr.N.T.R. University of Health Sciences Vijayawada, Andhra Pradesh, India

⁵Professor Department of Conservative Dentistry and Endodontics, Dr.N.T.R. University of Health Sciences Vijayawada, Andhra Pradesh, India

⁶Assistant Professor Department of Conservative Dentistry and Endodontics, Dr.N.T.R. University of Health Sciences Vijayawada, Andhra Pradesh, India

⁷Professor and HOD Department of Periodontics, Dr.N.T.R. University of Health Sciences Vijayawada, Andhra Pradesh, India

DOI: [10.36348/sjodr.2021.v06i06.004](https://doi.org/10.36348/sjodr.2021.v06i06.004)

| Received: 24.04.2021 | Accepted: 03.06.2021 | Published: 11.06.2021

*Corresponding author: Dr. Mohammad Naffizuddin M.D.S

Abstract

Dentistry has remarkable advancements in dental restorative materials, techniques and strategies that are remarkable in many ways. Scientifically proven approaches have proved that implants were esthetically and functionally excellent options for tooth replacement. Restoration of dental implant is considered to be a highly evolved procedure for oral health care considering reserved specialists and requires training beyond the regular dental school curriculum. Considering these important facts, a thorough knowledge of maxillary sinus anatomy in the edentulous patient is very much required for placement of successful maxillary sinus implants and the changes occurring in it periodically due course with no replacement. Treatment planning is very crucial considering the events occurring in dimensional changes in the maxillary sinus for successful implant placements and prognosis. The current study focuses on physical and physiological events occurring in the maxillary sinus due to a lack of prosthesis.

Keywords: Maxillary Alveolar Bone Dimensional Extraction Sockets.

Copyright © 2021 The Author(s): This is an open-access article distributed under the terms of the Creative Commons Attribution 4.0 International License (CC BY-NC 4.0) which permits unrestricted use, distribution, and reproduction in any medium for non-commercial use provided the original author and source are credited.

INTRODUCTION

Sinus pneumatization was identified after extraction of posterior maxillary teeth. The expansion of the sinus was larger following extraction of teeth enveloped by a superiorly curving sinus floor, extraction of several adjacent posterior teeth, and extraction of second molars. If dental implant placement is planned in these cases, immediate implantation and/or immediate bone grafting should be considered to assist in preserving the 3- dimensional bony architecture of the sinus floor at the extraction site [1-4].

Tooth extraction is one of the most common dental procedures. Generally, the extraction socket heals uneventfully. However, even with uneventful healing, the alveolar defect that results as a consequence of tooth removal will only become partially restored. Concurrent with bone growth into the socket, there is also well-documented resorption of the

alveolar ridges. The greatest amount of bone loss is in the horizontal dimension and occurs mainly on the facial aspect of the ridge. There is also a loss of vertical ridge height, which has been described to be most pronounced on the buccal aspect. This resorption process results in a narrower and shorter ridge, and the effect of this resorptive pattern is the relocation of the ridge to a more palatal/lingual position. The defect resulting from the loss of a tooth may be complicated by previous bone loss due to periodontal disease, endodontic lesions, or a traumatic episode.

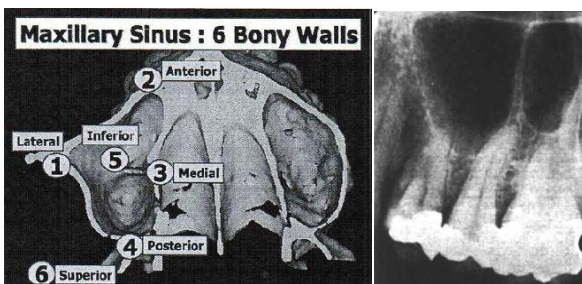
The size of the residual ridge is reduced most rapidly in the first six months, but bone resorption activity in the residual ridge continues throughout life at a slower rate resulting in the removal of large amounts of the jaw structure [8]. Initial stability of the implant is one of the fundamental criteria for obtaining Osseointegration. Sufficient density and the appropriate

volume of bone are therefore crucial factors for successful implant treatment [5-9].

Socket Grafting in the Posterior Maxilla Reduces the Need for Sinus Augmentation. Implanted material increases the probability of maintaining the alveolar ridge volume following tooth extraction and confirms the space-maintaining activity of an implanted material covered by a collagen membrane. This improvement in maintaining the vertical dimension in the posterior maxillary area decreases the demand for a sinus augmentation procedure [10].

Bony septa

The most widely studied internal structure of the sinus is the septum (Underwood septa). They may divide the back part of the sinus into multiple compartments known as posterior recesses. The presence of a septum has been related to the incidence of membrane perforations. Membrane perforations may lead to a higher incidence of postoperative complications.



Bony septa of maxillary sinus

Antral septa are bony projections most commonly arising from the floor of the maxillary sinus. They have been found more commonly in the edentulous than dentate maxilla because of the presence of secondary septa. It was hypothesized that after tooth loss, selective bony resorption of the sinus floor resulted in areas of protrusion and depression. The protrusive bony spikes form secondary septa, in comparison to the primary septa, are formed along with the development of the maxillary sinus.

This theory is further supported by the fact that primary septa are taller and may split a sinus into two compartments, whereas secondary septa are considerably shorter [11].

Classification of edentulous posterior maxilla

Specifically, the edentulous posterior maxilla poses a number of challenges that can complicate implant treatment planning. Cawood and Howell, in their classification of edentulous jaws, reported that the posterior maxilla loses its shape upon tooth loss. This bone loss in combination with sinus pneumatization often resulted in deficient vertical height, creating a major challenge for future implant-supported restorations.

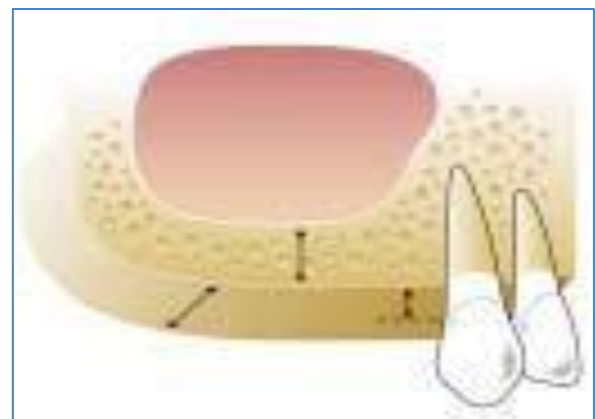
Misch developed a classification for treatment of the edentulous posterior maxilla based on the amount of bone below the antrum and the ridge width. Treatment categories ranged from SA-1 to SA-4 based on bone height and division A (> 5 mm) or B (2.5 to 5 mm) based on ridge width. Recently, Simion *et al.* developed a classification of the maxillary posterior edentulous region that took into consideration the bone crest as it relates to the cemento-enamel junction (CEJ) of the adjacent teeth. Together, these classifications provide complete guidelines for rehabilitation of the edentulous posterior maxilla, but independently, they are incomplete [16].

ABC classification

Hom-Lay Wang and Amar Katranji in 2008 have proposed a new classification system. The ABC classification is based on the assumption that the implants will be of minimum specifications: 4 mm in diameter and 10 mm in length.

Class A: Abundant bone

Class A indicates that the sinus floor is located at least 10 mm from the crest, with a width of 5 mm or greater. The distance from the bone crest to the adjacent CEJ is 3 mm or less. In this clinical scenario, implants can be placed without further grafting.



Sinus Class A

Class B: Barely sufficient bone

In this classification, the sinus floor is located 6 to 9 mm from the crest of the bone. The width is at least 5 mm and does not require further horizontal augmentation. The bone crest is 3 mm or less from the adjacent CEJ. In this scenario, the sinus can be augmented using either osteotome or lateral wall (window) procedures, and the implant may be placed simultaneously. Class B may have component defects that require grafting prior to, during, or after sinus elevation and implant placement. Class B situations can be subclassified into one of three divisions.

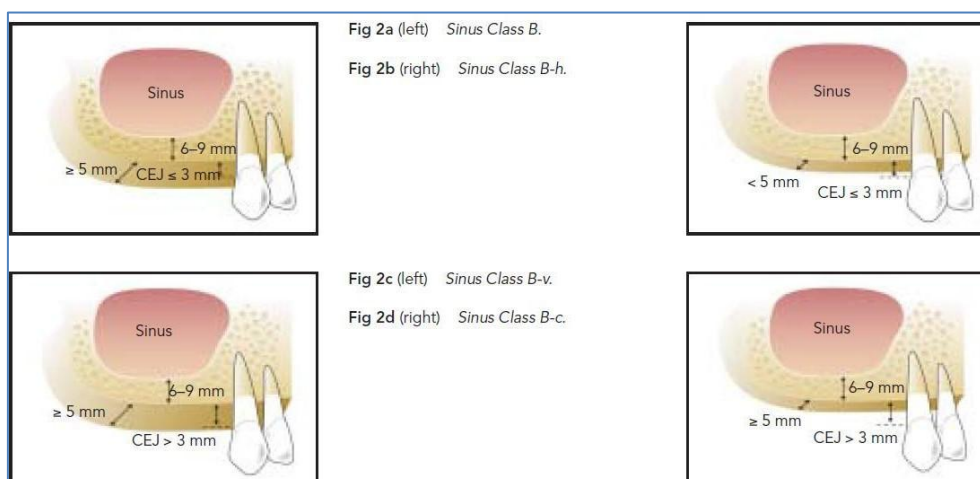1. Division h (horizontal defect): The sinus floor is 6 to 9 mm from the crest of the bone, and the width is less than 5 mm and requires horizontal

augmentation such as guided bone regeneration (GBR) to achieve proper width. The bone crest is 3 mm or less from the adjacent CEJ. In this scenario, the width should be augmented (e.g., GBR, on lay graft, or ridge split/expansion) to at least 5 mm so that the Class B protocol can be followed.

2. Division v (vertical defect): The sinus floor is 6 to 9 mm from the crest of the bone with normal bone width (≥ 5 mm). The bone crest is more than 3 mm from the adjacent CEJ and requires vertical augmentation. In this scenario, the bone crest is elevated through grafting procedures to maintain a

proper crown-to-implant ratio. Following augmentation, implants can be placed using the Class B protocol.

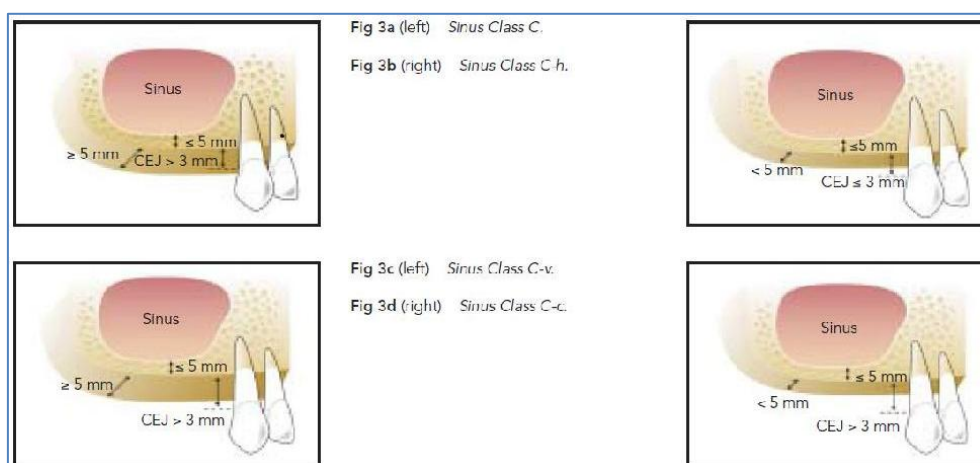3. Division c (combined defect): The sinus floor is 6 to 9 mm from the crest of the bone, the width is less than 5 mm, and the bone crest is greater than 3 mm from the adjacent CEJ. In this scenario, a combined vertical and horizontal component requires grafting procedures. Following augmentation, implants can be placed using the Class B protocol.



Class C: Compromised bone

In Class C situations, the bone crest is 5 mm or less from the sinus floor, the bone width is 5 mm or more, and the bone crest is 3 mm or less from the

adjacent CEJ. A lateral wall sinus augmentation is often recommended for a more predictable outcome. If implant stability is achieved, then immediate implants may be placed in a two-stage.



If implant stability cannot be achieved, a sinus graft should be allowed to heal for at least six months. Implants are placed after the healing period. Class C situations can be subclassified into one of three divisions.

1. Division-h (horizontal): The sinus floor is 5 mm or less from the crest of bone, and the width is less than 5 mm. The bone crest is 3 mm or less apical to the adjacent CEJ. The lateral window sinus augmentation procedure is often recommended, and implants are placed after sinus grafting. Horizontal augmentation is performed as indicated.

2. Division v (vertical defect): The sinus floor is 5 mm or less from the alveolar bone crest with normal bone width (≥ 5 mm). The bone crest is more than 3 mm from the adjacent CEJ. The bone crest is elevated via grafting procedures to maintain a proper crown-to-implant ratio. Following augmentation, implants can be placed using the Class B protocol. Nonetheless, the patient should be informed that an unfavourable crown to implant ratio may exist after the definitive restoration is placed.
3. Division-c (combined): The sinus floor is 5 mm or less from the crest of bone, and the width is less than 5 mm. The bone crest is more than 3 mm apical to the adjacent CEJ. The lateral window sinus augmentation procedure is performed. Horizontal and vertical bone augmentation is required for proper implant placement and restoration. Implants are placed after successful sinus and bone grafting [16].

Class	Recommended procedure(s)	Immediate/delayed
A	Implant placement	Immediate
B	Osteotome	Immediate
B-h	Osteotome and ridge expansion	Immediate
	GBR/onlay graft	Delayed
B-v	GBR followed by osteotome	Delayed
B-c	GBR and/or onlay graft followed by osteotome	Delayed
C	Lateral wall sinus elevation	Immediate with implant stability Delayed without implant stability
C-h	Lateral wall sinus elevation and GBR/onlay graft	Delayed
C-v	Lateral wall sinus elevation and GBR, followed by onlay graft if indicated	Delayed
C-c	Lateral wall sinus elevation and GBR, followed by onlay graft if indicated	Delayed

GBR = Guided bone regeneration.

Abc classification and recommended treatment options (Hom –Lay Wang et al.).

CONCLUSION

Maxillary sinus augmentation is the scope for the near future in implant dentistry; thorough knowledge in sinus anatomy and applied physiology is very much required for placement of successful implants and a good prognosis for every clinician. Implant exposure to the sinus mucosa can cause thickening and result in maxillary sinusitis and discomfort to the patient. Changes occurring in the sinus due to edentulism must be perceived and kept in mind for a good prognosis of the implant.

REFERENCES

1. Woo, I., & Le, B. T. (2004). Maxillary sinus floor elevation: review of anatomy and two techniques. *Implant dentistry*, 13(1), 28-32.
2. Tiwana, P. S., Kushner, G. M., & Haug, R. H. (2006). Maxillary sinus augmentation. *Dental Clinics*, 50(3), 409-424.
3. Van Den Bergh, J. P., Ten Bruggenkate, C. M., Disch, F. J., & Tuinzing, D. B. (2000). Anatomical aspects of sinus floor elevations. *Clinical Oral Implants Research: Treatment rationale*, 11(3), 256-265.
4. Sharan, A., & Madjar, D. (2008). Maxillary sinus pneumatization following extractions: a radiographic study. *International Journal of Oral & Maxillofacial Implants*, 23(1).
5. McGowan, D. A., Baxter, P. W., & James, J. A. (1993). The maxillary sinus and its dental implications (No. 18). *John Wright*.
6. May, M., Sobol, S. M., & Korzec, K. (1990). The location of the maxillary os and its importance to the endoscopic sinus surgeon. *The Laryngoscope*, 100(10), 1037-1042.
7. Chanavaz, M. (1990). Maxillary sinus: anatomy, physiology, surgery, and bone grafting related to implantology--eleven years of surgical experience (1979-1990). *The Journal of oral implantology*, 16(3), 199-209.
8. Van der Weijden, F., Dell'Acqua, F., & Slot, D. E. (2009). Alveolar bone dimensional changes of post- extraction sockets in humans: a systematic review. *Journal of clinical periodontology*, 36(12), 1048-1058.
9. Santagata, M., Guariniello, L., Rauso, R., & Tartaro, G. (2010). Immediate loading of dental implant after sinus floor elevation with osteotome technique: a clinical report and preliminary radiographic results. *Journal of oral implantology*, 36(6), 485-489.
10. Rasperini, G., Canullo, L., Dellavia, C., Pellegrini, G., & Simion, M. (2010). Socket grafting in the posterior maxilla reduces the need for sinus augmentation. *International Journal of Periodontics & Restorative Dentistry*, 30(3).
11. Wen, S. C., Chan, H. L., & Wang, H. L. (2013). Classification and management of antral septa for maxillary sinus augmentation. *International Journal of Periodontics & Restorative Dentistry*, 33(4).
12. Pommer, B., Ulm, C., Lorenzoni, M., Palmer, R., Watzek, G., & Zechner, W. (2012). Prevalence, location and morphology of maxillary sinus septa: systematic review and meta- analysis. *Journal of clinical periodontology*, 39(8), 769-773.
13. Beretta, M., Cicciu, M., Bramanti, E., & Maiorana,

- C. (2012). Schneider membrane elevation in presence of sinus septa: anatomic features and surgical management. *International journal of dentistry*, 2012.
14. Krennmair, G., Ulm, C., & Lugmayr, H. (1997). Maxillary sinus septa: incidence, morphology and clinical implications. *Journal of Cranio-Maxillofacial Surgery*, 25(5), 261-265.
15. Topozada, H. H., & Talaat, M. A. (1980). The normal human maxillary sinus mucosa: an electron microscopic study. *Acta oto-laryngologica*, 89(3-6), 204-213.
16. Wang, H. L., & Katranji, A. (2008). ABC sinus augmentation classification. *International Journal of Periodontics & Restorative Dentistry*, 28(4).