

Lingual Orthodontic Treatment of Adults: A Case Report

Inès Medhioub^{1*}, Hatem Hammouda¹, Nour Ben Belgacem¹, Rihab Zairi¹, Takwa Mamlouk¹, Anissa El Yemni Zinelabidine²

¹Resident, Dento-Facial Orthopedics Department of Farhat Hached Hospital, Sousse, Laboratory of Oral Health and Orofacial Rehabilitation, Tunisia

²Head of Dento-Facial Orthopedics Department of Farhat Hached Hospital, Sousse, Dento-Facial Orthopedics Department of Farhat Hached Hospital, Sousse, Laboratory of Oral Health and Orofacial Rehabilitation, Tunisia

DOI: <https://doi.org/10.36348/sjodr.2025.v10i01.009>

Received: 17.12.2024 | Accepted: 22.01.2025 | Published: 24.01.2025

*Corresponding author: Inès Medhioub

Resident, Dento-Facial Orthopedics Department of Farhat Hached Hospital, Sousse, Laboratory of Oral Health and Orofacial Rehabilitation, Tunisia

Abstract

Adult patients seeking orthodontic treatment consistently have aesthetic concerns, even throughout the course of the treatment. This has led to the introduction of Lingual Orthodontics in 1970s by Dr. Craven Kurz of USA and Dr. Kinya Fujita of Japan. Lingual orthodontics, in addition to its aesthetic benefits, offers several other advantages. The cooperation and confidence level of the patient has increased with the invisible appliances. The Anchorage control, indirect bonding and biomechanics is completely different from labial technique. In this article the concept of lingual orthodontics has been highlighted. The article shows a case report with lingual technique treated in the department of orthodontics at Farhat Hached University Hospital.

Keywords: Lingual orthodontic, Adult treatment, Invisible appliance.

Copyright © 2025 The Author(s). This is an open-access article distributed under the terms of the Creative Commons Attribution 4.0 International License (CC BY-NC 4.0) which permits unrestricted use, distribution, and reproduction in any medium for non-commercial use provided the original author and source are credited.

INTRODUCTION

Lingual orthodontics is a specialized approach to orthodontic treatment that uses brackets and wires placed on the lingual surfaces of the teeth, providing a fully discreet and aesthetic solution for patients seeking orthodontic correction without visible appliances. Introduced in the 1970s by pioneers like Kurz and Fujita, lingual orthodontics has evolved significantly, incorporating advanced materials and techniques that allow for more precise and comfortable treatment. Modern lingual systems, such as the customized Incognito and prefabricated In-Ovation L, offer a range of options tailored to the needs of the patients, from mild crowding to complex malocclusions.

The primary advantage of lingual orthodontics is its invisibility, which makes it particularly appealing to adults and those concerned with the aesthetic impact of traditional braces. However, the technique requires a high level of skill, both in bracket placement and wire adjustments, due to the difficulty in accessing the lingual surfaces. Additionally, lingual appliances may pose challenges in terms of patient comfort, speech, and oral hygiene, especially during the initial stages of treatment.

Despite these challenges, lingual orthodontics offers several benefits, including reduced visibility, fewer aesthetic compromises, and the ability to treat a wide range of malocclusions, from mild crowding to more complex skeletal discrepancies. Furthermore, the integration of digital technologies in bracket design and customization has significantly enhanced the precision and predictability of lingual treatments.

This article reviews the principles of lingual orthodontics, discusses its clinical applications, and explores the advancements that have shaped this treatment modality. It also examines patient outcomes, highlighting both the advantages and limitations of lingual appliances in achieving functional and aesthetic goals in orthodontic treatment [1].

Advantages of Lingual Braces:

- ❖ **Aesthetic Appeal:** Lingual braces are placed on the inner surface of the teeth, making them nearly invisible from the outside. This is ideal for patients who want to straighten their teeth without the visible appearance of traditional braces.

- ❖ **Discreet Treatment:** Since lingual braces are hidden behind the teeth, they are a popular option for adults and professionals who may feel self-conscious about wearing traditional braces.
- ❖ **Effective for All Ages:** Lingual braces can be used to treat both adults and children, making them suitable for a wide range of orthodontic cases [2].

Disadvantages of Lingual Braces

- ❖ The cost difference is significant; lingual braces are 3 to 4 times more expensive than vestibular treatments.
- ❖ The discomfort associated with this treatment is more pronounced compared to vestibular braces, as it may interfere with the natural movement of the tongue.
- ❖ Risk of tongue injury.
- ❖ Very delicate positioning of the brackets in direct bonding technique [2].

Indications for Lingual Braces

Lingual orthodontics offers the same potential for controlling dental movements as vestibular

orthodontics. This technique is suitable for treating minor dental misalignments, complex cases requiring the extraction of permanent teeth, and orthognathic (surgical orthodontics) cases.

Clinical Observation

The patient is a 22-year-old woman who consulted the orthodontic unit at CHU Farhat Hached Sousse for aesthetic reasons (maxillary and mandibular crowding).

The extraoral frontal examination shows parallelism between the ophryal, bipupillary, and bicommissural lines, with an increased lower facial height.

The extraoral lateral examination reveals a convex profile with a frontally aligned forehead, a straight nasal ridge, a normal nasolabial angle, and a cervicomental distance of four of the patient's fingers (Figure 1).



Figure 1: Pre-treatment extra-oral photographs

The intraoral examination reveals U-shaped arches, with a Class I molar and canine relationship on both the right and left sides, along with anterior crowding

in both the upper and lower arches. There is also a deviation of the lower midline towards the left side (Figure 2).

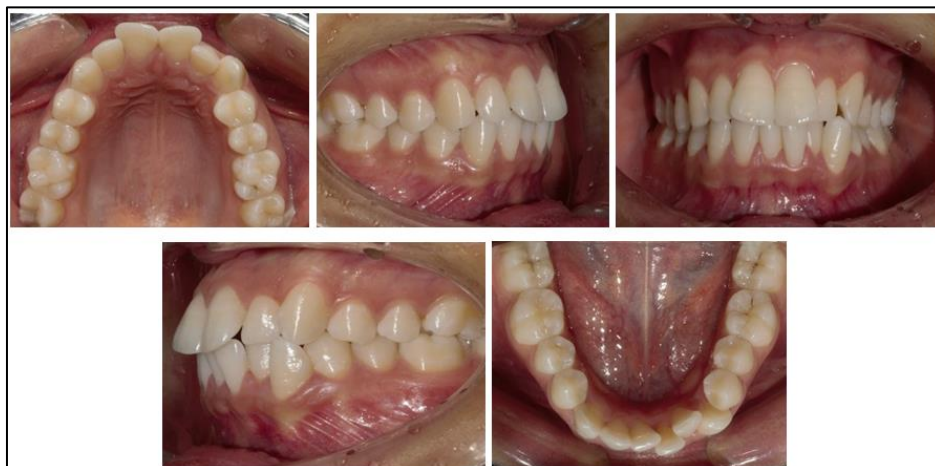

Figure 2: Pre-treatment endo-oral photographs

The radiological assessment includes:

Cephalometric analysis (Table 1) and tracing showed class 1 skeletal relationship ($ANB= 1^\circ$, $AoBo=-$

1mm), proclination of the upper and lower incisor ($I/F=118^\circ$, $IMPA = 105^\circ$), and short facial height ($FMA=19^\circ$).

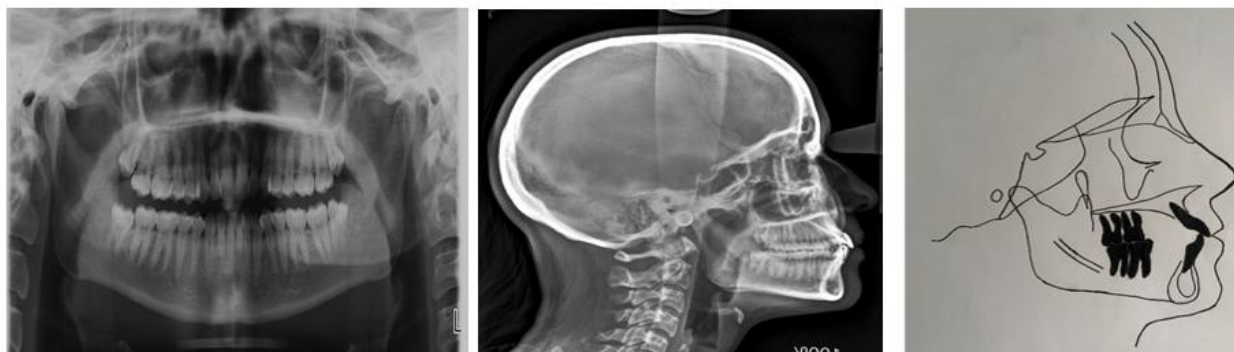

Figure 3: Pre-treatment radiographs

Table 1: The angular and linear values obtained from the Tweed analysis

<i>SNA</i>	79°
<i>SNB</i>	78°
<i>ANB</i>	1°
<i>Ao Bo</i>	-1mm
<i>FMA</i>	19°
<i>FMIA</i>	56°
<i>IMPA</i>	105°
<i>I/i</i>	117°
<i>I/F</i>	118°
<i>Z</i>	75°

Table 2: The angular and linear values obtained from the Steiner analysis

	+	-
Enc		8
RI		8
C Spee		2
DDM		18
Exo	16	
NET		2

Diagnosis

The patient presents with a skeletal Class I malocclusion combined with facial hypodivergence. On the dentoalveolar level, she has a Class I molar and canine relationship with proclined upper and lower incisors.

Treatment Objectives:

- Resolution of dental crowding.
- To maintain class I canine and molar relationships.
- Establishment of a functional overjet and overbite.
- Correction of the arch form.

- To achieve optimal facial esthetics

Therapeutic Decision

A non-extraction orthodontic treatment with lingual appliance was our treatment of choice. Before starting orthodontic treatment, the patient was referred to a periodontist for probing, evaluation and initial therapy including motivation to oral hygiene and supragingival plaque control.

Then, orthodontic treatment using the 2D system (Innovation L brackets from GAC) was initiated with direct bonding technique.

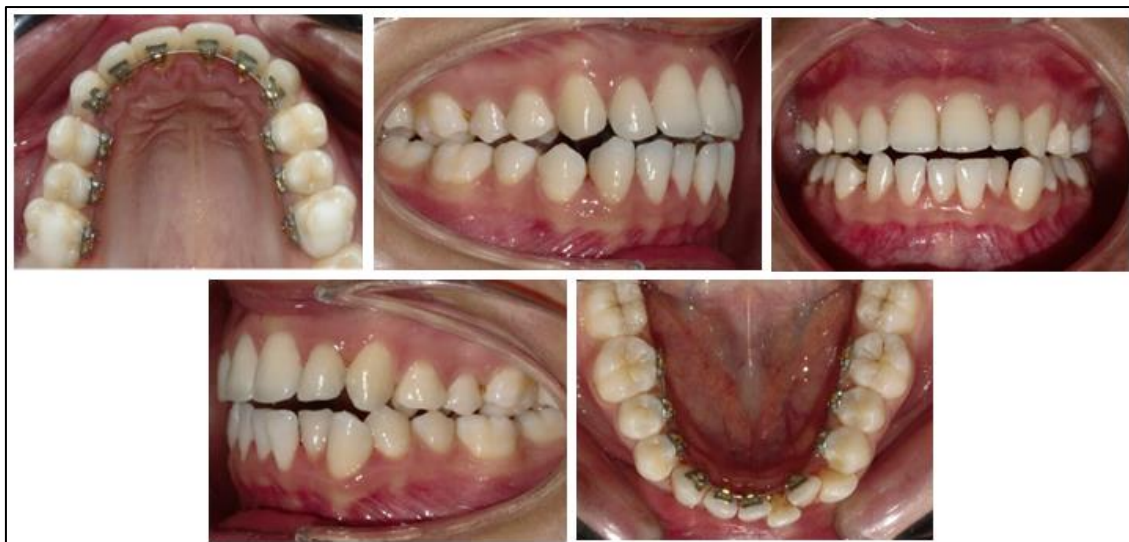

Figure 4: Direct Bonding Technique

Bracket Bonding (Figure 4)

- Here's an overview of the direct bonding process for lingual orthodontic treatment:

1. Preparation

- Oral hygiene: The patient's teeth are thoroughly cleaned, and any plaque or tartar is removed to ensure proper bonding.
- Isolation: The teeth are isolated using cotton rolls or cheek retractors to keep the treatment area dry, which is essential for successful bonding.

2. Etching

- The lingual surfaces of the teeth are etched with a phosphoric acid gel to create micropores for better adhesion of the bracket.

3. Bonding

- A bonding resin is applied to the etched surfaces of the teeth.

- The orthodontist then places the brackets directly on the lingual surfaces of the teeth, ensuring proper positioning according to the treatment plan.

The upper and Lower arches were bonded and 0.012 NITI wire was inserted for initial leveling.

Then, a NITI 0.014, 0.016, 0.018 was used.

The overall active treatment time was 16 months.

After debonding of the lingual appliance, fixed retainers were placed in both arches to maintain Long-term stability (Figure 8).

Therapeutic stages:

After 6 months of treatment, the space was opened for the 31 using a compressed spring.

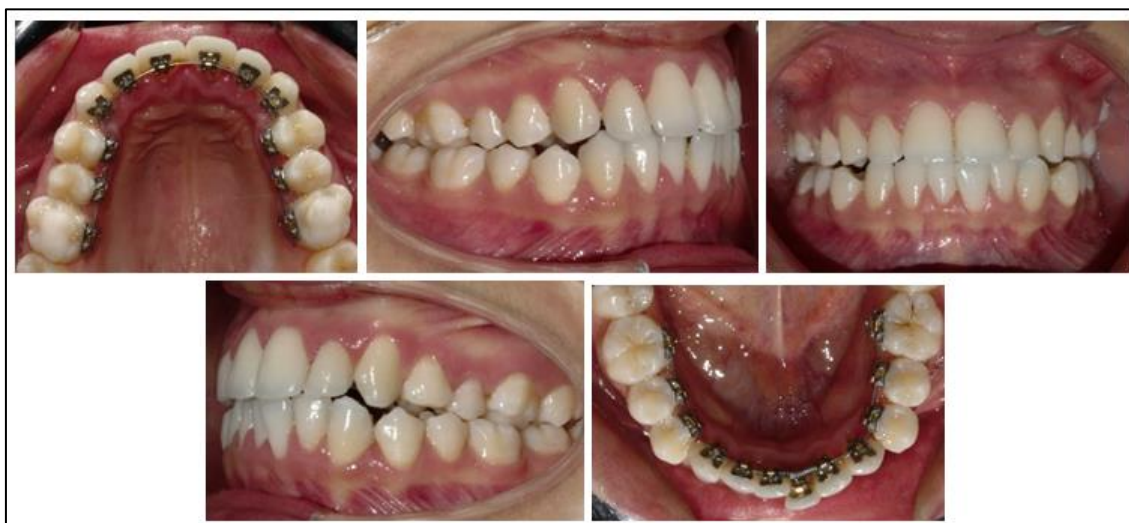

Figure 5: Space opening for the 31 using a compressed spring

After 12 months, the 31 was placed, and maxillary and mandibular leveling was achieved.

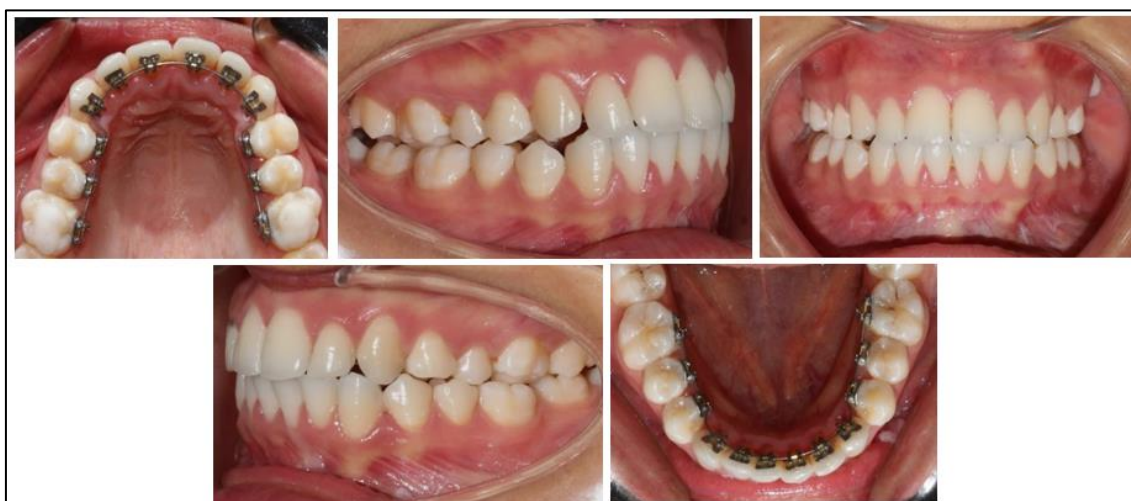

Figure 6: Correction of crowding in both the upper and lower arches

The final extraoral photographs show the restoration of facial aesthetics. The patient's smile and profile are now more harmonious (Figure 7).




Figure 7: Post-treatment extra-oral photographs

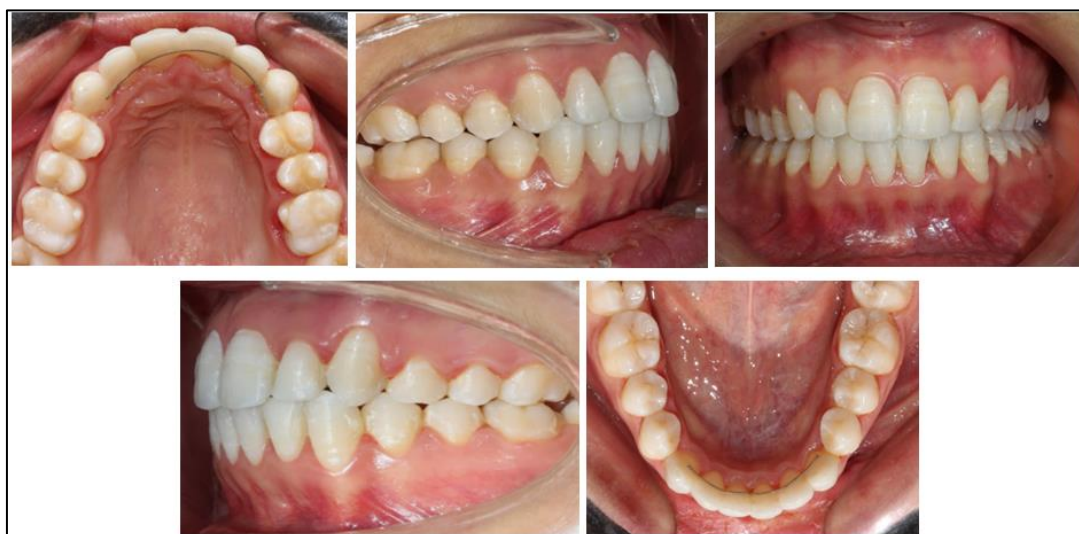

Figure 8: Post-treatment endo-oral photographs

Final Radiographic Assessment

The panoramic radiograph shows no evidence of root proximity.

The cephalometric analysis, along with both local and general superimpositions, reveals a slight lower alveolar protrusion compared to the start of treatment (Figure 9 & 10).

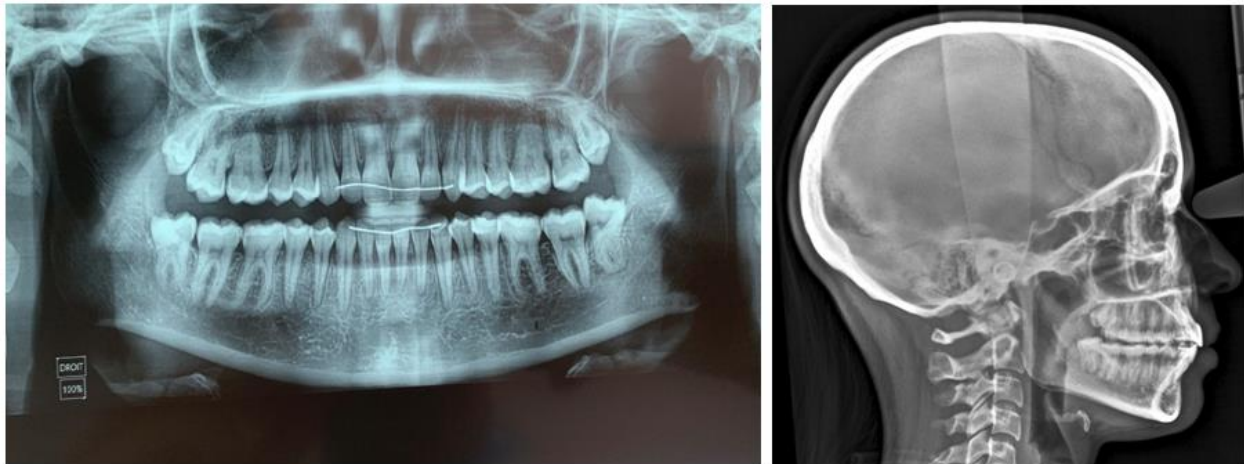

Figure 9: Post-treatment radiographs

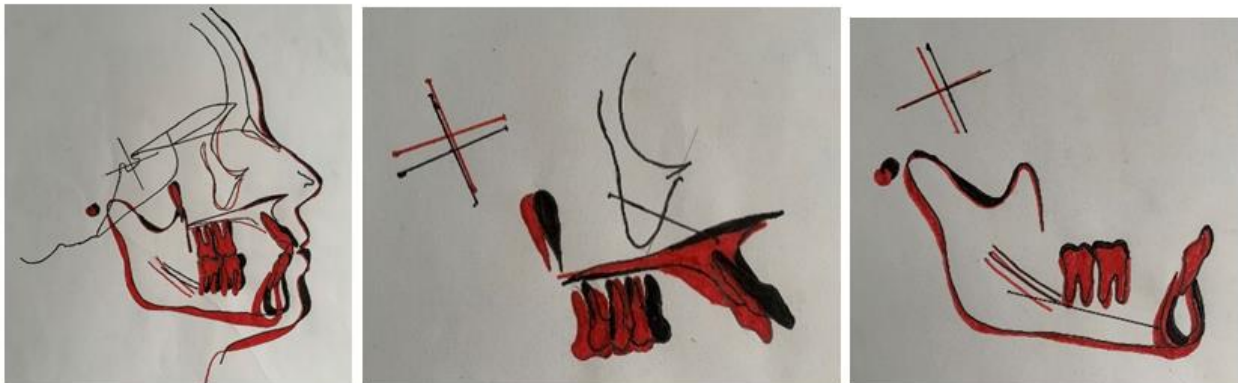


Figure 10: Cephalometric superimposition

DISCUSSION

In recent years, the growing number of adult patients seeking orthodontic treatment and their higher aesthetic expectations have led to the development of various cosmetic treatment approaches, including aesthetic brackets (Innovation C by GAC, Damon Clear, etc.) and clear aligners (Invisalign, Smilers, etc.). While these reduce the visual presence of the appliance, they remain visible, which is still a concern for some patients [1].

In this regard, lingual orthodontics represents the ideal solution due to its complete discretion. Since the introduction of lingual appliances by FUJITA, advancements have been made in their design and fabrication. The benefits of lingual appliances offered by clinicians or manufacturers include reduced visibility, fewer carious lesions and white spots, lighter forces due to a smaller inter-bracket distance, less anchorage loss, and increased comfort [2, 4].

There are several systems available on the market, including customized options such as the Liberty, Incognito, and Win systems, which are now considered benchmarks in the field of new-generation technologies, with proven efficacy in adult lingual orthodontics [7, 8].

There are also prefabricated systems, such as the In-Ovation L by GAC, which is the system we used to treat our patient.

In-Ovation L is a two-dimensional self-ligating lingual system that does not take into account the third order. It features a true bi-plot design with an optimal mesio-distal distance, offering enhanced control of rotation, and a spring-loaded interactive clip that can function in a passive, interactive, or active role, allowing for optimal control of the arch engagement throughout all treatment phases.

The In-Ovation L system is typically used for patients with interdental diastemas or mild dental

crowding, which was the case for our patient, who presented with a skeletal Class I, a Class I molar and canine relationship on both sides, anterior maxillary and mandibular crowding, and proclined upper and lower incisors [9].

The patient sought orthodontic treatment but refused visible braces, so we proposed fixed orthodontic treatment using the lingual technique with the In-Ovation L system by GAC [1, 5].

After bonding, stripping was performed and a bite block was placed to prevent bracket detachment during closure movements. Then, prefabricated "mushroom" archwires were inserted.

In lingual orthodontics, direct bonding and indirect bonding refer to two different methods of attaching the brackets to the teeth. Both methods are effective, but they each have distinct advantages and challenges. Below is a comparison of direct bonding vs. indirect bonding in lingual orthodontics.

Direct Bonding in Lingual Orthodontics Process:

- Direct bonding involves the orthodontist attaching the brackets directly to the teeth during the appointment. This method requires the orthodontist to individually place each bracket on the inner surface of the tooth and bond it using dental adhesive.

Indirect Bonding in Lingual Orthodontics Process:

- Indirect bonding involves a multi-step process where an impression or digital scan of the patient's teeth is taken first. From this, a model of the teeth is created in a lab. The brackets are then bonded to the model of the teeth, and a custom transfer tray is fabricated. This tray is used to transfer the bonded brackets onto the patient's teeth in a second appointment.

Table 3: Comparison: Direct vs. Indirect Bonding

Feature	Direct Bonding	Indirect Bonding
Bracket Placement	Brackets are placed directly on the teeth.	Brackets are placed on a model before transfer.
Time in Chair	Longer due to individual bracket placement.	Shorter due to pre-bonding on a model and tray.
Precision	Dependent on orthodontist's skill, prone to errors.	Greater precision since brackets are pre-positioned.
Comfort	Potentially uncomfortable due to prolonged mouth opening.	More comfortable for the patient with fewer individual steps.
Laboratory Involvement	Low, as no model or transfer tray is required.	High, requiring custom models and transfer trays.
Cost	Generally lower due to less lab involvement.	Higher, due to lab fees and the multi-step process.
Patient Follow-up	None needed for bracket placement; focus on adjustments.	Requires extra time for the fabrication of models and trays.
Flexibility	More adaptable during the procedure.	Less flexibility once brackets are placed on the model.

Which is Better?

- Direct Bonding may be more appropriate for patients with simpler orthodontic needs, where the orthodontist can place the brackets quickly and effectively, or when cost is a concern. It is also beneficial for cases where time is of the essence, and the orthodontist can directly modify the bracket placement on the spot.
- Indirect Bonding is generally preferred for more complex cases or when precise, customized bracket placement is necessary. It is particularly useful for patients with more severe malocclusion or those who need very accurate bracket positioning to achieve optimal results. This method also minimizes patient discomfort during the bracket bonding phase [3].

CONCLUSION

The choice between direct bonding and indirect bonding in lingual orthodontics largely depends on the complexity of the case, the desired level of precision, patient comfort, time constraints, and budget. Both methods are effective, but indirect bonding tends to be the go-to choice for more precise, efficient, and comfortable treatment in more complex cases.

RÉFÉRENCES

1. Singh, P., & Cox, S. (2011). Lingual orthodontics: an overview. *Dental update*, 38(6), 390-395.
2. Ata-Ali, F., Ata-Ali, J., Ferrer-Molina, M., Cobo, T., De Carlos, F., & Cobo, J. (2016). Adverse effects of lingual and buccal orthodontic techniques: A systematic review and meta-analysis. *American Journal of Orthodontics and Dentofacial Orthopedics*, 149(6), 820-829.

3. Patano, A., Inchingolo, A. D., Malcangi, G., Garibaldi, M., De Leonardi, N., Campanelli, M., ... & Inchingolo, A. M. (2023). Direct and indirect bonding techniques in orthodontics: a systematic review. *European Review for Medical & Pharmacological Sciences*, 27(17), 8039-8054. doi: 10.26355/eurev_202309_33565. PMID: 37750633.
4. Papageorgiou, S. N., Gözl, L., Jäger, A., Eliades, T., & Bourauel, C. (2016). Lingual vs. labial fixed orthodontic appliances: systematic review and meta-analysis of treatment effects. *European journal of oral sciences*, 124(2), 105-118.
5. Sorel, O., Mehdi, S., & Mano, M. C. Procédure de collage indirect, Faculté de Chirurgie Dentaire, 2 avenue du Professeur Léon Bernard (Bât. 15), 35043 Rennes Cedex, France.
6. Tsolakis, I. A., Gizani, S., Tsolakis, A. I., & Panayi, N. (2022). Three-dimensional-printed customized orthodontic and pedodontic appliances: a critical review of a new era for treatment. *Children*, 9(8), 1107. PMID: 35892610 PMCID: PMC9332207 doi: 10.3390/children9081107
7. Wiechmann, D., Rummel, V., Thalheim, A., Simon, J. S., & Wiechmann, L. (2003). Customized brackets and archwires for lingual orthodontic treatment. *American journal of orthodontics and dentofacial orthopedics*, 124(5), 593-599.
8. Fujita, K. (1979). New orthodontic treatment with lingual bracket mushroom arch wire appliance. *American journal of orthodontics*, 76(6), 657-675.
9. Fillion, D., & JF, L. (1991). L'orthodontie linguale: pourquoi est-elle en progrès. *Orthod*, 62(Pt 3), 793-801.