

Panoramic Radiography in Evaluating the Pattern of Impacted Third Molars

Priyanka Mahajan¹, Rajwinder Kaur Malhi², Karanprakash Singh³, Chitra Anandani⁴, Saurab Bither⁵, Amritpal Singh⁶

¹Intern, Luxmi Bai Institute of Dental Sciences & Hospital, Patiala, India

²Intern, Luxmi Bai Institute of Dental Sciences & Hospital, Patiala, India

³Reader, Department of Public Health dentistry, Luxmi Bai Institute of Dental Sciences & Hospital, Patiala, India

⁴Senior Lecturer, Department of Oral Pathology & Microbiology, Luxmi Bai Institute of Dental Sciences & Hospital, Patiala, India

⁵Professor, Department of Oral Surgery, Luxmi Bai Institute of Dental Sciences & Hospital, Patiala, India

⁶Lecturer, Department of Oral Surgery, Luxmi Bai Institute of Dental Sciences & Hospital, Patiala, India

Original Research Article

***Corresponding author**
Priyanka Mahajan

Article History

Received: 14.02.2018

Accepted: 23.02.2018

Published: 28.02.2018

DOI:

10.21276/sjodr.2018.3.2.5



Abstract: The aim of this study was to determine the prevalence of impacted third molars in terms of frequency, angulation, level of eruption and available retromolar space. In this retrospective study, a total of 402 OPGs were finalized. Pattern of impacted third molars was evaluated using WINTERS classification for the angulation and PELL & GREGORY classification for the level of eruption and available retromolar space. Among all the OPGs reviewed, third molar impaction was more prevalent in mandible than in maxilla. The most common angular position was mesioangular in mandible and vertical in maxilla. The most common level of eruption was Position B i.e. the highest position of impacted third molar was located below the occlusal plane but above the cervical line of adjacent second molar. Majority of third molars were impacted at less than adequate space. The current study revealed that the most frequent pattern of impaction according to PELL & GREGORY classification was Class 2B followed by Class 1C.

Keywords: Angulation, Impaction, Mandibular third molar, Radiographic evaluation.

INTRODUCTION

Development of alveolar process and face depend upon sequential eruption of teeth. Tooth eruption is a process that co-ordinates alveolar bone resorption and deposition responsible for development of maxillary and mandibular alveolar process. After the complete formation of enamel epithelium, active tooth eruption is initiated by formation of eruption pathway mediated by osteoclasts which are regulated by dental follicle and further, tooth is moved through eruption pathway by deposition of bone apical to crown. Complications in the eruption pathway may occur at any point resulting clinically in impacted, unerupted or embedded teeth [1].

An unerupted tooth is that which is in the process of eruption and is likely to erupt based on clinical and radiographic findings. A tooth is considered to be impacted when it is completely or partially unerupted positioned against a physical barrier such as another tooth, bone or soft tissue so that its further eruption is unlikely even beyond its normal chronological age of eruption.

In modern era the diet pattern of humans have changed to softer and more refined in nature thus reducing the efficacy of masticatory apparatus. This is probably one of the main factors responsible for smaller jaw size that fails to accommodate all the teeth. Genetic melting is also contributing in the prevalence of impaction [2].

In human dentition, the most commonly impacted tooth in the oral cavity is the third molar since they are the last one in the sequence of eruption [3]. Thus, the functional requirement and need for third molar has become minimal. It has been noted that third molar crypt formation begins at the age of 3-4 yrs and calcification starts at the age of 7-10 yrs. However, the time of eruption varies from 14-24 yrs in different population [4,5].

During normal development, the lower third molar begins its development in a horizontal angulation and as the tooth develops and the jaws grows, the angle changes from horizontal to mesioangular and followed by vertical. Failure of rotation from mesioangular to vertical direction results in impaction of third molar.

Tooth also becomes impacted because of arch length deficiency, dense overlying bone or soft tissue, ectopic position of tooth germ, prolonged retention of deciduous teeth, supernumerary teeth, cleft lip and palate, odontogenic cyst or tumor as these cause obstruction in the eruption pathway. Researchers had also found that ankylosis of the primary or permanent teeth associated with trauma, rickets, anemia, tuberculosis, malnutrition, cleidocranial dysostosis, Down syndrome and osteopetrosis are also the contributing factors for the impaction of tooth [6].

Occasionally, impacted teeth may remain asymptomatic throughout a person's life but majority of these teeth become involved in various pathologic processes which include dental caries, pericoronitis, cyst or tumor formation, development of neoplastic lesions and also cause root resorption of adjacent teeth [3]. The literature had also mentioned that impacted mandibular third molars weakens the angle region of mandible and make it more susceptible to fracture and later results in lower arch crowding [7,8].

According to PREVENTIVE DENTISTRY, impacted teeth should be removed before a complication arises [9]. Once it is diagnosed that a tooth is impacted and do not assume their proper function and position in the arch and has no potential for successful eruption, the tooth should be considered for extraction. Hence, extraction of impacted third molar is one of the most commonly performed procedures in the specialty of oral and maxillofacial surgery [10].

Several post-operative complications may arise during third molar extraction such as alveolar osteitis (dry socket), hemorrhage, nerve injuries and also fracture of mandible [11]. Damage to inferior alveolar nerve is a typical complication during that procedure [12, 13]. So the anatomy and position of mandibular third molar require greater consideration. Majority of these problems can be anticipated

preoperatively with adequate clinical examination and radiological investigations. Hence, the current study was planned to evaluate the frequency, angulation, depth of the impacted third molars and their ramus relationship radiographically.

MATERIALS & METHODS

The data required for this study was collected retrospectively in which informed consent of the patients were not obtained. For this study, the retrospective data of 786 patients who were in the age group of 21 - 40 yrs were screened.

Also the included cases should not be edentulous and with no history of surgery performed in the posterior region of mandible. Only high quality OPGs without any radiographic artifacts were included.

The exclusion criteria for this study were the cases having incomplete root formation, previous history of extraction and orthodontic treatment, presence of any bone pathology, presence of syndromes such as Down syndrome, alpert syndrome, ectodermal dysplasia, hyperparathyroidism etc. So the final data compromised of 402 OPGs for the study.

Orthopantograms were interpreted for the presence, location, depth and angulation of impacted third molars. Panoramic radiographs were used to evaluate the type of impaction (partially or completely impacted), basal bone height & its relationship with adjacent second molar.

The X-ray image viewer, tracing paper and scale were used to determine the position of impacted third molar. WINTER'S classification system was used to determine angulation of the long axis of impacted third molar with respect to the long axis of the second molar. It is classified as mesioangular, distoangular, vertical, horizontal, buccangular, lingualangular and inverted (Figure 1).

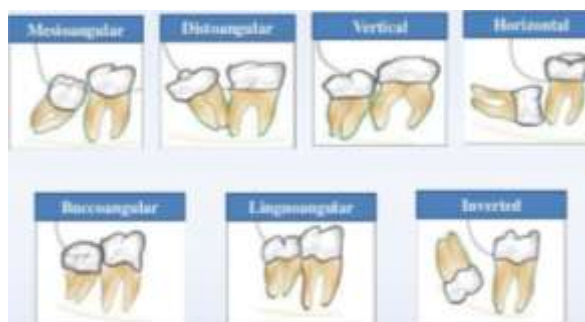

Figure-1

The depth of the impacted tooth compared with the height of the adjacent second molar provides the second system of classification for determining the difficulty of impaction removal. This classification system was suggested by PELL & GREGORY and is

called PELL AND GREGORY position A, B & C. In this classification system, the degree of difficulty is measured by the thickness of the overlying bone. It is described as follow:-

Position A

Occlusal surface of the impacted tooth is at the level or above the level of the occlusal plane of the adjacent second molar.

Position B

Impacted tooth with an occlusal surface between the occlusal plane and the cervical line of the adjacent second molar.

Position C

Occlusal surface of the impacted tooth is below the cervical line of the adjacent second molar (Figure 2).

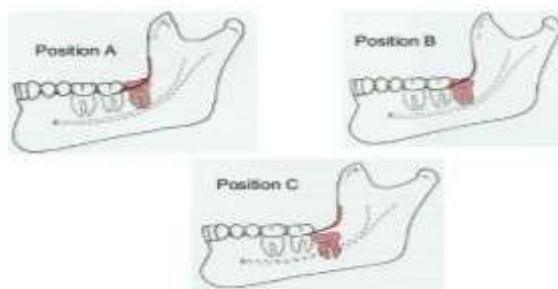


Fig-2

Another method for classifying impacted mandibular third molars is based on the amount of impacted tooth that is covered with bone of the mandibular ramus. This classification was also suggested by PELL & GREGORY and is referred to as PELL & GREGORY CLASS 1, 2 & 3 (Figure 3). It is described as below:

Class 1

The mesiodistal diameter of the crown is completely anterior to the anterior border of the mandibular ramus.

Class 2

The mesiodistal diameter of the crown of the mandibular third molar is partially embedded in the ramus of mandible.

Class 3

The mesiodistal diameter of the crown of the mandibular third molar is completely embedded in the ramus of mandible [14,15].

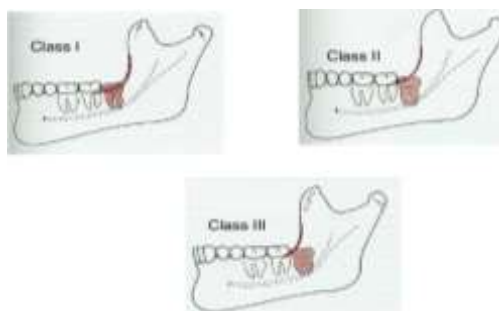


Fig-3

RESULTS

Among the 402 included cases, 255 OPGs had impacted third molars. The prevalence of impacted third molars in the maxilla and mandible were 185 and 404 respectively. Impacted third molars were 2.18 times more likely to occur in mandible than in maxilla (Graph 1).

The distribution of angulation of impacted third molars showed that mesioangular was the most frequent angulation of impaction (58.6%) followed by vertical (32.3%) & distoangular (26.6%). A significant correlation was found between the angular position & arch. There were significantly more mesioangular

impactions in mandible (48.1%) than in maxilla (10.5%) (Table 1).

Evaluation of the level of impaction showed that at Position B, the proportion of impacted third molars found in the mandible was 156 (i.e.38.9%) which was significantly higher than that of the maxilla i.e. 24 (5.9%). At Position C, the proportion of impacted third molars found in the maxilla was 150 (37.3%) which was significantly higher than that in mandible i.e.142 (35.4%) (Graph 2).

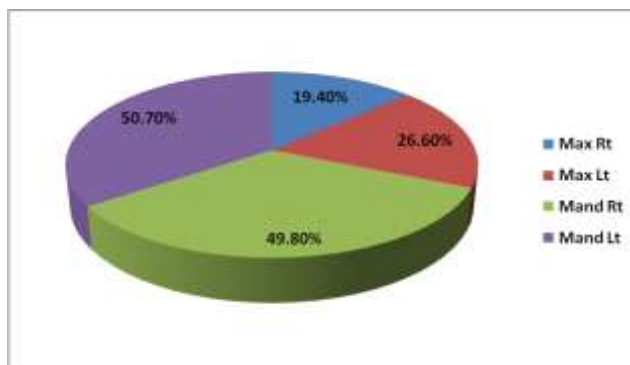
The current study showed that CLASS 2 (Mandibular right i.e. 112 & Mandibularl left i.e. 126)

was the most frequently encountered ramal relationship in both right & left mandibular impacted third molars followed by CLASS 3 (Mandibular right i.e. 77 &

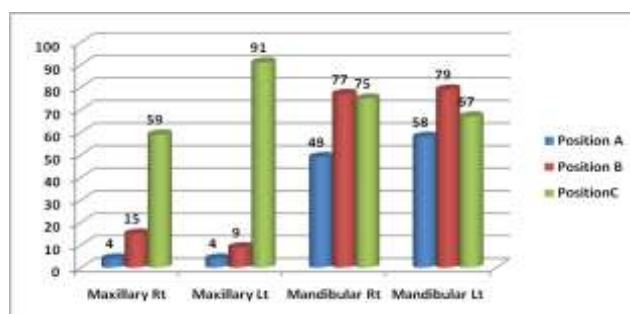
Mandibular left i.e. 70) & CLASS 3 (Mandibular right i.e. 11& Mandibular left i.e. 8) as depicted in Graph 3.

Table-1: Prevalence of angulation of impacted third molars according to winter’s classification

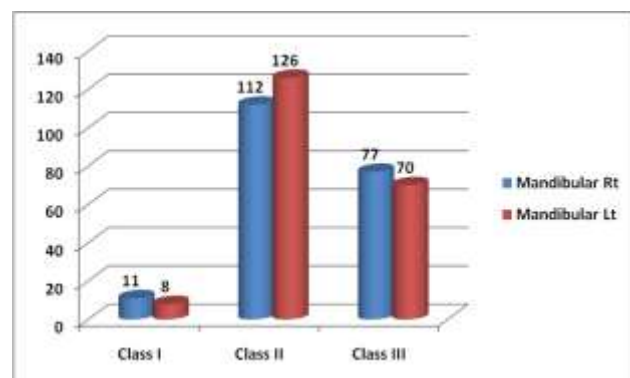
Mesioangular		Distoangular		Vertical		Horizontal		Buccolingual	
Maxilla	Mandible	Maxilla	Mandible	Maxilla	Mandible	Maxilla	Mandible	Maxilla	Mandible
44(10.5%)	212(48.1%)	67(15.3%)	49(11.2%)	70(16.0%)	72(16.3%)	4(0.9%)	55(12.4%)	2(0.5%)	3(0.6%)



Graph-1: Prevalence of impacted third molars in relation to individual arch



Graph-2: Position of impacted third molars according to Pell & Gregory classification



Graph-3: Ramal relationship of impacted third molars according to Pell & Gregory classification

DISCUSSION

Impaction of 3rd molars is a widespread pathological deformity in modern civilization. According to Elsey & Rock, its frequency is upto 73% among young adults [16]. Because of the increased incidence of unerupted third molars & it is normally associated with numerous complications. Therefore, assesment of third molars in terms of its position, angulation & level is a necessary intervention for better

patient management and decision making of whether to retain or remove these teeth.

Normally the growth of jaws basically completes at the age of 17 years. Therefore at the age of 21 yrs, it is possible to distinguish whether a third molar is in normal eruptive process or it will remain impacted in the jaw [17]. Thus, for the present study, patients between the age group of 21-40 yrs were

included. Similar age group samples were taken in the study conducted by Goyal S *et al.* [18].

Among all the OPGs reviewed, the results of the present study showed that prevalence of impacted third molars among the individuals was 63.4% (255) which was in consistent with the findings of the study conducted by Quek *et al* who also reported a higher prevalence of tooth impaction as (68%) in a sample of 1000 OPGs obtained from the Chinese people [21]. However, Arsalan Wahid *et al* reported that the prevalence of impaction was 30% which was lower than the statistics of present study [20].

In the present study, impacted third molars were 2.18 times more likely to occur in mandible than in maxilla. Similarly, Hashemipour *et al.* also reported 1.9 times higher incidence of impaction in mandible than in maxilla [21]. Of note, there are opposite findings in the other studies done by Kramer *et al* [22] (USA), Schersten *et al.* [23] (Sweden), Hattab *et al.* [24](Jordan).

Our results showed that 48.1% of impacted third molars were mesioangular in mandible. The present data was supported by findings of Santos and Quesada [25] showed in a study that mesioangular angulation of impaction (43.8%) was the most common in mandible. However the percentage of mesioangular impaction was considerably lower than that reported by Hattab *et al.* (50%) [26], Quek *et al.* (60%) [19] & Kruger *et al.* (62%) [27]. But higher in proportion than that reported by Byahatti & Ingafou (23.7%) [28].

Level of impaction indicates the depth at which a tooth is embedded in bone & estimates the height of third molar. Statistically strong evidence was detected between level of eruption & arch. The present records showed that Position B was the most common level of eruption in mandible & Position C in the maxilla. These figures were also observed by Quek *et al.*[19], Sandhu *et al.* [29] & Padhye *et al.* [30] in their data.

It was found that 59.2% of mandibular third molars were at CLASS 2 followed by 36.6% in CLASS 1 and 4.7% in CLASS 3. Results of the present study were in accordance with those of Dodson *et al.* [31], Gupta *et al.* [32] & Padhye *et al.* [30] as they also reported predominance of CLASS 2. In Class 2 situation, the tooth cannot be completely free from bone because a small shelf of bone overlies the distal portion of tooth. It should be obvious that the Class 1 relationship will provide the greatest accessibility to the impacted tooth & therefore will be easiest to remove. Class 3 relationship provides the least accessibility and therefore presents the greatest difficulty.

CONCLUSION

The current study revealed that third molar impaction was more prevalent in mandible than in maxilla & Mesioangular impaction was the most commonly encountered angular position. The most common pattern of impaction in the present study according to PELL & GREGORY classification was CLASS 2B followed by CLASS 1C. The data is very informative for planning surgical extraction of impacted third molars.

REFERENCES

1. Marks, S. C., & Schroeder, H. E. (1996). Tooth eruption: theories and facts. *The Anatomical Record*, 245(2), 374-393.
2. Kruger, G. O. (1959). Management of impactions. *Dent Clin North Am*, 707-722.
3. Ma'aita, J., & Alwrikat, A. (2000). Is the mandibular third molar a risk factor for mandibular angle fracture?. *Oral Surgery, Oral Medicine, Oral Pathology, Oral Radiology and Endodontics*, 89(2), 143-146.
4. Abu Alhaija, E. S. J., AlBhairan, H. M., & AlKhateeb, S. N. (2010). Mandibular third molar space in different antero-posterior skeletal patterns. *The European Journal of Orthodontics*, 33(5), 570-576.
5. Maričić, B. M., Legović, M., Šlaj, M., Lapter Varga, M., Žuvić Butorac, M., & Kapović, M. (2009). Presence of third molar germs in orthodontic patients with class II/2 and class III malocclusions. *Collegium antropologicum*, 33(4), 1171-1175.
6. Raghoebar, G. M., Boering, G., Vissink, A., & Stegenga, B. (1991). Eruption disturbances of permanent molars: a review. *Journal of oral pathology & medicine*, 20(4), 159-66.
7. Hashemipour, M. A., Tahmasbi-Arashlow, M., & Fahimi-Hanzaei, F. (2013). Incidence of impacted mandibular and maxillary third molars: a radiographic study in a Southeast Iran population. *Medicina oral, patologia oral y cirugia bucal*, 18(1), e140.
8. Perzin, K. H., Gullane, P., & Clairmont, A. C. (1978). Adenoid cystic carcinomas arising in salivary glands. A correlation of histologic features and clinical course. *Cancer*, 42(1), 265-282.
9. Peterson, L. J. (1998). Principles of management of impacted teeth. *Contemporary oral and maxillofacial surgery*, 2, 223-57.
10. Rajkumar, K., Ramen, S., Chowdhury, R., & Chattopadhyay, P. K. (2009). Mandibular third molars as a risk factor for angle fractures: a retrospective study. *Journal of Maxillofacial and Oral surgery*, 8(3), 237.
11. Monaco, G., MONTEVECCHI, M., BONETTI, G. A., Gatto, M. R. A., & CHECCHI, L. (2004). Reliability of panoramic radiography in evaluating the topographic relationship between the mandibular canal and impacted third molars. *The*

- Journal of the American Dental Association*, 135(3), 312-318.
12. Kim, J. W., Cha, I. H., Kim, S. J., & Kim, M. R. (2012). Which risk factors are associated with neurosensory deficits of inferior alveolar nerve after mandibular third molar extraction?. *Journal of oral and maxillofacial surgery*, 70(11), 2508-2514.
 13. Renton, T., Yilmaz, Z., & Gaballah, K. (2012). Evaluation of trigeminal nerve injuries in relation to third molar surgery in a prospective patient cohort. Recommendations for prevention. *International journal of oral and maxillofacial surgery*, 41(12), 1509-1518.
 14. Bell, G. W. (2004). Use of dental panoramic tomographs to predict the relation between mandibular third molar teeth and the inferior alveolar nerve: Radiological and surgical findings, and clinical outcome. *British Journal of Oral and Maxillofacial Surgery*, 42(1), 21-27.
 15. Laskin, D. M. (1985). *Oral and maxillofacial surgery* (Vol. 2, pp. 78-85). St. Louis, Mo.: Mosby.
 16. Elsey, M. J., & Rock, W. P. (2000). Influence of orthodontic treatment on development of third molars. *The British journal of oral & maxillofacial surgery*, 38(4), 350-353.
 17. Almpani, K., & Kolokitha, O. E. (2015). Role of third molars in orthodontics. *World Journal of Clinical Cases: WJCC*, 3(2), 132.
 18. Goyal, S., Verma, P., & Raj, S. S. (2016). Radiographic evaluation of the status of third molars in Sriganaganagar population—A digital panoramic study. *The Malaysian journal of medical sciences: MJMS*, 23(6), 103.
 19. Quek, S. L., Tay, C. K., Tay, K. H., Toh, S. L., & Lim, K. C. (2003). Pattern of third molar impaction in a Singapore Chinese population: a retrospective radiographic survey. *International journal of oral and maxillofacial surgery*, 32(5), 548-552.
 20. Wahid, A., Mian, F. I., Bokhari, S. A. H., Moazzam, A., Kramat, A., & Khan, F. (2013). Prevalence of impacted mandibular and maxillary third molars: a radiographic study in patients reporting madina teaching hospital, Faisal Abad. *Jumdc*, 4(2), 22-31.
 21. Hashemipour, M. A., Tahmasbi-Arashlow, M., & Fahimi-Hanzaei, F. (2013). Incidence of impacted mandibular and maxillary third molars: a radiographic study in a Southeast Iran population. *Medicina oral, patologia oral y cirugia bucal*, 18(1), e140.
 22. Kramer, R. M., & Williams, A. C. (1970). The incidence of impacted teeth: A survey at Harlem Hospital. *Oral Surgery, Oral Medicine, Oral Pathology*, 29(2), 237-241.
 23. Schersten, E., Lysell, L., & Rohlin, M. (1989). Prevalence of impacted third molars in dental students. *Swedish dental journal*, 13(1-2), 7-13.
 24. Hattab, F. N., Ma'amon, A. R., & Fahmy, M. S. (1995). Impaction status of third molars in Jordanian students. *Oral Surgery, Oral Medicine, Oral Pathology, Oral Radiology and Endodontics*, 79(1), 24-29.
 25. Santos, L. D., Laurek DECHICHE, N., Miranda ULBRICH, L., & Guariza, O. (2006). Análise radiográfica da prevalência de terceiros molares retidos efetuada na clínica de odontologia do Centro Universitário Positivo. *RSBO Revista Sul-Brasileira de Odontologia*, 3(1).
 26. Hattab, F. N., Ma'amon, A. R., & Fahmy, M. S. (1995). Impaction status of third molars in Jordanian students. *Oral Surgery, Oral Medicine, Oral Pathology, Oral Radiology and Endodontics*, 79(1), 24-29.
 27. Kruger, E., Thomson, W. M., & Konthasinghe, P. (2001). Third molar outcomes from age 18 to 26: findings from a population-based New Zealand longitudinal study. *Oral Surgery, Oral Medicine, Oral Pathology, Oral Radiology and Endodontics*, 92(2), 150-155.
 28. Richardson, M. E. (1977). The etiology and prediction of mandibular third molar impaction. *The Angle Orthodontist*, 47(3), 165-172.
 29. Sandhu, S., & Kaur, T. (2005). Radiographic evaluation of the status of third molars in the Asian-Indian students. *Journal of Oral and Maxillofacial Surgery*, 63(5), 640-645.
 30. Padhye, M. N., Dabir, A. V., Girotra, C. S., & Pandhi, V. H. (2013). Pattern of mandibular third molar impaction in the Indian population: a retrospective clinico-radiographic survey. *Oral surgery, oral medicine, oral pathology and oral radiology*, 116(3), e161-e166.
 31. Susarla, S. M., & Dodson, T. B. (2005). Estimating third molar extraction difficulty: a comparison of subjective and objective factors. *Journal of Oral and Maxillofacial Surgery*, 63(4), 427-434.
 32. Gupta, S., Bhowate, R. R., Nigam, N., & Saxena, S. (2010). Evaluation of impacted mandibular third molars by panoramic radiography. *ISRN dentistry*, 2011.