

Alternaria sp Mycotic Keratitis: A Case Report

Soukaina Adadi^{1*}, Ouahiba Bhalil², Bilal Moumni¹, Hayat Ben-Saghroune¹, Zineb Tlamçani¹¹Parasitology and Mycology Department, Central Laboratory of Medical Analysis, Hassan II University Hospital, Sidi Mohamed Ben Abdellah, Fez, Morocco²Immunology department, Central Laboratory of Medical Analysis, Hassan II University Hospital, Sidi Mohamed Ben Abdellah, Fez, MoroccoDOI: [10.36348/sjm.2022.v07i03.002](https://doi.org/10.36348/sjm.2022.v07i03.002)

| Received: 19.01.2022 | Accepted: 25.02.2022 | Published: 11.03.2022

***Corresponding Author:** Soukaina Adadi

Parasitology and Mycology Department, Central Laboratory of Medical Analysis, Hassan II University Hospital, Sidi Mohamed Ben Abdellah, Fez, Morocco

Abstract

Keratitis is a frequent pathology in everyday ophthalmology, whose etiologies are dominated by bacterial origin. The mycotic origin is a rare cause, and the prognosis is usually reserved, given the delay in diagnosis, mainly due to self-medication. We present a case report concerning a 60 year old patient who presented a mycotic corneal abscess due to *Alternaria sp*. He presented a stromal infiltration of the cornea of the left eye on biomicroscopic examination. A swab of the abscess was performed for mycological study which came back positive for *Alternaria sp*. On the basis of the clinical manifestations and conducted examination, a diagnosis of *Alternaria* mycotic keratitis was established.

Keywords: Mycotic keratitis, corneal abscess, *Alternaria sp*.**Copyright © 2022 The Author(s):** This is an open-access article distributed under the terms of the Creative Commons Attribution **4.0 International License (CC BY-NC 4.0)** which permits unrestricted use, distribution, and reproduction in any medium for non-commercial use provided the original author and source are credited.

INTRODUCTION

Fungal keratitis is a serious ocular affection which can engage the visual prognosis, its gravity is due to the common use of local corticoids, formally contraindicated in case of fungal infection, and to the diagnostic and therapeutic delay. Its diagnosis imposes the realization of microbiological samplings with a mycological study to identify the responsible fungus, it's commonly due to the *Fusarium sp* and *Aspergillus sp*, and exceptionally to *alternaria sp*. We report a case of *Alternaria sp* corneal abscess diagnosed in the parasitology-mycology department of the Hassan II University Hospital in Fez.

OBSERVATION

A 60 year old patient, monophthalmic, who was hospitalized in the ophthalmology department for a ocular pain, associated with a decrease vision, photophobia, and lacrimation, evolving for one week, without notion of wearing contact lenses, or local trauma.

Biomicroscopic examination showed: the presence of a perikeratic circle, conjunctival hyperemia, a hypopyon occupying the lower 1/3 of the anterior

chamber, the cornea is the seat of a 3mm/2mm stromal infiltration with infiltrated edges and central thinning, with presence of an anterior blepharitis, the visual acuity was quantified at "sees finger movements".

The diagnosis of corneal abscess (on surface pathology) was retained, and a sample by swabbing of the abscess was carried out for an eventual microbiological study (mycological + bacteriological + virological) in search of the responsible infectious agent: the bacteriological and virological researches were negative whereas the mycological study was positive.

Mycological Study

The swab of patient was mixed with a few drops of physiological water, and used for mycological study (direct examination + culture).

Direct examination in the fresh state showed the presence of conidia, isolated and grouped, ovoid and obclavate, of variable length, light brown in color, and divided by transverse partitions (Figure 1).

A culture was made on Sabouraud-Chloramphenicol(SC), Sabouraud-Chloramphenicol-

Actidione (SA) incubated at 37c° and on Sabouraud-chloramphenicol(SC) at 27c°. 3 days later, colonies appeared on the surface of the agar, first greyish, then darkened and became blackish.

A mounting in lactophenol blue between slide and coverslip was performed, showing the presence of

conidia of similar morphology to those found on direct examination (Figure 2).

Alternaria sp was retained as the cause of the keratitis.

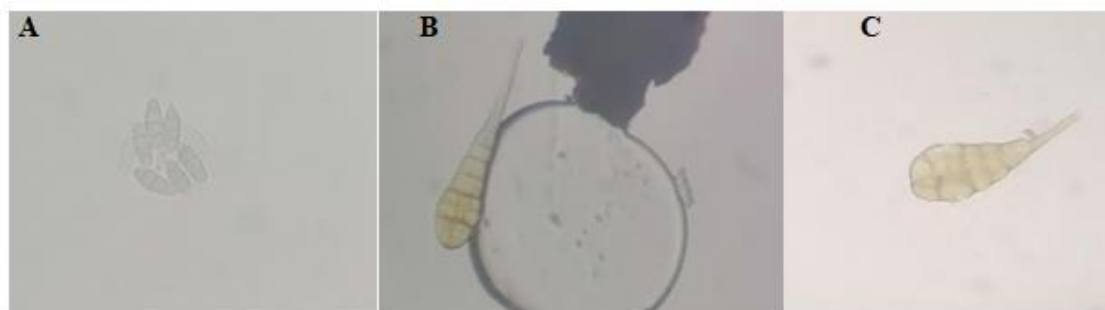


Figure 1: Direct examination at magnification (×40) showing oval conidia in clusters (A), and others of obclavate appearance (B and C)

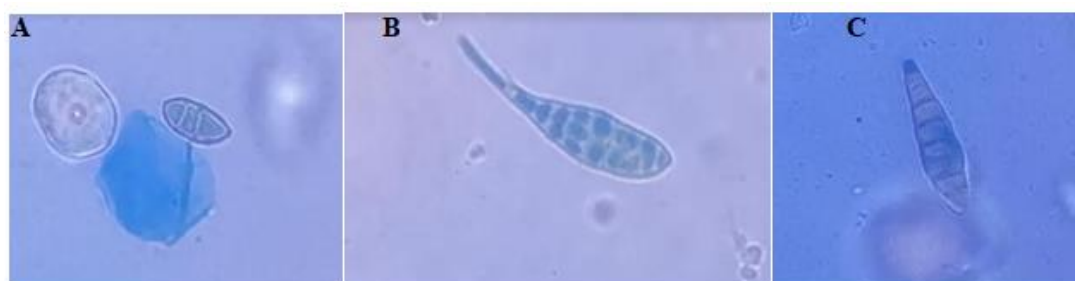

Figure 2: *Alternaria sp* after staining with lactophenol blue (magnification × 40), showing oval (A) and obclavate (B and C) conidia

DISCUSSION

Eye infections, such as keratitis, present a condition that can lead to devastating eye damage, including severe visual loss and blindness. The microorganisms responsible for such an infection can be bacteria or fungi.

Aspergillus is the most common cause of fungal keratitis, followed by *Candida*, *Fusarium*, *Curvularia* and *Alternaria* [1, 2], *Alternaria* infections are usually very rare, it is a cosmopolitan fungus, most commonly found in soil, plants, air and rot [3]. It can sometimes be found on the normal skin of humans and animals [4]. It is a non-pathogenic agent, but it can cause opportunistic infection or ocular infection such as keratitis and endophthalmitis after accidental trauma. In addition, it has been associated with respiratory and skin infections [4]. Ocular damage remains exceptional; for our patient, the mechanism of corneal damage remains unknown; it could be due to contamination by grains of sand or plant debris, manual or aerial, on a predisposed cornea (ocular surface pathology (anterior blepharitis), or to a trauma that went unnoticed.

To date, few cases of ocular infections caused by *Alternaria sp* have been reported: a study in Tunisia

of 43 cases of fungal keratitis found 2 cases of *Alternaria sp* keratomycosis [5], another study in Spain of 210 cases of human alternaria revealed 20 cases of *Alternaria sp* keratitis [4], and sporadic cases have been described in Italy [6] and America [7]. However, no case of *Alternaria* keratomycosis has been described in Morocco.

Mycological diagnosis is a crucial part of any suspected case of keratomycosis. The culture of the corneal sample remains the key examination for the positive diagnosis of keratomycosis [8, 9].

CONCLUSION

Keratomycosis represent a rare but serious clinical entity. Although the etiologies are dominated by bacterial origin, rarer causes, notably fungal such as *Alternaria sp*. early diagnosis and specific treatment to avoid serious complications that can affect the functional prognosis.

Disclosure of Interest: The authors declare that they have no conflicts of interest concerning this article

REFERENCE

1. Sherwal, B. L., & Verma, A. K. (2008). Epidemiology of ocular infection due to bacteria and fungus-a prospective study. *JK Sci*, 10(3), 127-131.
2. Niu, L., Liu, X., Ma, Z., Yin, Y., Sun, L., Yang, L., & Zheng, Y. (2020). Fungal keratitis: Pathogenesis, diagnosis and prevention. *Microbial pathogenesis*, 138, 103802.
3. Hibbett, D. S., Binder, M., Bischoff, J. F., Blackwell, M., Cannon, P. F., Eriksson, O. E., ... & Zhang, N. (2007). A higher-level phylogenetic classification of the Fungi. *Mycological research*, 111(5), 509-547.
4. Pastor, F. J., & Guarro, J. (2008). *Alternaria* infections: laboratory diagnosis and relevant clinical features. *Clinical Microbiology and Infection*, 14(8), 734-746.
5. Derbel, M., Ben Zina, Z., & Mhiri, W. (2002). Kératomycose : aspects cliniques, démarche diagnostique et thérapeutique. À propos de 43 cas. *Journal français d'ophtalmologie*, 25(5), 103-104
6. Monno, R., Alessio, G., Guerriero, S., Caggiano, G., Capolongo, C., De Vito, D., & Sanguinetti, M. (2015). *Alternaria* is an infrequent cause of keratitis: a case report and review of the literature. *Eye & Contact Lens*, 41(4), e14-e17.
7. McGirr, S., Andersen, D., & Halgren, J. (2020). *Alternaria* keratitis after corneal crosslinking. *American Journal of Ophthalmology Case Reports*, 17, 100616.
8. Olfa, F., Omar, H. S., Hsouna, M. Z., Sonya, M., Kais, B., & Leila, N. (2019). Fil microbiologique des abcès mycosiques dans un centre de référence en Tunisie La tunisie Medicale, 97(5), 644-649.
9. Mahmoudi, S., Masoomi, A., Ahmadikia, K., Tabatabaei, S. A., Soleimani, M., Rezaie, S., ... & Banafsheafshan, A. (2018). Fungal keratitis: An overview of clinical and laboratory aspects. *Mycoses*, 61(12), 916-930.