

# Intra-Vesical Foreign Bodies; Experience with Management in North Central Nigeria

Terkaa Atim<sup>1,2\*</sup>, Amina Buba<sup>2</sup>

<sup>1</sup>Department of Surgery, College of Health Sciences, University of Abuja, Nigeria

<sup>2</sup>Department of Surgery, University of Abuja Teaching Hospital, Nigeria

DOI: [10.36348/sjm.2019.v04i08.011](https://doi.org/10.36348/sjm.2019.v04i08.011)

| Received: 16.08.2019 | Accepted: 25.08.2019 | Published: 30.08.2019

\*Corresponding author: Dr. Terkaa Atim

## Abstract

**Background:** Foreign bodies within the bladder pose a challenging urologic problem as a result of their diversity, varied presentation and tailored management. Examples of foreign bodies that have been removed from the urinary bladder include electric wires, glass ampoules, sticks, ball point pens, pencils, safety-pins, hairclips, magnetic balls, intrauterine contraceptive devices (IUCD), gauze pieces, pelvic drains and batteries. **Methods:** We carried out a retrospective review of patients who were found to have intravesical foreign bodies intraoperatively between January 2017 and December 2018 in Abuja, Nigeria. **Results:** Five patients were found to have intravesical foreign bodies. There were 4 female and a male patient. The mean age at the time of presentation was 51 years. The aetiology was iatrogenic in all but one patient. There was varied mode of presentation. Plain radiographs and abdominopelvic ultrasonography were useful in diagnosis. Endoscopic removal of the foreign body was successful in 3 patients whilst one patient had a suprapubic cystostomy and another suprapubic cystolithotomy. **Conclusion:** Our review highlights the importance of educating health care workers on the need to ensure catheters, stents, abdominal drains are removed following their stipulated time of use. Awareness of this rare entity as an important possible differential diagnosis in patient presenting with urologic symptoms is also important.

**Keywords:** Foreign bodies, Intra-vesical, Iatrogenic, Endoscopic.

**Copyright © 2019:** This is an open-access article distributed under the terms of the Creative Commons Attribution license which permits unrestricted use, distribution, and reproduction in any medium for non-commercial use (Non-Commercial, or CC-BY-NC) provided the original author and source are credited.

## INTRODUCTION

Foreign bodies (FB) within the bladder pose a challenging urologic problem as a result of their diversity, varied presentation and tailored management [1-5]. Various FBs have been removed from the urinary bladder. Examples include electric wires, glass ampoules, sticks, ball point pens, pencils, safety-pins, hairclips, magnetic balls, intrauterine contraceptive devices (IUCD), gauze pieces, pelvic drains, batteries, leech, hairballs and many others [3-14].

The aetiology of intra-vesical foreign bodies includes insertion of the object through the urethra during masturbation [8, 9, 15], accidental migration via the urethra, migration from surrounding structures [6, 10] and iatrogenic surgical complication [2, 16, 17]. FB are usually inserted via the urethra for the purposes of sexual gratification, curiosity, initiating abortion and as a result of mental illness, senility or substance abuse [2, 6, 18]. Migration of objects such as intrauterine contraceptive device (IUCD), non-absorbable sutures, surgical instruments and surgical sponge into the urinary bladder have also been reported [19-21].

Following the increased placement of prosthetic devices within the urinary tract for medical reasons, iatrogenic FB have become a well-known complication. Hitherto the commonest cause of iatrogenic introduction was the abdominal sponge called gossypiboma [21-23].

The clinical presentation in most cases of vesical FB ranges from pain in the lower abdomen and genitalia, hematuria, features of cystitis to urinary retention [2, 3, 6, 24, 25]. Imaging studies (x-rays and sonography) are useful in the diagnosis and planning of the treatment for all patients [2, 3, 26, 27].

In the West African region, it is rare to have patients present with retained intravesical FBs. There are several reasons for this including lack of resources to make the diagnosis in community health centres. We carried out a retrospective review of patients who were found to have FBs in the bladder. The aim of this study is to review the exact etiology, clinical presentation and most suitable method of treatment of intra-vesical FB in our local practice.

### PATIENTS AND METHOD

In this retrospective report, all patients that presented to our practice with suspected foreign bodies (FB) in the urinary bladder between January 2017 and December 2018 were evaluated by clinical history, physical examination, abdominal ultrasonography, plain abdominal X-ray, urinalysis, urine culture, full blood count (FBC) and blood chemistry.

Urethrocystoscopy was carried out under either caudal block anesthesia or subarachnoid block for visualization of the foreign body in the urinary bladder except in a patient who had a suprapubic catheter in

place for urethral stricture disease. During each cystoscopic procedure attempt was made at removing the FB endoscopically. When cystoscopic retrieval failed, we resorted to doing an open cystostomy/cystolithotomy to extract the FB.

### RESULTS

There were five patients (4 females and one male) with intra-vesical FB encountered in our practice during the period of January 2017 and December 2018, (Fig 1) with a mean age of 51years. The aetiology of the intra-vesical FB among these patients varied as follows; self-inserted (1, 20%) and iatrogenic (4, 80%).

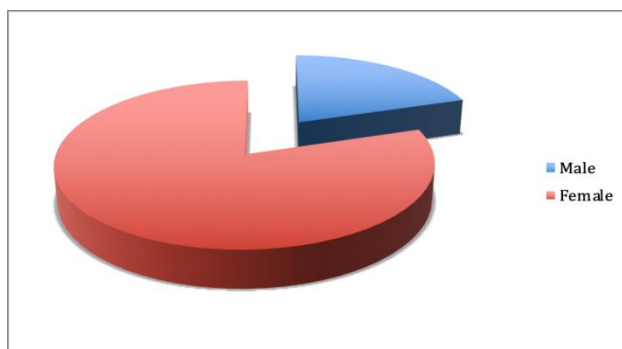


Fig-1: Gender distribution of patients with intra-vesical foreign bodies

Typical symptoms at presentation were as depicted in Table-1.

Table-1: Demographic characteristics, clinical presentation, aetiology and type of treatment of patients with intra-vesical foreign bodies

Patient number	Age (years)	Sex	Presentation	Aetiology	Urine culture	Treatment
1	54	F	LUTS, hematuria and dysuria	Cut stem of a foley’s catheter	-	Endoscopic
2	31	F	Pain in RIF and pelvis, LUTS, dysuria and hematuria	Migrated Peritoneal tube drain	Klebsiella specie	Endoscopic
3	58	M	Suprapubic pain, hematuria and LUTS	Retained Suprapubic catheter with stone encrustations	-	Open
4	67	F	LUTS, LIF pain, dysuria, fever, and vomiting	Neglected double J stent with stone encrustation	Proteus mirabilis	Endoscopic
5	48	F	LUTS and Lower abdominal pain	Self-insertion of eye brow pencil during masturbation	-	Endoscopic converted to Open

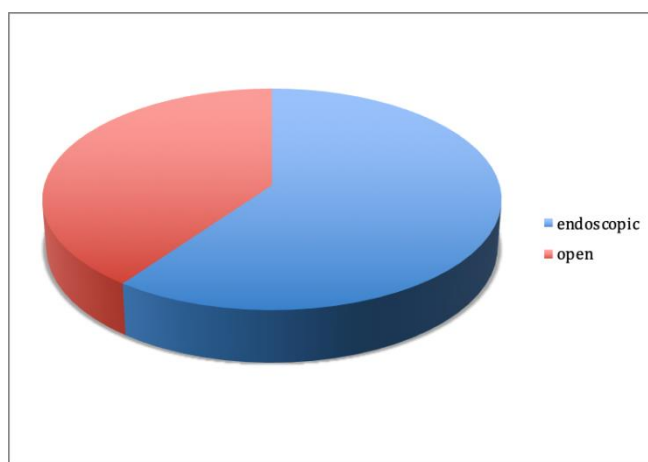


Fig-2: Types of surgical treatment performed for intra-vesical foreign bodies

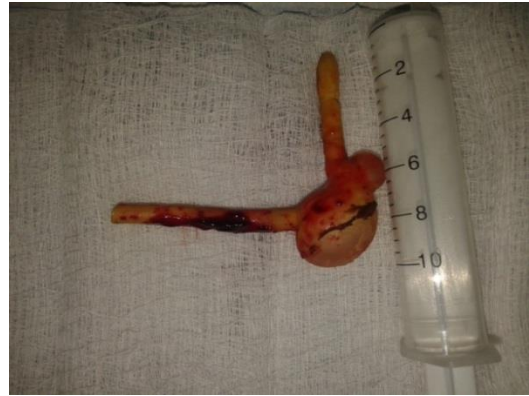Urease splitting microbial organisms (proteus mirabilis and klebsiella specie) were isolated in the

urine specimen of two (40%) of the patients who were subsequently treated with appropriate antibiotics before

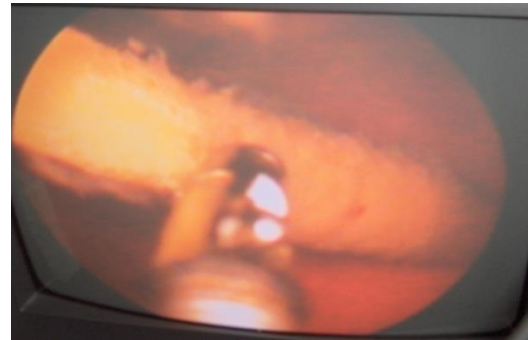definitive care. Ultrasonography and x-rays were used in detecting all the FB in this series. Urethro-cystoscopy was performed on all except one patient (Fig 2). The patient in whom urethro-cystoscopy could not be done required a cystolithotomy to remove a retained catheter with stone encrustation at the intra-vesical part. We had to convert from endoscopic procedure to open cystostomy in a lady who inserted an eye brow pencil. Other instruments deployed in the endoscopic removal of FB included stent removing and stone punch forceps.

Patient 1 was a 54 year old lady in whom we found the stem of a cut foley's catheter with partially deflated balloon inside her bladder at cystoscopy during evaluation for a missing piece of catheter. She was referred to us with a history of a missing cut piece of a foley's catheter from another district hospital. The attending health care worker cut the stem of the catheter in an attempt to remove it after failure to deflate the balloon. After cutting the stem of the foley's catheter close to the meatus, the cut piece migrated into the bladder and could not be seen moments later. The migrated stem of the catheter was removed at cystoscopy under caudal block anaesthesia using a stone punch forceps (Fig 3).

Patient 2 was a 31 year old lady who had emergency exploratory laparotomy following ruptured appendicitis in a local hospital 9months prior to presentation at our hospital. She presented to us with a history of recurrent urinary tract infections (UTI), irritative LUTS, and dysuria. Urinalysis was positive for leucocytes, nitrites and blood. Urine culture revealed heavy growth of klebsiella which was treated with levofloxacin. Abdominal ultrasonography revealed a FB in the bladder. After successfully treating the UTI she underwent cystoscopy under caudal block anaesthesia. An encrusted tube drain was seen protruding into the bladder from its right lateral wall (Fig-4). With the aid of a stent removing forceps the tube drain (piece of intravenous giving set) was gently removed (Fig-5). A urethral catheter was inserted and kept on continuous bladder drainage for 14days. We observed her for any features of peritonitis and discharged her home after 72hrs of uneventful hospital stay. On further probing, she recalled having an abdominal drain during the emergency surgery 9 months earlier but could not say if tube was removed prior to her discharge from hospital.



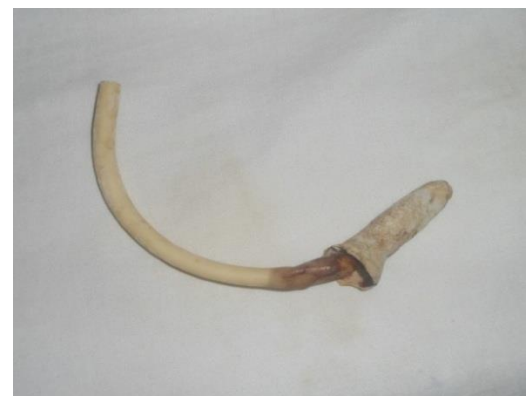**Fig-3: Stem of cut missing foley's catheter removed at cystoscopy**



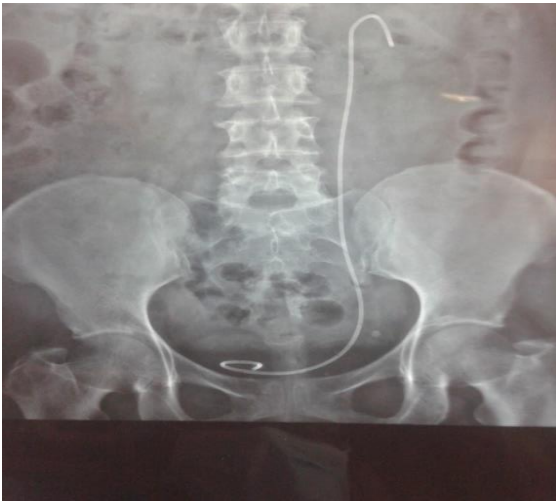**Fig-4: Endoscopic view of migrated peritoneal tube drain grasped by stent removing forceps**




**Fig-5: Migrated peritoneal tube drain after removal from the bladder**



**Fig-6: Retained suprapubic catheter with stone encrustation at the intra-vesical part**



**Fig-7: Plain abdominal KUB X-ray showing a double J stent in situ**

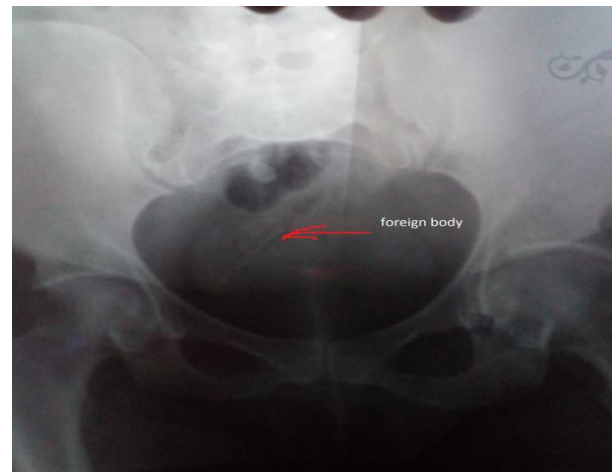

**Fig-8: Neglected Double J stent with stone encrustation seen at the intravesical part**

Patient 3 was a 58 year old man with urethral stricture disease who had suprapubic catheter placed in our emergency unit 10 months prior to the index presentation. He was not ready for definitive urethroplasty and elected to have the monthly catheter changes done at a clinic near his home. He defaulted from changing his catheter for about three months and the catheter could not be removed by the staff at the clinic so he was re-referred to us. At presentation the suprapubic catheter was in place and balloon was fully deflated but the catheter could not be removed. A pelvic x-ray showed a hyperechoic lesion casting posterior acoustic shadow and encasing the catheter. There were internal echoes in the bladder on sonography and urine culture showed growth of proteus mirabilis which was treated. He underwent suprapubic cystostomy under spinal anaesthesia and removal of the catheter. Stone encrustations were seen at the intra-vesical portion of the catheter (Fig 6). He eventually had urethroplasty 3 weeks later and was followed up for about 1 year after which he was discharged from the urology clinic.

Patient 4 was a 67 year old lady who presented one year after insertion of a double J stent following laser lithotripsy at another hospital. She presented with severe left iliac fossa pain, fever and vomiting. However, the patient was not informed of the need to

have the stent removed at a later date. At the time of presentation to us, she was dehydrated and febrile with a temperature of 38° C. There was marked left renal angle and iliac fossa tenderness. FBC showed leucocytosis with relative neutrophilia. Urinalysis was positive for leucocytes and nitrites and a growth of proteus mirabilis was detected on urine culture. She was admitted for resuscitation and treated for acute left pyelonephritis. An Abdominal ultrasonography showed a double J stent in situ with stone encrustation at the intra-vesical part and ipsilateral hydronephrosis. A plain abdominal radiograph confirmed the presence of a properly cited double J stent (Fig-7). She had cystoscopy under caudal block anaesthesia. A double J stent with stone encrustation around it was seen and removed using a stent removing forceps (Fig-8). She was discharged the same day on antibiotics and followed up 2 weeks later in clinic. She reported complete resolution of symptoms.



**Fig-9: Pelvic X-ray showing a radio-opaque foreign body in the region of the bladder**

Patient 5 was a 48year old lady who accidentally inserted an eye brow pencil into her urinary bladder during masturbation. Her complaints were dysuria, hematuria, urinary frequency and lower abdominal pain. There was no history of psychiatric disorder and no comorbidity. Both plain abdominal radiograph (Fig 9) and pelvic ultrasonography confirmed the presence of a radiopaque rod-like hyperdense object measuring 10cm in the urinary bladder (Fig-10). At urethro-cystoscopy an eye brow pencil was seen in the bladder and attempts at removing the pencil using a stone crushing forceps were unsuccessful. We converted to a suprapubic cystostomy to remove the eye brow pencil (Fig 11 and 12). A psychiatric consultation was requested and no disorder was noted. She was discharged home with a urethral catheter on continuous drainage on the third day and one week later the catheter was removed. There was no problem at follow up visit 3 months later.



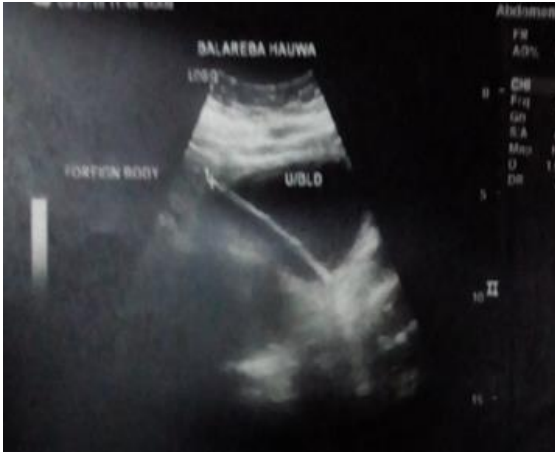

Fig-10: Sonoprint depicting a rod-like hyperdense object 10cm in length seen the urinary bladder

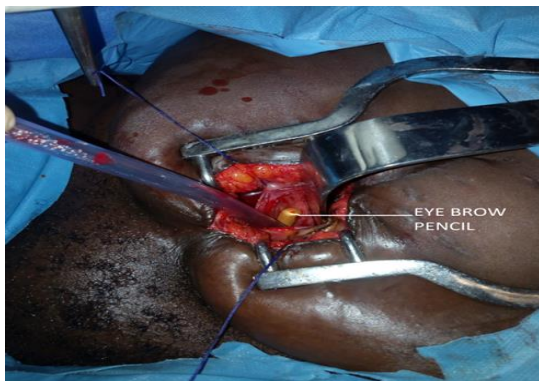

Fig-11: Suprapubic cystostomy showing the eye brow pencil in the urinary bladder



Fig-12: Eyebrow pencil extracted from the urinary bladder

## DISCUSSION

Foreign bodies in the urinary bladder are relatively uncommon and only few cases have been reported in isolation in Nigeria [8-10, 26, 28]. With recent advances in technology, numerous objects such as catheters, stents, and instruments are routinely introduced into patients' urinary tract for several reasons [5, 23, 29]. This has given rise to an increase in the incidence of iatrogenic foreign bodies. Moreover, self-insertion performed for sexual aggrandizement is also a notable contributor to the burden of foreign bodies in the urinary bladder [2, 3, 5, 6, 9, 17, 24, 29, 30]. In such cases, the patient often presents late due to feeling of embarrassment [8, 24].

Intra-vesical self-insertion of FB may be associated with psychiatric problems and some authors suggest a psychiatric evaluation for all cases, an issue that is still controversial [31, 32]. The sex incidence of intra-vesical foreign bodies is 1.7:1 with a slight preponderance among males [24, 25]. We however, observed more occurrence in females in our study, similar to reports by Mannan *et al.*, [3]. The short female urethra makes it more receptive to insertion and migration of foreign bodies [3, 18].

In our study, we encountered one case of self-inserted FB (1, 20%) while the remaining (4, 80%) were as a result of iatrogenic causes. The motive behind the self-inserted eyebrow pencil in the lady was for sexual gratification. Whereas most investigators report autoeroticism as the commonest reason for foreign bodies in the bladder [1, 2, 6, 14, 18, 30, 32] the contrary was the case in our study where iatrogenic causes were more predominant. A few other researchers have reported similar findings [3, 17]. Iatrogenic intra-vesical foreign bodies have been documented following open bladder surgeries. The nature of these FBs include gauze [16], clips and sutures with stones [19]. FBs can perforate either at the time of insertion or by slow migration across the bladder and uterine walls especially with intrauterine contraceptive devices (IUCD) [10, 20]. Slow migration across the bladder wall could have been the mechanism following the migrated peritoneal drain.

Long term catheter use and forgotten ureteral stents can result in catheter and stent encrustations with stone formation within the urinary tract [35]. As a consequence urinary catheters and ureteral stents may be retained and result in urinary tract infections [8, 34, 35]. These encrustations can occur either in the lumen of the catheter or extraluminally resulting in the catheters being retained or blocked [34]. Urease splitting bacteria especially proteus mirabilis are the culprit responsible for catheter encrustation (Table-1) and they achieve this by colonizing the device thus forming a biofilm. Patients with a retained encrusted Foley catheter suffer from genital pain, bladder spasms and peri-catheter urinary leakage and urinary retention [8, 34, 35]. Suprapubic cystostomy is usually required in such cases where catheter encrustations and overlying stone formation complicate removal of the catheters [8, 28, 35]. Performing a suprapubic cystostomy is more technically demanding, as such allied health care workers are more likely to refer to a physician when they encounter challenges like blockage or dislodgement [35].

Prolonged retention of foreign bodies in the urinary tract can equally lead to the formation of vesical stones [28, 34, 35]. Radiological investigations were instrumental in making a correct diagnosis and planning treatment for all our patients [2, 3, 4, 26, 27]. Plain abdominal radiographs revealed radiopaque FB and

together with ultrasonography and urethra-cystoscopy would suffice in making a diagnosis.

In most of the cases, the foreign bodies could be removed from the bladder at cystoscopy [1, 3, 24, 26, 36]. There are several modifications to minimally invasive methods of removing intra-vesical FBs such as use of nephroscopes, CO<sub>2</sub> insufflation cystoscopy, percutaneous access, amplatz sheaths, lasers and lithotripsy [4, 37]. Recently, Ho: YAG laser has been used to fragment large size foreign body inside the bladder thus facilitating removal through the cystoscope using forceps [37]. Cystoscopic removal using stent removing forceps was effective in the following cases: an encrusted Double J stent, a migrated peritoneal drain and the stem of cut foley's catheter. The double J stent provides a convenient means of drainage for the upper urinary tract. It is a common procedure in daily urologic practice. Serious complications such as migration, fragmentation, encrustation, and stone formation may occur, especially when stents are left in situ for long periods of time. Furthermore, a forgotten stent usually presents a complicated management and legal dilemma [29]. Cystoscopic removal of the foreign bodies with forceps is usually the preferred option, but when this is not feasible, open suprapubic cystostomy/cystolithotomy is required. For instance, in the case of eye brow pencil in the urinary bladder we managed, cystoscopic removal failed necessitating conversion to open cystostomy and safe removal of the object. Suprapubic cystostomy has been reported to be the procedure of choice where endoscopic maneuvers fail [4].

## CONCLUSION

This review highlights some important learning points. In the literature available, most cases of retained FBs in the bladder arise following accidental or intentional insertion by the patient. However, our data despite being small, suggests that the main aetiology in our practice is iatrogenic.

It is therefore important that health care professionals are educated on the need to ensure that these foreign bodies are appropriately removed after carrying out the intended use for which they were inserted. Also, the possibility of a retained FB should be considered in patients presenting with urologic symptoms particularly after a previous hospital encounter.

**Conflict Of Interest:** None to declare.

## REFERENCES

1. Datta, B., Ghosh, M., & Biswas, S. (2011). Foreign bodies in urinary bladders. *Saudi Journal of Kidney Diseases and Transplantation*, 22(2), 302-305.
2. Shaikh, A. R., Shaikh, N. A., Abbasi, A., Soomro, M. I., & Memon, A. A. (2010). Foreign bodies in the urinary bladder. *Rawal Medical Journal*, 35(2), 194-197.
3. Mannan, A., Anwar, S., Qayyum, A., & Tasneem, R. A. (2011). Foreign bodies in the urinary bladder and their management: a Pakistani experience. *Singapore medical journal*, 52(1), 24-28.
4. Eckford, S. D., Persad, R. A., Brewster, S. F., & Gingell, J. C. (1992). Intravesical foreign bodies: five year review. *British journal of urology*, 69(1), 41-45.
5. Bansal, A., Yadav, P., Kumar, M., Sankhwar, S., Purkait, B., Jhanwar, A., & Singh, S. (2016). Foreign bodies in the urinary bladder and their management: a single-centre experience from North India. *International neurourology journal*, 20(3), 260-269.
6. Van Ophoven, A., & DE KERNION, J. B. (2000). Clinical management of foreign bodies of the genitourinary tract. *The Journal of urology*, 164(2), 274-287.
7. Mibang, N., Faridi, M. S., Rahman, M. J., Shantajit, N., Lalrammuana, R., & Somarendra, K. (2016). Glass ampoule in urinary bladder as a foreign body. *Asian journal of urology*, 3(2), 96-98.
8. Bello, A., Kalayi, G. D., Maitama, H. Y., Mbibu, N. H., & Kalba, D. U. (2009). Bladder Calculus following an unusual vesical foreign body. *Journal of surgical technique and case report*, 1(1), 37-38.
9. Irekpa, E., Imomoh, P., Kesieme, E., & Onuora, V. (2011). Intravesical foreign bodies: a case report and a review of the literature. *International medical case reports journal*, 4(1):35-39.
10. Nwofor, A. M. E., & Ikechebelu, J. I. (2003). Uterovesical fistula and bladder stones following bladder penetration by a perforating intrauterine contraceptive device. *Journal of Obstetrics and Gynaecology*, 23(6), 683-684.
11. Bantis, A., Sountoulides, P., Kalaitzis, C., Giannakopoulos, S., Agelonidou, E., Foutziti, S., & Touloupidis, S. (2010). Perforation of the urinary bladder caused by transurethral insertion of a pencil for the purpose of masturbation in a 29-year-old female. *Case reports in medicine*, 2010.
12. Stravodimos, K. G., Koritsiadis, G., & Koutalellis, G. (2009). Electrical wire as a foreign body in a male urethra: a case report. *Journal of Medical Case Reports*, 3(1), 49.
13. Mukherjee, G. (1974). Unusual foreign body causing haematuria. *Journal of the Indian Medical Association*, 63(9), 284-285.
14. Ortoglu, F., Gürlen, G., Kuyucu, F., Erçil, H., & Ünal, U. (2015). A rare foreign material in the bladder: Piece of pencil. *Archives of Iranian medicine*, 18(9), 616-617.
15. Song, J. B., Tanagho, Y. S., Haseebuddin, M., Benway, B. M., Desai, A. C., Bhayani, S. B., & Figenschau, R. S. (2013). Endoscopic management

- of genitourinary foreign bodies. *Reviews in urology*, 15(2), 84-89.
16. Dakum, N. K., & Iya, D. (2001). Urinary retention caused by foreign body. *Nigerian Journal of Surgical Research*, 3(2), 90-92.
  17. Hemal, A. K., Taneja, R., Sharma, R. K., & Wadhwa, S. N. (1998). Unusual foreign bodies in urinary bladder: point of technique for their retrieval. *Eastern Journal of Medicine*, 3(1), 30-31.
  18. Cyprien, Z., Timothée, K., Gustave, S. B., Adama, O., Alain, T. I., Karim, P. A., & Adolphe, S. D. (2014). An Unusual Intravesical Foreign Body for Abortion Attempt. About a Case Report at Bobo Dioulasso University Teaching Hospital (Burkina Faso) and Literature Review. *Open Journal of Urology*, 4(04), 33-36.
  19. Kadekawa, K., Hossain, R. Z., Nishijima, S., Miyazato, M., Hokama, S., Oshiro, Y., & Sugaya, K. (2009). Migration of a metal clip into the urinary bladder. *Urological research*, 37(2), 117-119.
  20. Su, Y. R., & Chan, P. H. (2014). Mesh migration into urinary bladder after open ventral herniorrhaphy with mesh: a case report. *International surgery*, 99(4), 410-413.
  21. Stawicki, S. P., Evans, D. C., Cipolla, J., Seamon, M. J., Lukaszczyk, J. J., Prosciak, M. P., ... & Steinberg, S. M. (2009). Retained surgical foreign bodies: a comprehensive review of risks and preventive strategies. *Scandinavian Journal of Surgery*, 98(1), 8-17.
  22. Ugwu, B. T., Isamade, E. S., Misau, M. A., Mohammad, A. M., Uwumarogie, O. L., Liman, H. U., & Sani, A. A. (2004). Forgotten foreign bodies in the abdomen. *Niger Journal Surgery Research*, 6(3):137-140.
  23. Kelkar, V., & Patil, D. (2012). Management of forgotten double J stent and severe multiple large encrusted stones in the bladder and renal pelvis. *Central European journal of urology*, 65(4), 238-241.
  24. Bedi, N., El-Husseiny, T., Buchholz, N., & Masood, J. (2010). 'Putting lead in your pencil': self-insertion of an unusual urethral foreign body for sexual gratification. *JRSM short reports*, 1(2), 1-5.
  25. Ugur, B., Horsanali, M. O., Kartalmis, M., Girgin, C., & Dincel, C. (2011). Mesanede nadir bir yabancı cisim: tig./An unusual foreign body in the urinary bladder: beading awl. *Turkish Journal of Urology*, 37(3), 275-278.
  26. Oguntayo, O. A., Zayyan, M., Odogwu, K., Koledade, K., Mbibu, H., Bello, A., & Sani, S. (2009). Foreign body (metallic flashlight cover) in the urinary bladder mimicking advanced cancer of the cervix: Case report and review of the literature. *African Journal of Urology*, 15(2), 111-113.
  27. Ceran, C., & Uguralp, S. (2012). Self-inflicted urethrovaginal foreign bodies in children. *Case reports in urology*, 2012, 1-3.
  28. Okwudili, O. A., Nnabuiife, A. O., & Ogbu, U. C. (2018). An Unusual Cause of Retained Suprapubic Foley Catheter-Case Report and Literature Review, 1(1):5-8.
  29. Ahallal, Y., Khallouk, A., El Fassi, M. J., & Farih, M. H. (2010). Risk factor analysis and management of ureteral double-j stent complications. *Reviews in urology*, 12(2-3), e147-151.
  30. Moon, S. J., Dai Hee Kim, J. H. C., Jo, J. K., Son, Y. W., Choi, H. Y., & Moon, H. S. (2010). Unusual foreign bodies in the urinary bladder and urethra due to autoerotism. *International neurourology journal*, 14(3), 186-189.
  31. Kenney, R. D. (1988). Adolescent males who insert genitourinary foreign bodies: is psychiatric referral required?. *Urology*, 32(2), 127-129.
  32. Trehan, R. K., Haroon, A., Memon, S., & Turner, D. (2007). Successful removal of a telephone cable, a foreign body through the urethra into the bladder: a case report. *Journal of medical case reports*, 1(1), 153.
  33. Kochakarn, W., & Pummanagura, W. (2008). Foreign bodies in the female urinary bladder: 20-year experience in Ramathibodi Hospital. *Asian Journal of Surgery*, 31(3), 130-133.
  34. Ho, C. K., Khandasamy, Y., Singam, P., Hong Goh, E., & Zainuddin, Z. (2010). Encrusted and incarcerated urinary bladder catheter: what are the options?. *Libyan Journal of Medicine*, 5(1), 5686.
  35. Kumar, M., Narayan, T. A., Kaundal, P., & Sadasukshi, N. (2017). Neglected Suprapubic Catheter: Stone Formation On Foley Balloon Catheter. *Ann Int Med Dent Res*, 3((Supplementary1):10-12.
  36. Cury, J., Coelho, R. F., & Srougi, M. (2006). Retroperitoneal migration of a self-inflicted ballpoint pen via the urethra. *International braz j urol*, 32(2), 193-195.
  37. Wyatt, J., & Hammontree, L. N. (2006). Use of Holmium: YAG laser to facilitate removal of intravesical foreign bodies. *Journal of endourology*, 20(9), 672-674.