

Rupture of A Giant Retro-Caval Aneurysm of the Right Renal Artery about A Case

H. Elloumi*, M. Chtoutourou

Service of Urology, Habib Thamer Hospital, Rue Ali Ben Ayed, Tunis, Tunisia

*Corresponding author: Elloumi Habib

| Received: 18.05.2019 | Accepted: 25.05.2019 | Published: 30.05.2019

DOI: [10.36348/sjm.2019.v04i05.013](https://doi.org/10.36348/sjm.2019.v04i05.013)

Abstract

We report the case of Mr IS 50 years old without notable antecedents, admitted in our service in a haemorrhagic table of shock associated with an abdominal mass giving the lumbar contact in connection with a broken aneurysm in the right renal artery associated with ipsilateral renal ischemia. A right nephrectomy was carried out and a subtotal resection of aneurysm with installation of a drainage. The operational continuations were simple. We review the literature regarding epidemiology, classification, symptomatology and management of aneurysms of the renal artery.

Keywords: Rupture, aneurysm, renal artery, nephrectomy, surgery treatment.

Copyright © 2019: This is an open-access article distributed under the terms of the Creative Commons Attribution license which permits unrestricted use, distribution, and reproduction in any medium for non-commercial use (Non-Commercial, or CC-BY-NC) provided the original author and source are credited.

INTRODUCTION

Renal artery aneurysm is a rare clinical entity that can be congenital or acquired, having an incidence of 0.1% on the whole of the general population [1]. The scanographic serie bring back an incidence which amount to 3% [2]. It touches the subject of 4th and 5th decade with a female predominance. Although rare, the risk of aneurysm rupture is fatal with a mortality that can amount to 80% of cases [5]. Despite advances in endovascular treatment, surgery remains the real choice [2, 6].

OBSERVATION

MR IS is a man of 50 years without any notable history, consults for right lumbar pain that has been evolving for 4 days without urinary disorders, the examination notes a cutaneo-mucous pallor, a state of haemorrhagic shock, a polypnea, a painful hard mass of 15 cm long axis occupying the entire right hemi-abdomen, giving the lumbar contact, no lumbar breath noted, biology notes anemia at 10g / dl, hepatic hemostasis and renal assessments are without abnormalities. On the X-ray of AUSP, calcifications on the projection of the renal artery. An ultrasound shows a retro-peritoneal hemorrhagic mass (Fig 1 & 2). CT scan revealed an aneurysm of the right renal artery,

fissured, thrombosed, hemorrhagic, pushing back the liver and compressing the poorly perfused right kidney forming a high-frequency retroperitoneal hematoma (Fig 3 & 4). The patient had received measurements of reanimation and prepared for emergency surgery. A subcostal right was performed, intraoperative exploration notes a saccular aneurysm of the right renal artery raising the inferior vena cava implanting itself to the trunk of the renal artery at 1 cm from its aortic origin. The aneurysm is fissured with active hemorrhage, a large retroperitoneal hematoma is noted, and the right kidney is atrophied and ischemic. Our conduct was to carry out a right nephrectomy, to ligate the right renal artery at its base and a resection of aneurysm with installation of drainage into retro-peritoneal (Fig 5 & 6). The postoperative course was simple. Drainage brought 170 ml of serohematic fluid and was removed in the 3th postoperative day. Pathological examination concluded to a renal infraction and thrombosed and perforated saccular aneurysm in the right renal artery. The patient was put outgoing in the 15th postoperative day and followed to the outpatient. The ethiological investigations did not give an issue to any notable cause. The medium-term evolution for the patient was without any incident.

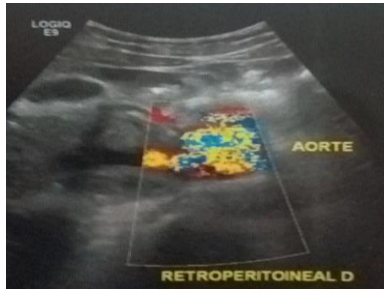


Fig-1: Dopler ultrasound view of an hemorrhagic saccular aneurysm of the renal artery

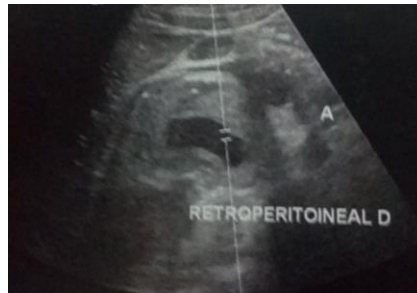

Fig-2: Ultra sound view of stenosed and hemorrhagic aneurysm with a retroperitoneal hematoma

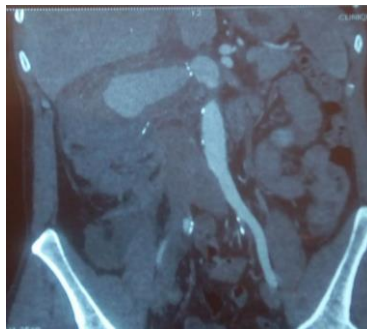


Fig-3: Frontal CT-scan view of a saccular aneurysm of the right renal artery with an important retroperitonéal hématoma raising up the liver and a poorly perfused right kidney

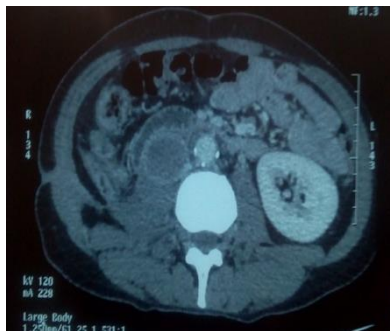


Fig-4: CT scan view of retroperitoneal hematoma with a right artery renal aneurysm

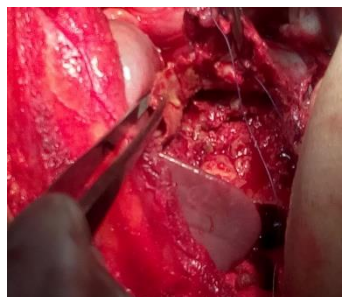


Fig-5: Peroperative exploration: endoluminal view of the aneurysm after partial resection and control of the hemorrhage

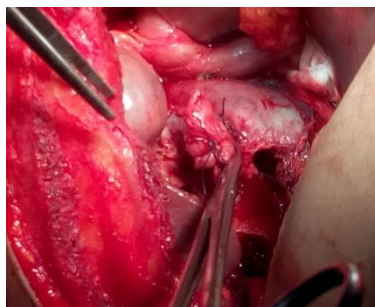


Fig-6: Subtotal resection of the aneurysm and ligation of the renal right artery at its base

DISCUSSION

The renal artery aneurysms are unilateral in 80% of cases and often occupy the right renal artery, these aneurysms are multiple in 30% of cases, and often sit on the trunk of the artery [1, 7, 9]. According to Poutasse there are 4 types of aneurysms whose most frequent are the saccular which are providers of rupture, the spindle-shaped which are providers of stenosis, the dissequant and the intra-renal [2, 9]. Aneurysms of the renal artery progress to either thrombosis or rupture [10]. The frequency of the latter amounts to 3% of the diagnosed aneurysms [11]. The rarity of the aneurysmal rupture makes the understanding of the natural history not established [11].

Nevertheless, some factors have been described as being involved in aneurysmal rupture such as pregnancy, arterial high blood pressure, character non-calcified of the aneurysm, aneurysmal size exceeding 1.5 cms and intra-renal location [12, 13]. The fibro-muscular dysplasia congenital disease is associated in 68% with renal artery aneurysms [1, 14-18]. The ruptured aneurysms have been described in certain pathologies such as Behçet's disease, Lupus and Marfan's syndrome [19, 20]. The renal artery aneurysms are symptomatic in 4 to 23% of the cases, they can be symptomatic of abdominal or lumbar pain, the notion of hematuria can be reported, the examination can note: arterial hypertension in 70% of the cases a lumbar breath, hypo-volumic shock, and abdominal mass can be perceived [21]. The association of an acute lumbar pain and a high blood pressure of brutal installation is evocative of aneurysmal rupture [4]. In emergency conditions such as our case, the renal ultrasound coupled with Doppler is essential to the diagnosis [22], it allows to visualize the sac, to explore the arterial trunk and to highlight a hematoma retro-peritoneal; the angio-CT identifies the lesions with strong anatomical precision and allows to eliminate the differential diagnosis of a tumoral mass or an arteriovenous fistula [22]. According to Dawn *et al.*, [21], the treatment of renal artery aneurysms is indicated when the aneurysm exceeds 2 cms, at the women in age of procreation, whith symptomatic aneurysms of pain or hematuria, for complicated aneurysms of rupture, dissection or thrombosis, and for aneurysms with refractory HTA [21]. In the case of aneurysmal rupture, the surgical processin is the rule, it

consists in an aneurysmal resection and in an arterial repairing surgery by an in-situ or ex-situ technique, so allowing to preserve the kidney [13]. The in-situ technique is indicated in saccular aneurysms, the ex-situ technique is recommended for difficult aneurysms or impossible to repair considering it offers a better exposure [8]. Restorative techniques are rarely indicated and require a technical control in order to repair complex aneurysms within clamping times which can exceed 45 minutes [23]. Nephrectomy is indicated in renal infarction, ischemic renal atrophy, and complex aneurysms [20]. In our case, a nephrectomy was carried out considering renal ischemia, the total resection of the aneurysm was impossible seen the relationship of it with the inferior vena cava which raises it for fear of traumatizing it, which obliged us to make a ligation of the renal artery in 1 cm from its aortic origin and in 0.5 cm upstream of the aneurysm.

CONCLUSION

The aneurysm of the renal artery is rarely symptomatic and often fortuitous discovery, its evolution is marked by rupture which is a rare but fatal complication. In case of rupture, a fast diagnosis is required by Doppler ultrasound or angio-CT. The processing of choice is the surgical treatment making renal preservation possible by arterial repair techniques. The main prognostic factor is early diagnosis.

REFERENCES

1. Martin III, R. S., Meacham, P. W., Ditesheim, J. A., Mulherin Jr, J. L., & Edwards, W. H. (1989). Renal artery aneurysm: selective treatment for hypertension and prevention of rupture. *Journal of vascular surgery*, 9(1), 26-34.
2. Stanley, J. C., Rhodes, E. L., Gewertz, B. L., Chang, C. Y., Walter, J. F., & Fry, W. J. (1975). Renal artery aneurysms: significance of macroaneurysms exclusive of dissections and fibrodysplastic mural dilations. *Archives of Surgery*, 110(11), 1327-1333.
3. Davaine, J. M., Tresson, P., Jayet, J., Couture, T., Lawton, J., Kashi, M., ... & Koskas, F. (2017). Anévrysmes de l'artère rénale. *JMV-Journal de Médecine Vasculaire*, 42(2), 89.
4. Mathieu, D., Abbou, C., Meunier, S., Larde, D., & Vasile, N. (1983). Primary dissecting aneurysm of the renal artery. *Urologic radiology*, 5(1), 17-21.

5. Faker, G. (2011). Anevrysme de l'artère rénale hilaire: A propos d'un cas. *La tunisie chirurgicale*, 21.
6. Toshino, A., Oka, A., Kitajima, K., Akiyama, K., Mitsuhata, N., Mannami, R., ... & Mannami, M. (1996). Ex vivo surgery for renal artery aneurysms. *International journal of urology*, 3(6), 421-425.
7. Henriksson, C., Björkerud, S., Nilson, A. E., & Pettersson, S. (1985). Natural history of renal artery aneurysm elucidated by repeated angiography and pathoanatomical studies. *European urology*, 11, 244-248.
8. Novick, A. C., Stewart, B. H., & Straffon, R. A. (1980). Extracorporeal surgery and autotransplantation: indications and techniques and results. *Journal of Urology*, 123, 806-811.
9. Tcherdakoff, P. H., Maillet, R., Ecoiffier, J., Vasse, J., & Milliez, P. (1971). Anévrysme de l'artère rénale chez les malades hypertendus: 42 cas. *Presse Med*, 79, 123-128.
10. Zubarev, A. V. (2001). Ultrasound of renal vessels. *Eur Radiol*, 11:1902-15MILLIEZ P.
11. Calligaro, K. D., & Dougherty, M. J. (2010). Renovascular disease: aneurysms and arteriovenous fistulae. In *Rutherford's vascular surgery* (p. 2329). WB Saunders, Philadelphia.
12. Nishikawa, N., Onishi, H., Kawase, N., & Fukuzawa, S. (2003). Rupture of renal artery aneurysm during pregnancy. *Hinyokika Kyo*, 49:103-106.
13. Njinou Ngninkeu, B., Eucher, P., Vandenbossche, P., Lacrosse, M., Van Cangh, P. J., & Lorge, F. (2002). Anévrysme rompu de l'artère rénale: une cause rare d'hématurie macroscopique. *Progrès en urologie: journal de l'Association française d'urologie et de la Société française d'urologie*, 12(3), 454-458.
14. Henke, P. K., Cardneau, J. D., Welling Iii, T. H., Upchurch Jr, G. R., Wakefield, T. W., Jacobs, L. A., ... & Stanley, J. C. (2001). Renal artery aneurysms: a 35-year clinical experience with 252 aneurysms in 168 patients. *Annals of surgery*, 234(4), 454.
15. Klausner, J. Q., Harlander-Locke, M. P., Plotnik, A. N., Lehrman, E., DeRubertis, B. G., & Lawrence, P. F. (2014). Current treatment of renal artery aneurysms may be too aggressive. *Journal of vascular surgery*, 59(5), 1356-1361.
16. Pfeiffer, T., Reiher, L., Grabitz, K., Grünhage, B., Häfele, S., Voiculescu, A., ... & Sandmann, W. (2003). Reconstruction for renal artery aneurysm: operative techniques and long-term results. *Journal of vascular surgery*, 37(2), 293-300.
17. Tsilimparis, N., Reeves, J. G., Dayama, A., Perez, S. D., Debus, E. S., & Ricotta II, J. J. (2013). Endovascular vs open repair of renal artery aneurysms: outcomes of repair and long-term renal function. *Journal of the American College of Surgeons*, 217(2), 263-269.
18. Hupp, T., Allenberg, J. R., Post, K., Roeren, T., Meier, M., & Clorius, J. H. (1992). Renal artery aneurysm: surgical indications and results. *European journal of vascular surgery*, 6(5), 477-486.
19. Kurz, S., Holder, M., Laberke, H. G., & Bastanier, C. K. (1992). Rupture of a renal artery aneurysm. Fulminated course, fatal complication of type IV Ehlers-Danlos syndrome in childhood. *Monatsschr Kinderheilkd*, 140:624-628.
20. Kumamoto, H., Kagebayashi, Y., Mibu, H., Hayashi, Y., Ozono, S., & Hirao, Y. (2002). Spontaneous rupture of a left renal artery aneurysm: a case report. *Hinyokika kyo. Acta urologica Japonica*, 48(2), 81-83.
21. Coleman, D. M., & Stanley, J. C. (2015). Renal artery aneurysms. *Journal of vascular surgery*, 62(3), 779-785.
22. Chow, K., Mahadanaarachchi, J., Baird, A., Rowlands, P., & Cornford, P. A. (2002). Massive peri-renal haemorrhage from ruptured renal artery aneurysm in the presence of normal renal function. *Scandinavian journal of urology and nephrology*, 36(5), 389-390.
23. Dean, R. H., Meacham, P. W., & Weaver, F. A. (1986). Ex vivo renal artery reconstructions: indications and techniques. *Journal of vascular surgery*, 4(6), 546-552.