

A Clinicopathological Profile of Vocal Cord Polyps in India

Saileswar Goswami^{1*}, Shivaam Kesarwaani², Dipankar Kumar Basumata²

¹Associate Professor, Department of E.N.T, Calcutta National Medical College, Kolkata, West Bengal, India

²Post Graduate Trainee, Department of E.N.T, Calcutta National Medical College, Kolkata, West Bengal, India

*Corresponding author

Saileswar Goswami

Article History

Received: 03.05.2018

Accepted: 13.05.2018

Published: 30.05.2018

DOI:

10.36348/sjm.2018.v03i05.002



Abstract: An analysis of 129 cases of vocal cord polyps was done in this study. It was most often seen in middle aged persons during third, fourth, and fifth decades of life. Maximum incidence was in the 5th decade. The youngest of the patient was 26 years of age and the oldest was of 45 years, with the mean age of 36 years. Vocal cord polyps were found predominantly in males (86%), with a male and female ratio of 6.1:1. In all 129 cases, the lesions were unilateral and mostly situated in the middle of the vocal cords. Smoking (68.2%), vocal abuse or misuse (62.8%), and chronic respiratory tract infection (30.2%) were the main aetiological factors. There were no dysplastic changes in the epithelium. The treatment options for vocal cord polyps included both non-invasive and invasive techniques. Non-invasive techniques included conservative therapy with voice rest, steam inhalation, antiallergics, antibiotics, and antireflux drugs. Conservative treatment was considered as an option in vocal cord polyps which were small and of recent onset. Invasive technique was a combination of surgery and vocal rehabilitation. Conventional microlaryngeal surgery was ideal for the treatment of vocal cord polyps. In 82 cases (63.6%), the histopathological picture was of fibroangioma and in other 47 cases (36.4%) the picture was of chronic nonspecific inflammation with oedema. There were recurrences in 18 cases within one year of surgery. Operating measures did not prevent recurrences of vocal cord polyps. Recurrences were significantly less in the patients who stopped smoking and misusing or abusing their voices after surgery. Voice therapy and cessation of smoking in the postoperative period played important roles in the long term results of vocal cord polyps. Better outcome and rapid improvement were observed in those patients who underwent voice therapy in follow ups.

Keywords: vocal cord polyp, hoarseness, vocal abuse, vocal rehabilitation, microlaryngoscopy.

INTRODUCTION

The vocal cord or vocal fold is an amazing structure. It can withstand significant degree of stress and strain. However, chronic misuse of voice may lead to the formation of vocal nodules, vocal cord polyps or Reinke's oedema.

Polyps are defined as the product of inflammation. It may be due to allergy, infection or trauma. Most of the vocal cord polyps are situated in the middle of the vocal cord, which is the place where maximum muscular force and aerodynamic force hit one another during phonation. The main aetiological factor has not yet been identified. But in most of the cases, the history of misuse of voice is present. So vocal cord polyp is thought to be the product of phonotrauma. Misuse of voice does not mean excessive use of voice but the manner in which the voice is produced. Polyps are found in patients who use their voices in a shrill or strident way with unnecessary tension.

Benign vocal fold mucosal lesions seem to be caused primarily by vibratory trauma. Occupational and lifestyle vocal demands are the primary risk factors along with excessive talkativeness. Smoking, gastroesophageal reflux, allergy, and infection also increase the vulnerability of vocal fold mucosa to vibratory trauma, leading to injury. Non-singers with benign vocal fold mucosal disorders present with the complaint of change in voice. A singer with normal conversational voice may seek professional evaluation because of singing voice limitations, usually in the upper range. More than 90% of the patients [1] with voice complaints have benign vocal fold disorders.

A true vocal cord polyp is a benign swelling greater than 3 mm in diameter, that arises from the free edge of the vocal cord [2]. Vocal cord polyps present in an array of sizes, shapes and compositions. A vocal cord polyp is covered with stratified squamous epithelium and may exhibit a variety of changes in the stroma, which include oedema, fibrosis, increased vascularity, haemorrhages and hyaline changes. Thus,

on the basis of histological changes, vocal cord polyps are divided into gelatinous polyps, fibrous polyps, and telangiectatic polyps [3].

Vocal cord polyps are fairly common and comprise of about 41% of benign laryngeal pathologies [4]. In this study, an attempt has been made to go into the aetio-pathogenesis of this common benign lesion.

MATERIALS AND METHODS

This study was conducted in three Medical Colleges of West Bengal, India, over a period of 30 years. The subjects of this study were selected from the patients presenting with hoarseness of voice in the E.N.T. outpatient department of those hospitals. All the patients were examined and only the cases with hoarseness of voice for more than 15 days were selected. The patients presenting with other voice disorders were excluded from this study. The patients with hoarseness of voice for less than 15 days were also excluded. During the initial phase of our study, only indirect laryngoscopy were done in all cases. This was later combined with fibre optic laryngoscopy upon availability of the instruments required.

A detailed history was taken in all cases with special importance to age, sex, occupation, complaints with duration, and any predisposing factors. The onset and the progress of the symptoms were noted. Past history of such episodes and other illnesses and history

of previous treatment were taken. Thyroid function tests were done in patients who had experienced a significant weight gain or had no identifiable irritant. Routine haematological assessment and biochemical estimation of blood sugar, blood urea and routine examination of urine were carried out in all patients except a few. X-ray chest and x-ray soft tissue of neck were done where necessary.

Selected cases were admitted and conventional direct laryngoscopy or microlaryngoscopy was done under general anaesthesia. Microlaryngoscopy was done using a Zeiss operating microscope fitted with a 400 mm objective lens. Necessary surgery was done and the tissue was sent for histopathological examination. After the surgery, absolute voice rest was advocated for two weeks. Voice therapy was started after 2 to 3 weeks and was continued as long as it was felt to be beneficial.

RESULTS AND DISCUSSION

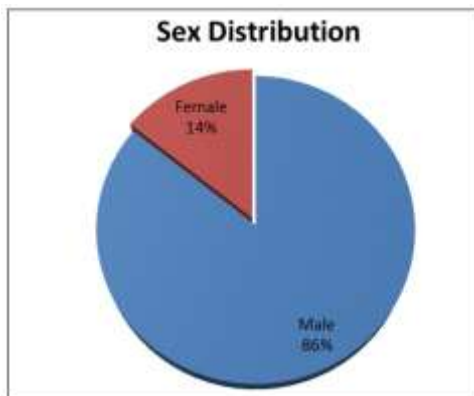
In our study comprising of 765 patients presenting with hoarseness, 129 were found to be suffering from vocal cord polyps. The youngest of the patient was 26 years of age and the oldest was of 45 years with the mean age of 36 years. Vocal cord polyps were found predominantly in males, during third, fourth, and fifth decades of life. Maximum incidence was in the 5th decade.

Table-1: Age Distribution of Patients

Age groups	Number of cases	Percentage (%)
21-30 years	41	31.8%
31-40 years	29	22.5%
41-50 years	59	45.7%
Total	129	100%

Out of the 129 patients, 111 (86%) were males and 18 (14%) were females and the male female ratio was 6.1:1. Singh R *et al.*, [5] found male predominance with a male, female ratio of 2:1 in vocal cord polyp cases. Singhal *et al.*, [6] found its highest incidence in the 3rd decade of life and a male female ratio of 3.7:1. Kleinsasser [7] in his series of 900 vocal cord polyps found that 76 % of the patients were males and 24 % were females. Most of the patients were between 30 and 50 years of age. The average age of the men was 40 years and the women was 38 years. None of the patients

were younger than 20 years of age. Salmon [8] in his study found that vocal cord polyps were the most common benign lesions of the larynx. It was rare in very young and very old and most commonly found in the 5th decade of life. It was found predominantly in men. Male female ratio was 2:1. Epstein *et al.*, [9] in their series of 155 cases, found 147 cases of unilateral and 8 cases of bilateral vocal cord polyps. The peak age of incidence was 40 to 50 years. Bastian *et al.*, [10], Nagata *et al.*, [11] and Singh M *et al.*, [4] also found a male predominance among vocal cord polyp cases.



It was seen in our study that out of 129 patients of vocal cord polyps, 88 (68.2%) patients were smokers. Effat & Milad [12] in their study also made similar observations. They also stated that vocal cord polyps were larger in smokers than in non-smokers. Kleinsasser [7] in his series found that 80 to 90% of the patients were smokers.

We found that in all the 129 cases, the lesions were unilateral. Singh M *et al.*, [4] in their study noted 94 % of the cases of vocal cord polyps to be unilateral. Kleinsasser [7] found that 10% of the polyps were multiple and bilateral whereas 5% were multiple and unilateral.

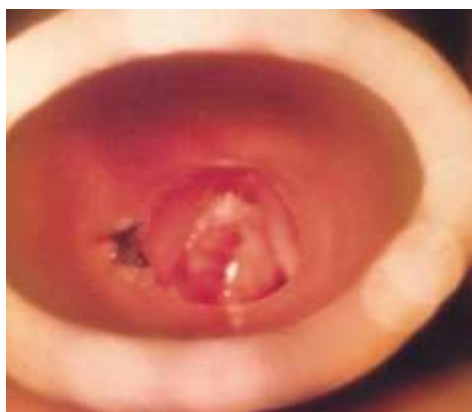

Fig-1: Microlaryngoscopic photograph showing a large polyp, slightly reddish in colour, arising from the left vocal cord with a stalk. Histological picture was of angiofibroma

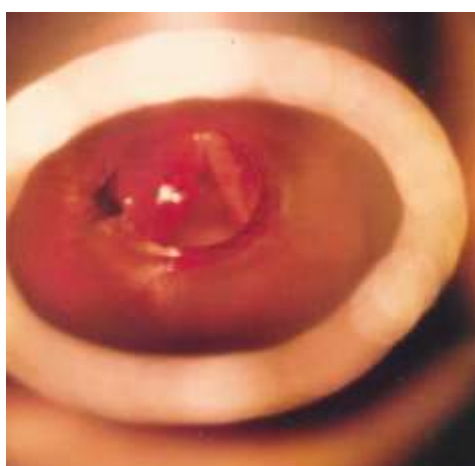


Fig-2: Microlaryngoscopic photograph of the vocal cord polyp shown in Fig-1, following surgery

In 81 (62.8%) cases out of 129, vocal misuse or abuse were present. Chronic respiratory tract infection were present in 39 (30.2%) cases. Many of them reported that they had used or abused their voices

professionally or habitually. In most of the cases, the lesions were situated in the middle of the vocal cords. This could be attributed to the fact that shearing and collision forces on the superficial lamina propria were

greatest in this region. Kleinsasser [7] and Ballenger [13] also stated that misuse or abuse of voice might be considered as one of the main aetiological factors.

The polyps were reddish or greyish in color, arising from a stalk or a broad base in some cases. In 17 cases, there were dilated blood vessels over the polyps. The size of the polyps varied from 3mm to 10 mm in diameter. In all the cases, vocal cords were mobile. Hoarseness improved markedly after excision of the polyps.

In 82 cases (63.6%), the histopathological picture was of fibroangioma and in other 47 cases (36.4%) the picture was of chronic nonspecific

inflammation with oedema. Similar observations were made by Singh M *et al.*, [4] in their study, in which they found 76% angiomatous polyp, 18% inflammatory polyp and 6% chronic laryngitis cases.

We observed that sometimes it was difficult to differentiate Reinke's oedema from a gelatinous polyp of the vocal cord. The oedema fluid was usually serous but in case of long standing Reinke's oedema, the viscosity of the oedematous fluid increased and it became jelly like. Not only did they look alike on indirect laryngoscopy but also on microlaryngoscopy. The histological picture helped in those cases. Goswami *et al.*, [14] had made similar observation in their study.

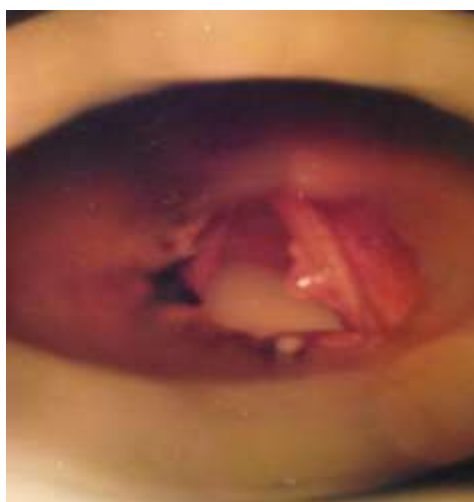


Fig-3: Microlaryngoscopic photograph showing an oedematous polyp arising from the right vocal cord with a broad base

The treatment option for vocal cord polyps included both non invasive and invasive techniques [15]. Non-invasive techniques included conservative therapy with voice rest, steam inhalation, antiallergics, antibiotics and antireflux drugs. A total of 15 cases, who had recent onset and small vocal cord polyps, were subjected to conservative treatment for at least 3 months with close follow-ups. Out of those 15 patients, 6 (40%) patients had complete resolution, while the rest 8 (60%) cases had clinically significant reduction in size within a mean duration of 5 months. Klein *et al.*, [16] found that polyps that eventually resolved, did so within 9 months, which was in corroboration with our findings.

Invasive technique was a combination of surgery and vocal rehabilitation. All known causative factors should first be eliminated. Most of the patients were treated by microlaryngoscopic surgery and voice therapy during follow-ups. Healing was usually rapid and new epithelium developed with a firmer attachment to the underlying muscle, which prevented recurrence. We observed better outcome and rapid improvement in those patients who underwent voice therapy in follow-ups than those who did not undergo it.

Similar observations were made by LILIN *et al.*, [17] in their study, where they demonstrated from the subjective and objective data of the two groups before and after surgery, that the vocal rehabilitation effect following surgery in the patients of the training group was better than that of the control group and the difference was statistically significant ($P < 0.05$). Cohen *et al.*, [18] presented one of the earliest studies reporting the utility of voice therapy as the first line of treatment for vocal cord polyps. However, their report comprised of both cysts and polyps and reported only the improvement of symptoms.

More recent large case series [19, 20] focused on the utility of voice therapy as the main treatment strategy. The primary end point of the series mentioned, was improvement in voice quality. In our series, we chose complete resolution of the vocal cord polyps as the significant end point.

A recent review article by Garrett and Francis [21] stated that voice therapy may or may not be important in the conservative approach for treating vocal cord polyps. However, the role of voice therapy

and vocal hygiene in any voice related condition should not be overlooked. Hence, the role of voice therapy in the conservative management of vocal cord polyps needs more attention with regard to study researches.

In our study, the patients were followed up for one year after surgery. Wang *et al.*, [22] gave importance to the education regarding proper vocal hygiene and hydration and avoidance of vocal abuse, misuse, and overuse as necessary baseline instructions.

There were recurrences in 18 cases within one year of surgery. Recurrences were significantly less in the patients who stopped smoking and misusing or abusing their voices after surgery. Hojslet *et al.*, [23] also stated that if smoking was not stopped, the result of any treatment would be disappointing.

CONCLUSION

Vocal cord polyps were commonly found in middle aged persons and predominantly in males (86%). Smoking, vocal misuse or abuse, and recurrent respiratory tract infection were the main aetiological factors. Histopathological picture was of angiofibroma in most of the cases and nonspecific inflammation in other cases.

The treatment options for vocal cord polyps include both non-invasive and invasive techniques. Non-invasive techniques include conservative therapy with voice rest, steam inhalation, antiallergics, antibiotics and antireflux drugs. This should be considered as an treatment option in vocal cord polyps of recent onset and small size. Invasive technique is a combination of surgery and vocal rehabilitation. Conventional microlaryngeal surgery is ideal in the treatment of vocal cord polyps.

Vocal cord polyp is essentially a benign pathology. In some cases it may be difficult to differentiate vocal cord polyps from Reinke's oedema. It is not associated with any dysplastic changes in the epithelium. Operating measures do not prevent recurrences of vocal cord polyp. Voice therapy and cessation of smoking play important roles for long term treatment results of vocal cord polyp.

REFERENCES

1. Kiakojoury, K., Dehghan, M., Hajizade, F., & Khafri, S. (2014). Etiologies of dysphonia in patients referred to ENT clinics based on videolaryngoscopy. *Iranian journal of otorhinolaryngology*, 26(76), 169.
2. Wallis, L., Jackson-Menaldi, C., Holland, W., & Giraldo, A. (2004). Vocal fold nodule vs. vocal fold polyp: answer from surgical pathologist and voice pathologist point of view. *Journal of Voice*, 18(1), 125-129.
3. Kleinsasser, O. (1968). *Microlaryngoscopy and endolaryngeal microsurgery: Techniques and typical cases*. WB Saunders Co..
4. Singh, M., Bandyopadhyay, S., Gupta, S. C., & Rai, A. (2002). Benign laryngeal lesions—a clinicopathological study of eleven years and a case report of pleomorphic lipoma. *Indian journal of Otolaryngology and head and Neck Surgery*, 54(3), 242-245.
5. Singh, R., & Prinja, S. A Clinicopathological Study of Patients with Organic Dysphonia.
6. Singhal, P., Bhandari, A., Chouhan, M., Sharma, M. P., & Sharma, S. (2009). Benign tumors of the larynx: a clinical study of 50 cases. *Indian Journal of Otolaryngology and Head & Neck Surgery*, 61(1), 26-30.
7. Kleinsasser, O. (1982). Pathogenesis of vocal cord polyps. *Annals of Otolology, Rhinology & Laryngology*, 91(4), 378-381.
8. Pracy, R., Ballantyne, J., & Grove, J. (1979). Congenital diseases of the nose. *Scott-Brown's Diseases of ear nose and throat. fourth edition. London: Butterworths*, 73-81.
9. Epstein, S. S., Winston, P., Friedmann, I., & Ormerod, F. C. (1957). The vocal cord polyp. *The Journal of Laryngology & Otolology*, 71(10), 673-688.
10. Bastian, R. W., Keidar, A., & Verdolini-Marston, K. (1990). Simple vocal tasks for detecting vocal fold swelling. *Journal of Voice*, 4(2), 172-183.
11. Nagata, K., Kurita, S., Yasumoto, S., Maeda, T., Kawasaki, H., & Hirano, M. (1983). Vocal fold polyps and nodules. A 10-year review of 1,156 patients. *Auris Nasus Larynx*, 10, S27-S35.
12. Effat, K. G., & Milad, M. (2015). A comparative histopathological study of vocal fold polyps in smokers versus non-smokers. *The Journal of Laryngology & Otolology*, 129(5), 484-488.
13. Ballenger, J. J., & Cole, R. I. (1985). *Diseases of the Nose, Throat, Ear, Head, and Neck*.
14. Goswami, S., & Patra, T. K. (2003). A Clinico-pathological study of Reinke's oedema. *Indian Journal of otolaryngology and Head and Neck surgery*, 55(3), 160-165.
15. Nakagawa, H., Miyamoto, M., Kusuyama, T., Mori, Y., & Fukuda, H. (2012). Resolution of vocal fold polyps with conservative treatment. *Journal of Voice*, 26(3), e107-e110.
16. Klein, A. M., Lehmann, M., Hapner, E. R., & Johns, M. M. (2009). Spontaneous resolution of hemorrhagic polyps of the true vocal fold. *Journal of Voice*, 23(1), 132-135.
17. Lin, L., Sun, N., Yang, Q., Zhang, Y., Shen, J., Shi, L., ... & Sun, G. (2014). Effect of voice training in the voice rehabilitation of patients with vocal cord polyps after surgery. *Experimental and therapeutic medicine*, 7(4), 877-880.
18. Cohen, S. M., & Garrett, C. G. (2007). Utility of voice therapy in the management of vocal fold

- polyps and cysts. *Otolaryngology—Head and Neck Surgery*, 136(5), 742-746.
19. Yun, Y. S., Kim, M. B., & Son, Y. I. (2007). The effect of vocal hygiene education for patients with vocal polyp. *Otolaryngology—Head and Neck Surgery*, 137(4), 569-575.
 20. Cho, K. J., Nam, I. C., Hwang, Y. S., Shim, M. R., Park, J. O., Cho, J. H., ... & Sun, D. I. (2011). Analysis of factors influencing voice quality and therapeutic approaches in vocal polyp patients. *European Archives of Oto-Rhino-Laryngology*, 268(9), 1321-1327.
 21. Garrett, C. G., & Francis, D. O. (2014). Is surgery necessary for all vocal fold polyps?. *The Laryngoscope*, 124(2), 363-364.
 22. Wang, C. T., Liao, L. J., Lai, M. S., & Cheng, P. W. (2014). Comparison of benign lesion regression following vocal fold steroid injection and vocal hygiene education. *The Laryngoscope*, 124(2), 510-515.
 23. Højslet, P. E., Moesgaard-Nielsen, V., & Karlslose, M. (1990). Smoking cessation in chronic Reinke's oedema. *The Journal of Laryngology & Otology*, 104(8), 626-628.