

## Massive Tricuspid Insufficiency after Pacemaker Implantation

M. Malki\*, A. Lagziri, L. Oukerraj, I. Fellat, J. Zarzur, M. Cherti

Cardiology department B: CHU Ibn Sina – Rabat, Morocco

**\*Corresponding author***M. Malki***Article History***Received: 14.10.2018**Accepted: 23.10.2018**Published: 30.10.2018***DOI:**

10.36348/sjm.2018.v03i10.007



**Abstract:** Implantable cardiac devices, including defibrillators and pacemakers, may be the cause of tricuspid regurgitation (TR) or may worsen existing TR. Diagnosis by clinical exam and 2-dimensional echocardiography may be augmented by 3-dimensional echocardiography and/or computed tomography or cardiac magnetic resonance. The mechanism may be mechanical perforation or laceration of leaflets, scarring and restriction of leaflets, or asynchronized activation of the right ventricle. Pacemaker-related TR might cause severe right-sided heart failure. Percutaneous removal of PM and ICD leads is often performed in large specialty centers with significant experience, but carries with it significant and sometimes fatal risk. TR is usually treated by either surgical repair (usually consisting of ring annuloplasty) or by tricuspid replacement in some patients with advanced valvular disease.

**Keywords:** pacemaker lead, tricuspid insufficiency, Threedimensional echocardiography, extraction, annuloplasty.

**INTRODUCTION**

Patients who present with severe right heart failure out of proportion to left-sided heart disease present a diagnostic challenge because the etiology may be due to constrictive pericarditis, restrictive cardiomyopathy, or pulmonary vascular disease [1-5]. We recently have observed the occurrence of right heart failure due to tricuspid regurgitation resulting from a permanent pacemaker (PM) and implantable cardiac defibrillator (ICD) leads, entities that have not been well recognized.

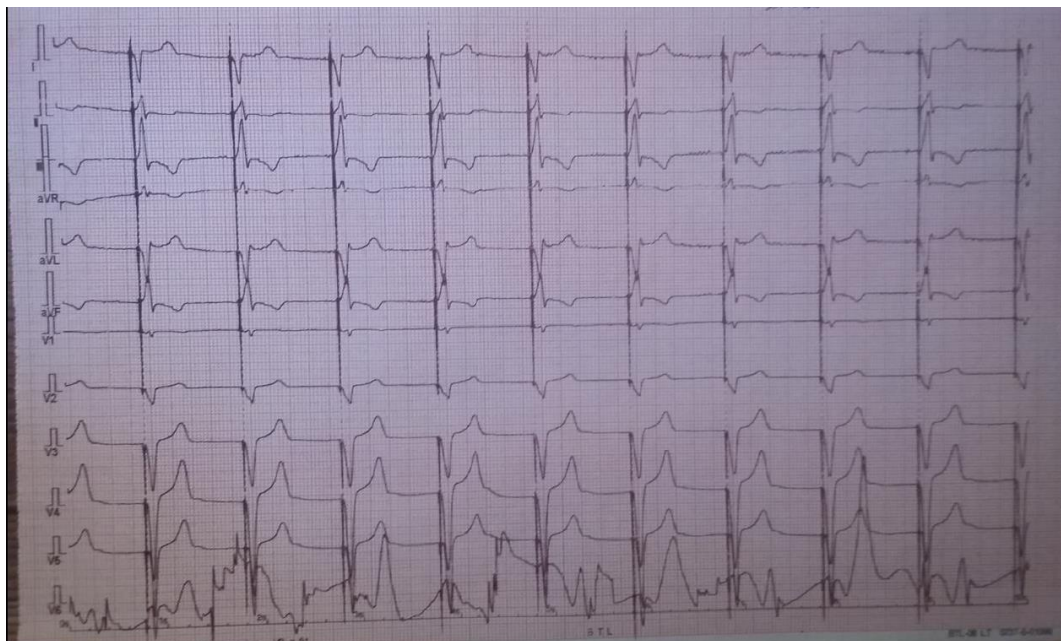We report the case of a 60 years old man presenting with right heart failure due to massive tricuspid insufficiency caused by pacemaker leads

**OBSERVATION**

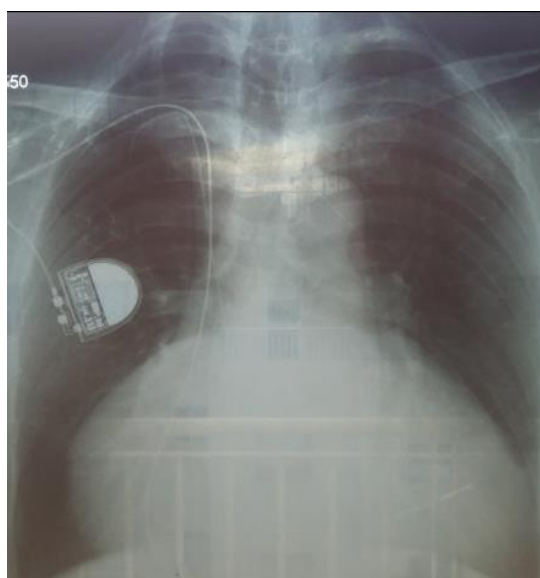
We report the case of a 60 years old patient with history of Emery Dreiffus disease complicated by an atrioventricular block implanted with a dual chamber pacemaker for 8 years, and having benefited two years ago from change of the ventricular lead because of a dysfunction. He was hospitalized for a chart of right heart failure including hepato-jugular reflux, jugular venous distension, peripheral edema and ascites, cardiac

exam objectived a tricuspid regurgitation murmur and right gallop without signs of left ventricular failure.

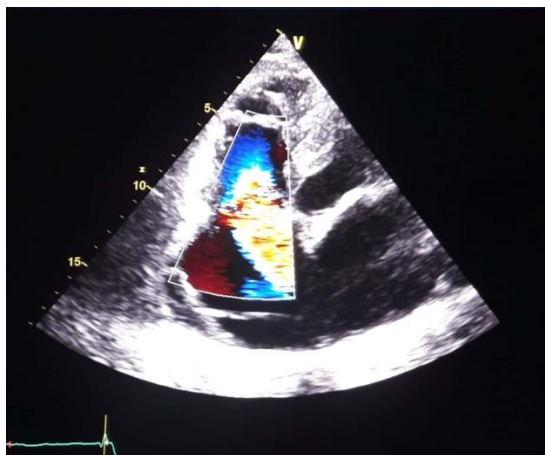The 12 lead ECG (Figure-1) showed paced rhythm with a rate of 60 beats per minute. Chest x-ray objectived large dilation of right cavities, pacemaker leads were well placed (Figure-2). The echocardiography showed a large dilation of the right cavities with a massive tricuspid insufficiency (Figure-3) due to the lack of coaptation of the valves. The patient was addressed in cardiac surgery department for tricuspid valve plasty and lead mobilization.



**Fig-1:** 12 lead ECG showing paced rhythm at 60 bpm



**Fig-2:** Chest X-ray showing a large dilation of the right cavities



**Fig-3:** Transthoracic echocardiography showing massive tricuspid insufficiency

## DISCUSSION

Tricuspid regurgitation is a common valvular lesion, the pathophysiology is divided into 2 major categories: functional (associated with left or right heart pathology) and structural (from primary leaflet abnormalities). Functional tricuspid regurgitation often results from left-sided heart valve disease [6]. The incidence of TR may be increasing in frequency coincident with the use of implanted cardiac devices, such as implantable cardiac defibrillators and permanent pacemakers. This association was first described by Gibson and colleagues in 1980 [7].

Tricuspid regurgitation after lead placement can occur via multiple mechanisms. It may be the result of mechanical causes such as scar formation or thrombus on the leads impairing closure. Perforation or laceration of valve leaflets is another cause of TR. Another mechanism is asynchrony, resulting from abnormal right ventricle (RV) activation from a pacemaker [13, 18].

Patients may present with clinical symptoms of right-sided congestive heart failure; however, many are asymptomatic even when TR is present. Physical examination may reveal the typical respirophasic systolic murmur at the left sternal border that increases with inspiration, but in many the murmur is unimpressive. Other physical exam findings typical of TR include hepatojugular reflux, jugular venous distension, peripheral edema and ascites [17].

Both 2-dimensional (2D) echocardiography and color Doppler flow mapping are essential in diagnosing TR. The severity is based on the direction and the size of the regurgitant jet, the presence of proximal flow convergence, and vena contracta width [8]

The PM lead may become entrapped in the thickened, fibrotic, and fused posterior and septal leaflets [9]. Threedimensional (3D) transthoracic echocardiography (TTE) may be useful in diagnosing lead-related TR, particularly in visualizing the short axis of the tricuspid valve, not obtainable with 2D echocardiography, which allows assessment of the route and the position of the lead within the tricuspid valve apparatus [9, 10, 11]. Unfortunately, due to the need for dedicated probes and image analysis software, as well as greater cost, 3D echocardiography is not as widely used currently. Another modality is cardiac magnetic resonance, which can be used to both detect and quantify TR based on regurgitant jet area and volume.

Medical treatment has been studied mostly in patients with functional TR, and includes treating the underlying cause and congestive heart failure management [6]. Chronically implanted leads may cause fibrosis and scar tissue formation, resulting in adherence to the tricuspid valve. Device-related

infection is the main cause for lead extraction [12]. Lead extraction has become both increasingly sophisticated and specialized. Sometimes leads can be removed by simple traction. Some patients require advanced techniques using stylets and laser-equipped sheaths [16]. Percutaneous removal of PM and ICD leads is often performed in large specialty centers with significant experience, but carries with it significant and sometimes fatal risk [11, 15]. TR is usually treated by either surgical repair (usually consisting of ring annuloplasty) or by tricuspid replacement in some patients with advanced valvular disease [14].

## CONCLUSION

Device-related TR is usually due to either mechanical mechanisms; perforation/laceration of leaflets, entrapment of leads resulting in scar tissue, or interference with valve coaptation; or physiological mechanisms; asynchronized activation of the RV from apex to base; mechanisms. When clinically significant, management typically involves percutaneous extraction of the offending leads. Larger, prospective, and well-controlled studies are needed to truly assess the incidence and timing of TR after lead implantation along with associated prognosis and mortality.

## REFERENCES

1. Kabbani, S. S., & LeWinter, M. M. (2000). Diastolic heart failure: constrictive, restrictive, and pericardial. *Cardiology clinics*, 18(3), 501-509.
2. Hancock, E. W. (2001). Differential diagnosis of restrictive cardiomyopathy and constrictive pericarditis. *Heart*, 86(3), 343-349.
3. Asher, C. R., & Klein, A. L. (2002). Diastolic heart failure: restrictive cardiomyopathy, constrictive pericarditis, and cardiac tamponade: clinical and echocardiographic evaluation. *Cardiology in review*, 10(4), 218-229.
4. Weitzenblum, E. (2003). Chronic cor pulmonale. *Heart*, 89(2), 225-230.
5. Runo, J. R., & Loyd, J. E. (2003). Primary pulmonary hypertension. *The lancet*, 361(9368), 1533-1544.
6. Agarwal, S., Tuzcu, E. M., Rodriguez, E. R., Tan, C. D., Rodriguez, L. L., & Kapadia, S. R. (2009). Interventional cardiology perspective of functional tricuspid regurgitation. *Circulation: Cardiovascular Interventions*, 2(6), 565-573.
7. Gibson, T. C., Davidson, R. C., & Desilvey, D. L. (1980). Presumptive tricuspid valve malfunction induced by a pacemaker lead: a case report and review of the literature. *Pacing and Clinical Electrophysiology*, 3(1), 88-94.
8. Rogers, J. H., & Bolling, S. F. (2009). The tricuspid valve: current perspective and evolving management of tricuspid regurgitation. *Circulation*, 119(20), 2718-2725.
9. Chen, T. E., Wang, C. C., Chern, M. S., & Chu, J. J. (2007). Entrapment of permanent pacemaker lead

- as the cause of tricuspid regurgitation. *Circulation Journal*, 71(7), 1169-1171.
10. Seo, Y., Ishizu, T., Nakajima, H., Sekiguchi, Y., Watanabe, S., & Aonuma, K. (2008). Clinical utility of 3-dimensional echocardiography in the evaluation of tricuspid regurgitation caused by pacemaker leads. *Circulation Journal*, 72(9), 1465-1470.
  11. Nucifora, G., Badano, L. P., Allocca, G., Gianfagna, P., Proclemer, A., Cinello, M., & Fioretti, P. M. (2007). Severe tricuspid regurgitation due to entrapment of the anterior leaflet of the valve by a permanent pacemaker lead: Role of real time three-dimensional echocardiography. *Echocardiography*, 24(6), 649-652.
  12. Rickard, J., & Wilkoff, B. L. (2011). Extraction of implantable cardiac electronic devices. *Current cardiology reports*, 13(5), 407.
  13. Kim, J. B., Spevack, D. M., Tunick, P. A., Bullinga, J. R., Kronzon, I., Chinitz, L. A., & Reynolds, H. R. (2008). The effect of transvenous pacemaker and implantable cardioverter defibrillator lead placement on tricuspid valve function: an observational study. *Journal of the American Society of Echocardiography*, 21(3), 284-287.
  14. McCarthy, P. M., Bhudia, S. K., Rajeswaran, J., Hoercher, K. J., Lytle, B. W., Cosgrove, D. M., & Blackstone, E. H. (2004). Tricuspid valve repair: durability and risk factors for failure. *The Journal of thoracic and cardiovascular surgery*, 127(3), 674-685.
  15. Rogers, J. H., & Bolling, S. F. (2009). The tricuspid valve: current perspective and evolving management of tricuspid regurgitation. *Circulation*, 119(20), 2718-2725.
  16. Rickard, J., & Wilkoff, B. L. (2011). Extraction of implantable cardiac electronic devices. *Current cardiology reports*, 13(5), 407.
  17. Loupy, A., Messika-Zeitoun, D., Cachier, A., Himbert, D., Brochet, E., Lung, B., & Vahanian, A. (2008). An unusual cause of pacemaker-induced severe tricuspid regurgitation. *European Journal of Echocardiography*, 9(1), 201-203.
  18. Krupa, W., Kozłowski, D., Derejko, P., & Świątecka, G. (2001). Permanent cardiac pacing and its influence on tricuspid valve function. *Folia morphologica*, 60(4), 249-258.