

Case Report

A perplexing fibro-osseous entity: Central ossifying fibroma of maxilla

Dr. Chintamaneni Raja Lakshmi¹, Dr. Ayesha Thabusum D², Dr. Sujana Mulk Bhavana³, Dr. Meka Poorna Venkata Prabhat⁴

¹Reader, Department Of Oral Medicine and Radiology, Drs Sudha and Nageswara Rao Siddhartha institute of dental sciences, Gannavaram Mandal, Krishna district, Andhra Pradesh, India.

²Assistant professor, Department Of Oral Medicine and Radiology, Drs Sudha and Nageswara Rao Siddhartha institute of dental sciences, Gannavaram Mandal, Krishna district, Andhra Pradesh, India.

³Assistant professor, Department Of Oral Medicine and Radiology, Drs Sudha and Nageswara Rao Siddhartha institute of dental sciences, Gannavaram Mandal, Krishna district, Andhra Pradesh, India.

⁴Professor and Head of the department, Department Of Oral Medicine And Radiology, Drs Sudha and Nageswara Rao Siddhartha institute of dental sciences, Gannavaram Mandal, Krishna district, Andhra Pradesh, India.

*Corresponding Author:

Dr. Chintamaneni Raja Lakshmi

Email: lakshmi.chintamaneni@yahoo.com

Abstract: Central ossifying fibroma is a rare slow growing destructive benign fibro-osseous tumor. It is typically found in craniofacial bones, frequently involving the mandible. The present case showed maxillary involvement, which is a very unique site of occurrence. It occurs more commonly in women in fourth decade of life. A correlation between clinical and radiographical and histopathological features is a key to establish diagnosis.

Keywords: Fibro –osseous lesion, Central ossifying fibroma (COF), Maxilla.

INTRODUCTION

Fibro - osseous lesions is a term used for diverse group of diseases that are characterized by replacement of normal bone tissue by fibrous tissue containing variable amount of mineralized material. Ossifying fibroma is one such benign fibro–osseous lesion seen more often in females in third to fourth decade of life. Usually it present as asymptomatic slow growing lesions commonly involving posterior mandible. Radiographically it appears as well circumscribed unilocular image with three phases of presentation. Initially as radiolucent, later as mixed lesion with radiolucent-radiopaque areas and the older lesions present as completely radiopaque lesion surrounded by radiolucent halo. Treatment constitutes curettage, surgical excision or enbloc resection depending on site and size of the lesion. The aim of presenting this case is to enlighten the clinician about the clinical, radiographic and microscopic features of central ossifying fibroma which helps for prompt diagnosis and better prognosis.

CASE REPORT

A 55yr old female patient reported with the complaint of swelling over the right cheek area for the past 8 months with gradual increase in its size from its onset. The swelling was asymptomatic and associated with difficulty in chewing. Patient also revealed that she

underwent extraction of her teeth at the site of swelling about one month back, despite the swelling persists.

Clinical examination revealed facial asymmetry due to swelling on the right side of the face measuring about 5x3cm seen extending superiorinferiorly from the line joining the ala tragus line to 2cm above the inferior border of the mandible and mediolaterally extending from the corner of the mouth to 2cm from the angle of the mandible (figure 1). Skin over the swelling showed normal colour with stretched contour. On palpation the swelling was non tender and hard in consistency. Intraoral examination revealed a solitary swelling involving right maxilla measuring 5x3cm, extending anteriorly from first premolar region to the maxillary tuberosity posteriorly causing obliteration of the buccal vestibule. The surface of the swelling was smooth and erythematous with no signs of discharge. On palpation the swelling was non tender and hard in consistency.

Patient was then subjected to evaluation of serum calcium, phosphorus and alkaline phosphatase levels along with routine haematological investigations. All the blood parameters found to be within the normal limits.

Radiological investigations include orthopantomograph and CT of maxilla.

Orthopantomograph showed a well defined radioopacity involving the right maxillary posterior region extending from first premolar to the maxillary tuberosity. Superiorly involving the floor of maxillary sinus and inferiorly involving the alveolar ridge with displacement of second molar distally and occlusally (figure 2). For better localization of the lesion advanced imaging CT is performed, Axial section revealed a well circumscribed expansile mass lesion involving right maxilla of size approximately 5.5cm x3.4cm seen extending anteroposteriorly from the first premolar to maxillary tuberosity with buccal cortical plate expansion. Internal structure depicted mixed radiographic image with variable amount of predominant radiopaque foci and radiolucent areas (figure 3a). Coronal section showed a tumor mass of right maxilla with mixed radiodensity, with upward bowing of floor of maxillary sinus, without any evidence of encroachment into surrounding vital structures (figure 3b) 3D CT representing tumor extension with buccal cortical expansion (figure 3c).

A provisional diagnosis of fibro-osseous lesion was made, and the differential diagnosis of fibrous dysplasia, odontogenic myxoma, cemento-ossifying fibroma was considered.

An incisional biopsy was performed from the site of the lesion. The histopathological report of the specimen revealed hypercellular connective tissue with areas of ossification and areas of woven bone with osteoblastic rimming and osteocytes in the lacunae at the centre (figure 4). Owing to the histopathological features and correlated with clinical and radiographic findings a final diagnosis of central ossifying fibroma of right maxilla was made

Under general anesthesia patient was operated and local infiltration with lignocaine 2% with adrenaline given on right posterior and anterior buccal vestibular region and the tumor site was exposed through incision line drawn from the vermilion border, along the philtrum of the lip, extending through the base of the nose and along the facial nasal groove. Mucoperiosteal flap was raised and the entire tumor was exposed and resection was done below zygomatic buttress anteriorly and 4mm away from the midpalatal raphe palatally. The whole tumor was removed along with the involved teeth. Surgical site was packed and flap enclosure done. Pack was removed after 36 hrs.

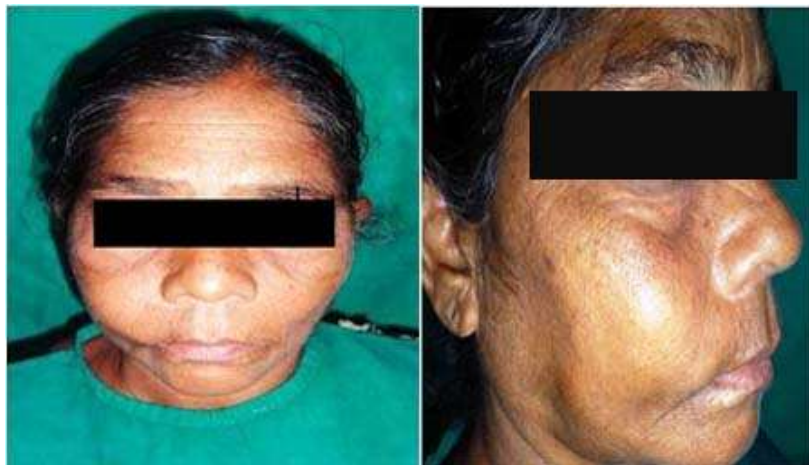

Fig-1: Extra oral picture showing lesion over right cheek. (Both frontal and lateral view)

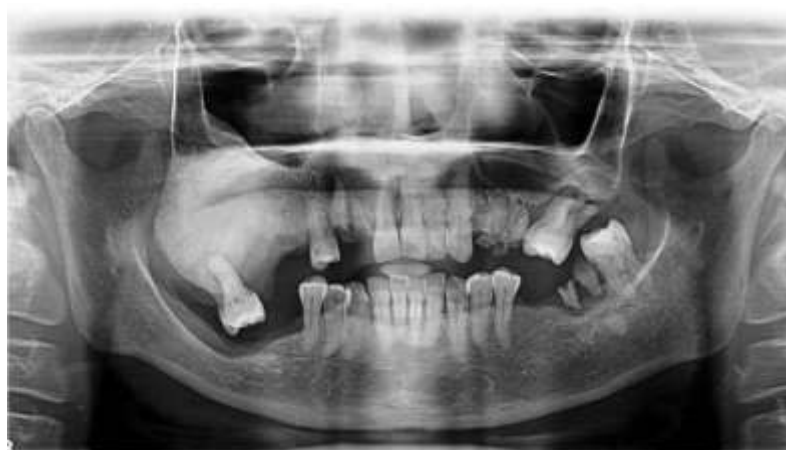

Fig-2: Orthopantomograph depicting the pathology in right maxilla

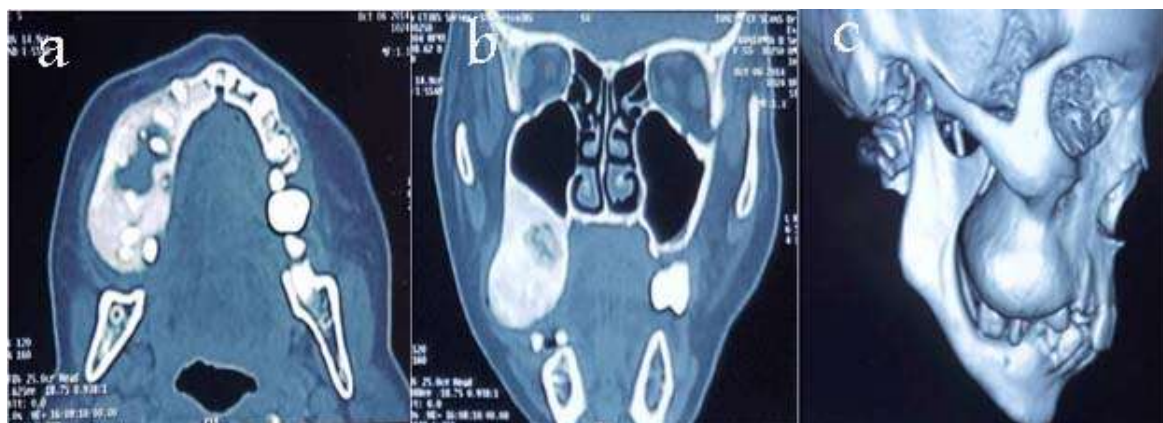


Fig-3: 4a: Axial section, 4b: Coronal section, 4c: Three dimension CT scan revealing the lesion extensions.

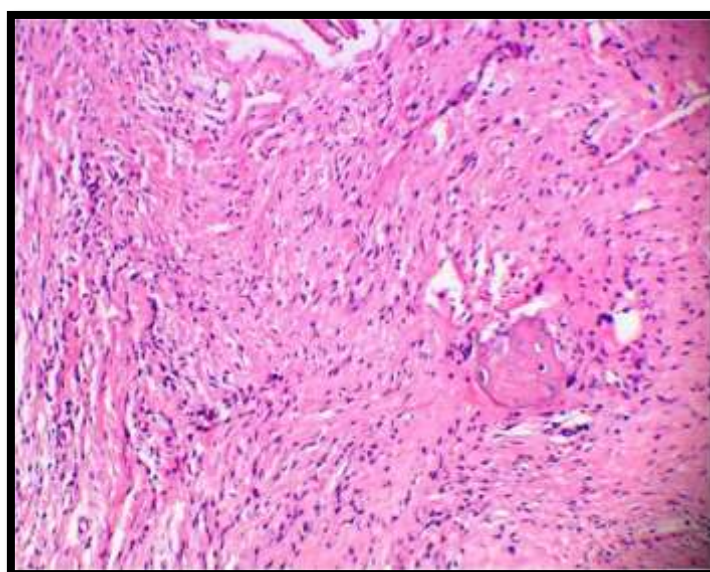


Fig-4: Microscopic features of central ossifying fibroma

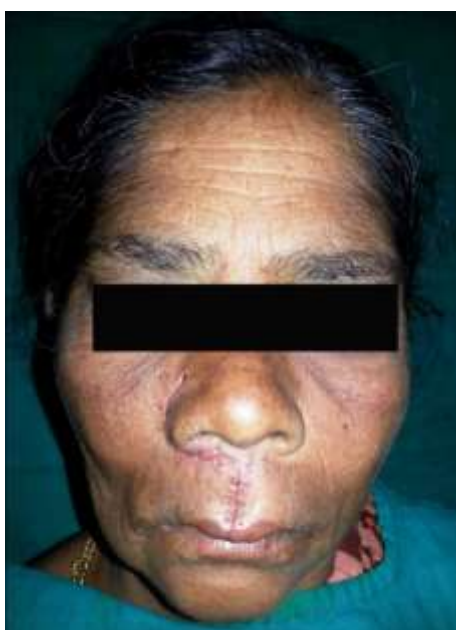

Fig-5: Post- treatment of the patient after surgery.

Out come and follow up: Patient was on monthly follow-up. Patient was last seen about 8 months after surgery with no evidence of recurrence.

DISCUSSION

Ossifying fibroma was first described by Menzel in 1872, later Montgomery in 1927 coined the term “ossifying fibroma” [1]. Two possible origins for ossifying process of this lesion is primarily by excessive proliferation of periodontal ligaments and secondarily by metaplastic process occurring in the connective tissue fibres [2]. According to WHO classification benign fibro-osseous lesions in the maxillofacial region were categorized as Osteogenic neoplasms and non – neoplastic bone lesions, Ossifying fibroma was considered as Osteogenic neoplasm [3]. Formerly this lesion was named as “Cementifying ossifying fibroma” and now it is termed as “Ossifying fibroma” according to new WHO classification in 2005 [4].

Previous reported cases of central ossifying fibromas were slow growing, asymptomatic, with swelling being the first clinical manifestation [5, 6] as seen in the current case. Many studies reported that commonest site of occurrence is posterior region of the mandible and very few cases have been reported in maxilla, as in the present case. Based on radiographic features MacDonald- Jankowski described three stages of central ossifying fibroma initial radiolucent stage, then a mixed stage, and finally radiopaque stage [5] Majority of them present as well defined mixed density lesions, with very few being completely radiolucent. Resorption of roots and divergence of associated teeth with loss of lamina dura may be noted [7] in the present case the lesion showed mixed radiodensity causing tooth displacement and loss of lamina dura.

Radiographically fibrous dysplasia is considered as main differential diagnosis of ossifying fibroma (OF). Fibrous dysplasia usually appears as diffuse homogenous ground glass radiodense lesion blending with the surrounding bone, where as ossifying fibroma shows well demarcated mixed radiolucent and radiopaque [8]. Among osseous dysplasias, early, intermediate and late stages of focal osseous dysplasia (FOD) could be considered in the differential diagnosis. Differentiating features of FOD from ossifying fibroma includes FOD mostly seen in patients during fourth and fifth decades of life, lesions smaller in size than OF and radiographically it presents with ill defined borders [9]. One additional important diagnostic feature of COF radiographically is that there is a centrifugal growth pattern expanding equally in all directions which produces a round tumor mass [10]. This characteristic presentation is evident in the present case.

Microscopically OF present as a cellular connective tissue with mineralized material and osteoblastic rimming seen on the surface of the

mineralized tissue. Similar picture is seen in this case [11]. Prado Ribeiro AC et al conducted a study and revealed histological differentiating feature for fibrous dysplasia from OF is the presence of peritrabecular clefting [12].

The management of central ossifying fibromas remains uncertain. Surgical curettage or enucleation with long term follow up is the line of treatment for small well circumscribed COFs, where as surgical resection is indicated for larger lesions. The prognosis however is very good and recurrence is rarely encountered. Eversole reported recurrence of 28% following curettage [13]. In our case surgical resection of the entire lesion was done with regular follow ups owing to its less recurrence.

In conclusion ossifying fibroma of the maxilla is an uncommon benign tumor with more female predilection. This tumor can present as a diagnostic dilemma owing to the overlapping features with other fibro-osseous lesions, so clinicians should be aware and correlate the clinical, radiographic and histological features of such lesions to provide better prognosis for the patient

REFERENCES

1. Binath, Ö., Erşahin, Y., Coşkun, S., & Bayol, Ü. (1995). Ossifying fibroma of the occipital bone. *Clinical neurology and neurosurgery*, 97(1), 47-49.
2. Ono, A., Tsukamoto, G., Nagatsuka, H., Yoshihama, Y., Rivera, R. S., Katsurano, M., ... & Sasaki, A. (2007). An immunohistochemical evaluation of BMP-2,-4, osteopontin, osteocalcin and PCNA between ossifying fibromas of the jaws and peripheral cemento-ossifying fibromas on the gingiva. *Oral oncology*, 43(4), 339-344.
3. Kramer, I. R. H., Pindborg, J. J., & Shear, M. (1992). Neoplasm and other lesions related to bone. *World Health Organization. Histologic typing of odontogenic tumors. Berlin. Springer-Verlag*, 28-31.
4. Reichart, P. A., Philipsen, H. P., & Sciubba, J. J. (2006). The new classification of Head and Neck Tumours (WHO)—any changes?. *Oral oncology*, 42(8), 757-758.
5. Chang, C. C., Hung, H. Y., Chang, J. Y. F., Yu, C. H., Wang, Y. P., Liu, B. Y., & Chiang, C. P. (2008). Central ossifying fibroma: a clinicopathologic study of 28 cases. *Journal of the Formosan Medical Association*, 107(4), 288-294.
6. Toro, C., Millesi, W., Zerman, N., Robiony, M., & Politi, M. (2006). A case of aggressive ossifying fibroma with massive involvement of the mandible: Differential diagnosis and management options. *International Journal of Pediatric Otorhinolaryngology Extra*, 1(2), 167-172.
7. MacDonald-Jankowski, D. S. (1998). Cemento-ossifying fibromas in the jaws of Hong Kong

- Chinese. *Dentomaxillofacial Radiology*, 27(5), 298-304.
8. McCarthy, E. F. (2013). Fibro-osseous lesions of the maxillofacial bones. *Head and neck pathology*, 7(1), 5-10.
 9. Su, L., Weathers, D. R., & Waldron, C. A. (1997). Distinguishing features of focal cemento-osseous dysplasia and cemento-ossifying fibromas: II. A clinical and radiologic spectrum of 316 cases. *Oral Surgery, Oral Medicine, Oral Pathology, Oral Radiology, and Endodontology*, 84(5), 540-549.
 10. Sarwar, H. G., Jindal, M. K., & Ahmad, S. S. (2008). Cemento-ossifying fibroma-a rare case. *Journal of Indian Society of Pedodontics and Preventive Dentistry*, 26(3), 128.
 11. Andrade, M. D., Silva-Sousa, Y. T. C., Marques, M. F. T., Pontual, M. L. D. A., Ramos-Perez, F. M. D. M., & Perez, D. E. D. C. (2013). Ossifying fibroma of the jaws: a clinicopathological case series study. *Brazilian dental journal*, 24(6), 662-666.
 12. Ribeiro, A. C. P., Carlos, R., Speight, P. M., Hunter, K. D., Santos-Silva, A. R., de Almeida, O. P., & Vargas, P. A. (2012). Peritrabecular clefting in fibrous dysplasia of the jaws: an important histopathologic feature for differentiating fibrous dysplasia from central ossifying fibroma. *Oral surgery, oral medicine, oral pathology and oral radiology*, 114(4), 503-508.
 13. Bal Reddy, P., Reddy, S., Prasad, N., Kiran, G., & Patlolla, K. (2012). Central Ossifying Fibroma of the Mandible: An Unusual Case Report. *J Clin Diag Res*, 6(3), 539-41.