

## Multiple Esophageal Leiomyomas: Case Report

Soumaya Jellal<sup>1\*</sup>, Mouna Salihoun<sup>1</sup>, Mohamed Acharki<sup>1</sup>, Nawal Kabbaj<sup>1</sup>

<sup>1</sup>EFD-Hepatogastroenterology Unit, Ibn Sina Hospital, Mohammed V University, Rabat, Morocco

DOI: [10.36348/sjmps.2023.v09i06.002](https://doi.org/10.36348/sjmps.2023.v09i06.002)

| Received: 22.04.2023 | Accepted: 25.05.2023 | Published: 03.06.2023

\*Corresponding author: Soumaya Jellal

EFD-Hepatogastroenterology Unit, Ibn Sina Hospital, Mohammed V University, Rabat, Morocco

### Abstract

Esophageal leiomyoma is uncommon. It is the most common benign tumor of the esophagus accounting for 0.4% of esophageal neoplasms and approximately two-thirds of benign esophageal tumors. About 90% of them are reported to be solitary and intramural lesions, and multiple or diffuse lesions seem to be very rare. We report the observation of a 75 years old male patient who was evaluated for chronic epigastric pain, Physical examination findings were typically normal, the patient underwent upper GI endoscopy. In esophagus, many submucosal tumor covered with intact mucosa, varying between 5mm and 20mm in size and located in the middle and lower part of oesophagus were noted. The radial endoscopic ultrasonography showed multiple (>10 masses), homogenous hypoechoic masses with clear margins, originated from the submucosa layer with normal surrounding structures, located in the middle and lower part of the oesophagus, and their size was < 2 cm, these lesions are followed periodically as they have a slow growth rate and negligible risk of malignant transformation. Multiple esophageal leiomyomas seems to be very rare, EUS is a valuable technique for the diagnosis of the disease and for making treatment decisions.

**Keywords:** Esophageal leiomyoma, tumor, homogenous hypoechoic masses, oesophagus.

**Copyright © 2023 The Author(s):** This is an open-access article distributed under the terms of the Creative Commons Attribution 4.0 International License (CC BY-NC 4.0) which permits unrestricted use, distribution, and reproduction in any medium for non-commercial use provided the original author and source are credited.

### INTRODUCTION

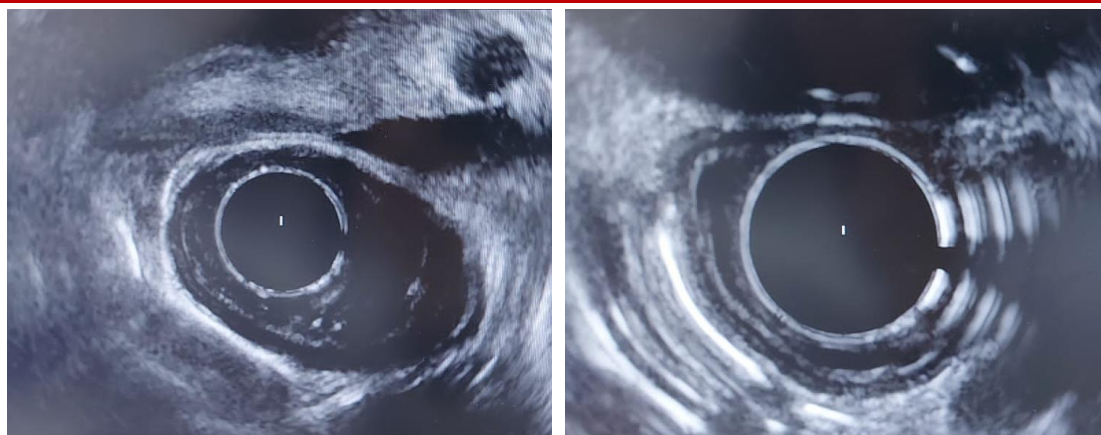
Although esophageal leiomyoma is rare, it's the most common benign submucosal mesenchymal tumor (SMT) of the esophagus, originates from the cells of the smooth muscle, accounting for 0.4% of esophageal neoplasms and approximately two-thirds of benign esophageal tumors [1]. It almost appears as a single tumor, and multiple leiomyomas of the esophagus are extremely rare, accounting for 2.4% of cases according to previous reports [2, 3].

Since esophageal leiomyoma is generally a slow-growing tumor and the size of the tumor may not change for many years, most affected patients are asymptomatic [4]. Often, a diagnosis of esophageal leiomyoma is made as an incidental finding during routine investigation or screening for upper gastrointestinal (GI) pathology [5]. Endoscopic ultrasonography (EUS) and computerized tomography (CT) are used for the diagnosis of leiomyoma. The mainstay treatment depends on symptoms and those >

5cm, esophagectomy or enucleation are recommended as the standard treatment in symptomatic patients. In this article, we report the observation of a multiple esophageal leiomyomas.

### CASE PRESENTATION

A 75 years old male patient was evaluated for chronic epigastric pain, Physical examination findings were typically normal, the patient underwent upper GI endoscopy. In esophagus, many submucosal tumor covered with intact mucosa, varying between 5mm and 20mm in size and located in the middle and lower part of oesophagus were noted. The radial endoscopic ultrasonography showed multiple (>10 masses), homogenous hypoechoic masses with clear margins, originated from the submucosa layer with normal surrounding structures, located in the middle and lower part of the oesophagus, and their size was < 2 cm, these lesions are followed periodically as they have a slow growth rate and negligible risk of malignant transformation (Figure 1).



**Figure 1: Radial EUS showing multiple hypoechoic masses with clear margins, originated from the submucosa layer with normal surrounding structures, located in the middle and lower part of the oesophagus, and their size was < 2 cm.**

## DISCUSSION

Esophageal leiomyoma is uncommon. It is the most common benign tumor of the esophagus accounting for 0.4% of esophageal neoplasms and approximately two-thirds of benign esophageal tumors [1]. About 90% of them are reported to be solitary and intramural lesions, and multiple or diffuse lesions seem to be very rare [2,3]. These tumors originate from the smooth muscle in the muscular layer of the esophagus. They are located mainly in the middle to distal esophagus and are uncommon in the upper third of the esophagus where the muscular layer consists of predominantly skeletal muscle. Incidences of 10%, 40%, and 50% have been reported in the upper, middle, and lower thirds of the esophagus, respectively. Leiomyomas are mostly single tumors. Multiple tumors, usually composed of <5 tumors, were detected in 2.4% of reported cases [7]. Furthermore, multiple leiomyoma is difficult to differentiate from diffuse esophageal leiomyomatosis.

Fernandes *et al.* [8] classified diffuse esophageal leiomyomatosis into 2 types. The first type was described as a condition involving a diffuse thickening of the esophageal musculature without any discrete lesion that may be associated with hereditary visceral leiomyomatosis (dominant inherited) and Alport syndrome (eye abnormalities, sensorineural hearing loss, myopia, and nephropathy: X-linked AS) [10]. The diagnosis of diffuse leiomyomatosis type I includes the clinical features of multiple-site tumors as well as genetic testing for Alport syndrome or type IV collagen mutation (COL4A5 gene) [9]. The presentation of this type is associated with progressive dysphagia, and both of its radiologic imaging and esophageal manometry findings mimic those of achalasia. In terms of the second type, the lesion consists of many confluent leiomyoma nodules surrounding the esophageal lumen [7]. Here, we report a case of multiple esophageal leiomyoma without clinical syndrome of diffuse esophageal leiomyomatosis.

The majority of patients with esophageal leiomyoma remain asymptomatic, and a very few patients go with epigastric discomfort, dysphagia or other symptoms, which were not specific for the disease. Most cases of the esophageal lesions were found by accident when patients received upper conventional endoscopy for other diseases. Symptoms seems to be present when the tumor has grown >5 cm, regardless of the number of tumors, and usually when it is an intraluminal rather than an intramural growth. In our case, the patient was asymptomatic which can be explain by the size of tumors <5 cm.

In the past, conventional endoscopy and CT scans were often used to detect esophageal lesions. More than half of the lesions grow from the muscularis mucosa. Conventional endoscopy can easily detect superficial lesions, but it cannot evaluate origination, growth direction and some other characteristics. In addition, approximately 40% of esophageal leiomyomas originate from the muscularis propria, which may increase the difficulty of diagnosis and biopsy. All these situations make it very hard to differentiate esophageal leiomyomas from other analogous lesions.

Endoscopic ultrasonography (EUS) can clearly reveal the five-layered structure of the esophageal wall and could also confirm the nature, size, number, origin of the lesions and their relationship with the surrounding organs. With these information EUS is now an effective method of the diagnosis of esophageal leiomyomas and able to make a distinction between esophageal leiomyoma and other submucosal lesions or external pressure neoplasms, such as inflammatory nodule, hemangioma, intravenous nodule, lipoma and cyst [13].

According to the European Society of Gastrointestinal Endoscopy (ESGE) clinical guidelines [15], EUS-guided FNA is indicated when there is a presumptive diagnosis of unresectable GIST for which

treatment with tyrosine kinase inhibitors is contemplated, in patients with previous history of malignancy to rule out metastasis, and when lymphoma is diagnosed, neuroendocrine tumors or extrinsic tumor is suspected (based on EUS, biological, or clinical criteria). On the other hand, the authors recommended against FNA if surgical excision is considered, or in case of the presence of the typical echo features of a lipoma, and in small (<2 cm) submucosal tumors (SMTs) of the esophagus and the stomach. Moreover, the clinical benefit from sampling of larger lesions in affecting the ultimate management was questioned.

EUS is a scientific and reasonable technique for making treatment decisions of the patients with esophageal leiomyoma. If the lesion originates from the muscularis mucosa or submucosa, endoscopic resection is preferred. However, surgery is preferred for a lesion that originates from the muscularis propria, due to potential complications, such as esophageal perforation and excessive bleeding [11].

The progression of esophageal leiomyomas showed a benign course during the follow-up examinations. esophageal leiomyomas are generally slow growing. Therefore, for those patients with esophageal leiomyoma who refused to receive endoscopic resection or surgical excision, especially for those patients with a lesion < 20 mm, periodic follow up with EUS is preferred and acceptable [1].

## CONCLUSION

Multiple esophageal leiomyomas seem to be very rare, EUS is a valuable technique for the diagnosis of the disease and for making treatment decisions.

## REFERENCES

- Xu, H., Li, Y., Wang, F., Wang, W., & Zhang, L. (2018). Video-assisted thoracoscopic surgery for esophageal leiomyoma: a ten-year single-institution experience. *Journal of Laparoendoscopic & Advanced Surgical Techniques*, 28(9), 1105-1108.
- Seremetis, M. G., Lyons, W. S., Deguzman, V. C., & Peabody Jr, J. W. (1976). Leiomyomata of the esophagus. An analysis of 838 cases. *Cancer*, 38(5), 2166-2177.
- Prenzel, K. L., Schäfer, E., Stippel, D., Beckurts, K. T. E., & Hölscher, A. H. (2006). Multiple giant leiomyomas of the esophagus and stomach. *Diseases of the Esophagus*, 19(6), 504-508.
- Iwaya, T., Maesawa, C., Uesugi, N., Kimura, T., Ikeda, K., Kimura, Y., ... & Wakabayashi, G. (2006). Coexistence of esophageal superficial carcinoma and multiple leiomyomas: A case report. *World Journal of Gastroenterology: WJG*, 12(28), 4588.
- Mathew, G., Osueni, A., & Carter, Y. M. (2021). Esophageal leiomyoma. In *StatPearls [Internet]*. StatPearls Publishing.
- Cheng, Y. L., Hsu, J. Y., Hsu, H. H., Yu, C. P., & Lee, S. C. (2000). Diffuse leiomyomatosis of the esophagus. *Digestive Surgery*, 17(5), 528-531.
- Sokouti, M., Sokouti, M., & Sokouti, B. (2018). Primary role of EUS, CT, and esophagoscopy in diagnosing multiple giant leiomyoma of the esophagus: a literature review. *Journal of Medical and Surgical Research*, 5, 559-563.
- Fernandes, J. P., Mascarenhas, M. J., Costa, C. D., & Correia, J. P. (1975). Diffuse leiomyomatosis of the esophagus: a case report and review of the literature. *The American Journal of Digestive Diseases*, 20(7), 684-690.
- Gupta, V., Lal, A., Sinha, S. K., Nada, R., & Gupta, N. M. (2009). Leiomyomatosis of the esophagus: experience over a decade. *Journal of Gastrointestinal Surgery*, 13, 206-211.
- Ueki, Y., Naito, I., Oohashi, T., Sugimoto, M., Seki, T., Yoshioka, H., ... & Ninomiya, Y. (1998). Topoisomerase I and II consensus sequences in a 17-kb deletion junction of the COL4A5 and COL4A6 genes and immunohistochemical analysis of esophageal leiomyomatosis associated with Alport syndrome. *The American Journal of Human Genetics*, 62(2), 253-261.
- Jiang, T., Yu, J., Chen, L., Chen, H., Shan, G., Yang, M., & Xu, G. (2017). Clinical value of endoscopic ultrasonography for esophageal leiomyoma in elder patients. *Journal of Visualized Surgery*, 3.
- Puli, S. R., Reddy, J. B., Bechtold, M. L., Antillon, D., Ibdah, J. A., & Antillon, M. R. (2008). Staging accuracy of esophageal cancer by endoscopic ultrasound: a meta-analysis and systematic review. *World journal of gastroenterology: WJG*, 14(10), 1479.
- Kida, M., Kawaguchi, Y., Miyata, E., Hasegawa, R., Kaneko, T., Yamauchi, H., ... & Koizumi, W. (2017). Endoscopic ultrasonography diagnosis of subepithelial lesions. *Digestive Endoscopy*, 29(4), 431-443.
- Hwang, J. H., Rulyak, S. D., & Kimmey, M. B. (2006). American Gastroenterological Association Institute technical review on the management of gastric subepithelial masses. *Gastroenterology*, 130(7), 2217-2228.
- Dumonceau, J. M., Polkowski, M., Larghi, A., Vilmann, P., Giovannini, M., Frossard, J. L., ... & Ginès, A. (2011). Indications, results, and clinical impact of endoscopic ultrasound (EUS)-guided sampling in gastroenterology: European Society of Gastrointestinal Endoscopy (ESGE) Clinical Guideline. *Endoscopy*, 43(10), 897-912.
- Baysal, B., Masri, O. A., Eloubeidi, M. A., & Senturk, H. (2017). The role of EUS and EUS-guided FNA in the management of subepithelial lesions of the esophagus: A large, single-center experience. *Endoscopic ultrasound*, 6(5), 308.