

Oral Administration of L-Arginine Ameliorate Nsaid-Induced Gastric Injury in Wistar Rats

Kolawole I. AJIBOYE^{1*}, Francis S. OLUWOLE², Oyebimpe F. AJIBOYE³

¹Department of Physiology, Benjamin S Carson School of Medicine, Babcock University, Nigeria

²Department of Physiology, College of Medicine, University of Ibadan, Ibadan, Nigeria

³Department of Radiology, Babcock University Teaching Hospital, Ilesan, Nigeria

DOI: [10.36348/sjmpps.2019.v05i07.011](https://doi.org/10.36348/sjmpps.2019.v05i07.011)

| Received: 16.07.2019 | Accepted: 23.07.2019 | Published: 30.07.2019

*Corresponding author: Kolawole Ajiboye

Abstract

A major trend in ulcer management currently is the role of nitric oxide (NO) and its agonists such as L-Arginine in ameliorating gastric ulcers. The current study focuses on the possible effects of L-Arginine supplementation on indomethacin-induced gastric ulcerations in rats. Male Wistar albino rats weighing between 150-180g were used and divided thus: Group I (Control) – saline, 8ml/kg, Group II- L-Arginine 1g/kg B.W for 3 days, Group III- L-Arginine 1g/kg B.W for 7 days. The effect of L-arginine supplementation was on indomethacin-induced gastric ulcerations, ulcer dimensions and histological profile of the gastric mucosa was examined. The result showed that arginine supplementation possesses capabilities of reducing ulcer formation as evident by the lower ulcer scores of the supplemented groups when compared with the Control. The 3-day supplemented group had a significantly lower ulcer score ($p < 0.05$). Ulcer area and width were significantly reduced in the 3-day supplemented group ($p < 0.05$) while the ulcer depth was significantly reduced in both supplemented groups ($p < 0.01$). Histological examination of the gastric tissues showed that the 3-day supplemented group had greater reduction in the level of gastric disturbance than both Control group and the 7-day supplemented group. We proposed that a rapid angiogenetic activity in response to arginine supplementation which then wanes over time may be responsible for this pattern. This study provides evidence that arginine supplementation is beneficial in reducing the risk of gastric ulcer induced by NSAIDS and this is possibly mediated by direct enhancement of angiogenetic activity around the disturbed gastrum.

Keywords: Arginine, gastric ulcer, nitric oxide, cGMP, NSAID, indomethacin.

Copyright © 2019: This is an open-access article distributed under the terms of the Creative Commons Attribution license which permits unrestricted use, distribution, and reproduction in any medium for non-commercial use (NonCommercial, or CC-BY-NC) provided the original author and source are credited.

INTRODUCTION

One of the major paradigm shifts in the field of medicine is the refocusing of medical therapies from curative medicine to preventive medicine. In the domain of ulcer and its treatment, not much can be said to have been achieved in terms of preventing ulcer; no thanks to the multiple causative sources (aggressive factors) which has made prevention a herculean task. Most therapies to date have focused on isolating and treating the aggressive factor(s) responsible for the ulcer while others have generally relied on careful and strict abstinence from harmful causative sources. A major find and current trend in ulcer management is the role of nitric oxide (NO) and its precursor in ameliorating gastric ulcers [1, 2].

Several studies have documented the gastro-protective effects of NO against non-steroidal anti-inflammatory drugs (NSAID)-induced gastric ulceration. By extension L-Arginine, a precursor of NO has also been implicated in having positive effects on

gastric ulceration. Such positive benefits have included increased prostaglandin secretion, reduction in the amount of acid secreted and enhanced anti-oxidant action. Earlier studies have shown that pre-treatment with a single dose of NO synthase or its precursor ameliorates NSAID-induced gastropathy in rats [3]. There is however a paucity of data on the long-term benefits, if any, that may be derived from regular or supplementary use of NO precursors. This is why the current study focuses on the possible effects of oral administration of L-Arginine on indomethacin-induced gastric ulceration in rats.

MATERIALS AND METHODS

Animals

Male Wistar albino rats weighing between 150-180g were used for the study. They were procured from the Babcock University Animal Holding Facility, Babcock University, Nigeria. The animals were fed with standard rat and mice pellets (Ladokun feeds,

Ibadan) and given free access to water. Animals were divided according to the following experimental groups: Group I (Control) – saline, 8ml/kg, Group II- L-Arginine 1g/kg B.W for 3 days, Group III- L-Arginine 1g/kg B.W for 7 days

Studies carried out are

Study 1: Effect of L-arginine supplementation on indomethacin-induced gastric ulcerations.

Study 2: Determination of ulcer dimensions (area, depth and width)

Study 3: Histological profile of gastric mucosa

Experimental Procedures

1) Ulcer Induction - Indomethacin-induced ulceration model was adapted for this study [4]. Animals were fasted for 24 hours prior to experimentation but had free access to water. The Control group received Indomethacin (40mg/kg bw, p.o). Group II and Group III animals also received indomethacin (40mg/kg bw, p.o) at the end of their supplementation periods respectively. All animals were sacrificed 4hours after indomethacin administration with ether overdose; the stomachs were removed and assessed for ulcer lesions [5].

2) Ulcer scoring- This is based on a modified method of scoring method [6]. Ulcers were independently assessed and scored by two observers using the following criteria-

Normal stomach= 0

Punctuate/pin-point ulcer= 0.5

2 or more small haemorrhagic ulcers= 1
Ulcer greater than 2mm= 2

3) Percentage Inhibition- was calculated using the following formular:

$$\% \text{ Inhibition} = [I_c - I_t / I_c] \times 100$$

-where I_c is the ulcer index for Control group
 I_t is the ulcer index for the treated group.

4) Determination of Ulcer Dimensions-Ulcer dimension (Area, Depth and Width) determinations were determined using micrometric software, Motic 2000. The stomach samples were flattened and carefully sandwiched between two layers of transparent plastic folders and then scanned with the Motic 2000 image software.

5) Histological Assessment- Histological profiling of the ulcerated gastric mucosa was based on the method using Periodic Acid Schiff staining (PAS) [7]. Stomachs fixed with 10% formalin and embedded in paraffin were sectioned at 5µm in an automated microtome. The gastric tissue integrity (mucosa-submucosa) was assessed for damage.

STATISTICAL ANALYSIS

Data were expressed as Mean ± SEM. Statistical difference between test groups and control group was calculated using the student's t-test. $p < 0.05$ was considered as significant.

RESULTS AND DISCUSSION

Table-1: Effect of L-arginine supplementation on ulcer indices

Treatment Group	Mean Ulcer score	Paul's Index	Percentage Inhibition
Group I - Control (Saline 8ml/kg)	13.7 ± 1.47	13.7	-
Group II -1g/kg Arginine (3days)	8.12 ± 2.82*	4.06	70.4
Group III -1g/kg Arginine (7days)	11.4 ± 3.69	8.55	37.6

Data expressed as Mean ± SEM; n= 8. *- significant at $p < 0.05$ when compared with Control;

Table-2: Effect of L-arginine supplementation on ulcer dimensions

Treatment Group	Area (µm ²)	Width (µm)	Depth (µm)
Group I - Control (Saline 8ml/kg)	98.24 ± 6.61	78.22 ± 5.31	2687 ± 250
Group II- 1g/kg Arginine (3days)	40.10 ± 2.33**	54.81 ± 3.10*	20.88 ± 2.41**
Group III- 1g/kg Arginine (7days)	104 ± 1.21	66.16 ± 1.66	45.60 ± 3.62**

Data expressed as Mean±SEM; n= 8. *- significant at $p < 0.05$ when compared with Control; **- significant at $p < 0.01$ when compared with Control.

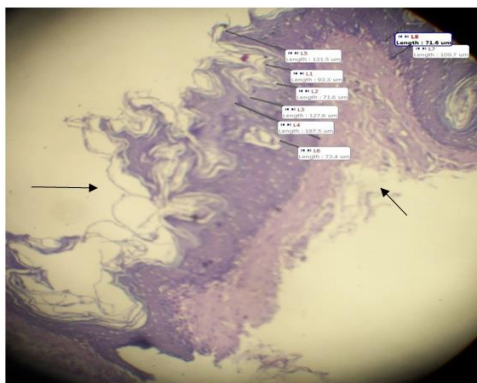


Fig-1: Control animal histology. Mucosa and submucosa exfoliation in control animals (arrowed). Gastric erosion extends into the muscularis externa (x40). White markings are labels for ulcer depth measurement

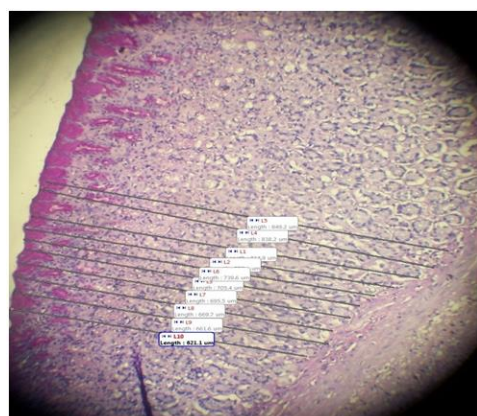


Fig-2: Group II animal (3-day supplementation) histology I. Normal gastric gland and mucosa structure in Group II animals (x40). White markings are labels for ulcer depth measurement

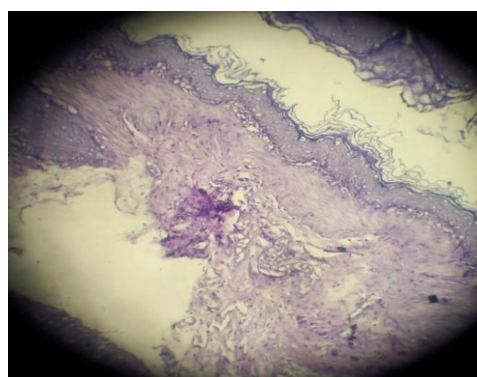


Fig-3: Group II (3-day supplementation) histology II. Mucosa and submucosa exfoliation (arrowed) (x40)

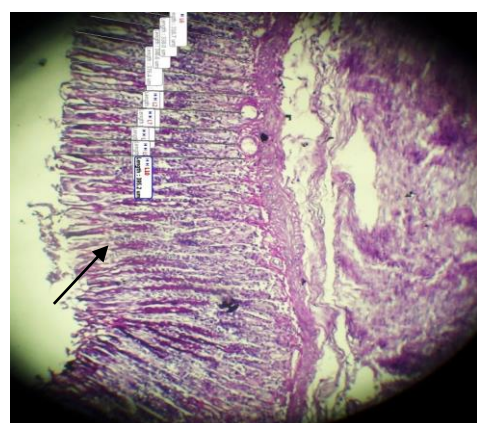


Fig-4: Group III (7-day supplementation) histology I. Slight apical glandular erosions (arrowed) with a fairly intact sub-mucosa (x40). White markings are labels for ulcer depth measurement

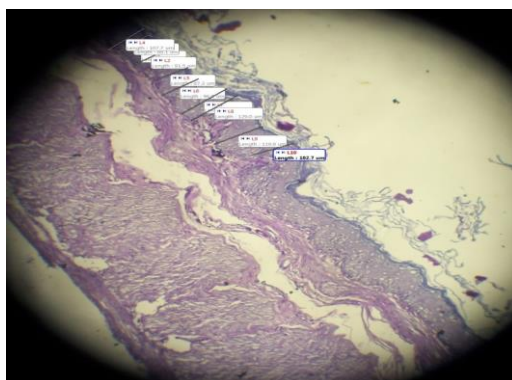


Fig-5: Group III (7-day supplementation) histology II. Complete glandular and epithelial erosion leaving only the sub-mucosa (x40). White markings are labels for ulcer depth measurement

DISCUSSION

The quest to conquer gastric ulcer has led to the discovery and administration of various kinds of therapies over the years. It is an accepted fact that improved vascular circulation enhances the gastrum's defensive prospects against ulcer [8]. Nitric oxide, an endogenous substance has been known to improve microcirculation around ulcers. Furthermore, the NO/cGMP pathway has been implicated in the pathogenesis of ulcers by several authors [9, 10]. Recent evidence has also shown that inducible NO promotes angiogenesis by enhancing vascular endothelial growth factor (VEGF) synthesis [11]. L-arginine is an NO precursor with similar capabilities as NO. It was therefore proposed that arginine supplementation may be beneficial in preventing gastric ulcer formation.

The result of this study showed that arginine supplementation possesses capabilities of reducing ulcer formation in indomethacin-induced rats. Table 1 shows that arginine supplementation has an ulcer reducing effect as evident by the lower ulcer scores of the supplemented groups when compared with the Control. The 3-day supplemented group had a significantly lower ulcer score ($p < 0.05$) when compared to control. This ulcer reducing effect is better seen in the ulcer inhibition index in which the 2 supplemented groups had a highly significant inhibition index when compared with the Control group ($p < 0.01$). Only 50% of the 3-day supplemented group and 75% of the 7-day supplemented group developed ulcer. These figures are in line with studies that have shown that NO-donors ameliorate gastric mucosa damage caused by NSAID agents [12, 13].

Table 2 shows the effect of arginine supplementation on ulcer dimensions. Ulcer area and width were significantly reduced in the 3-day supplemented group ($p < 0.05$) while the ulcer depth was significantly reduced in both supplemented groups ($p < 0.01$). As earlier mentioned, it may be possible that

the level of angiogenesis fostered by L-arginine may be responsible for the reduction in ulcer depth.

Oral administration of 40mg/kg indomethacin to rats provoked deep and severe disturbance of the gastric mucosa. The standard damage pattern usually is epithelial exfoliations that most times extend down into the muscularis mucosae. Histological examination of the gastric tissues however showed a reduction in the level of disturbance especially in the 3-day supplemented group (Fig. 2, 3) when compared with the Control group (Fig. 1). While it may be expected that protection against gastric ulcer formation will increase with increasing days of supplementation, this however was not the observed case. The 7-day supplemented group presented with more severe mucosa damage (Fig. 4, 5) when compared with the 3-day group. With a similar pattern observed in the ulcer inhibition index and the ulcer depth profile, we postulate that a rapid angiogenetic activity in response to arginine supplementation which then wanes over time is responsible for this pattern. This rapid angiogenesis may also be a major factor in the non-development of ulcer in 50% of the animals in the 3-day supplemented group and as the effect wanes more of the animals developed ulcer, as observed in the 7-day supplemented group. Further studies are planned on longer days of supplementation with varying doses of arginine while also incorporating direct angiogenetic studies.

CONCLUSION

This study provides evidence that arginine supplementation is beneficial in reducing the risk of gastric ulcer induced by NSAIDS and this is possibly mediated by direct enhancement of angiogenetic activity around the disturbed gastrum.

ACKNOWLEDGEMENT

Funding for the study was privately sourced. All authors listed contributed to conceptualisation, bench work and production of the manuscript. No conflict of interest is declared.

REFERENCES

1. Elliott, S. N., McKnight, W., Cirino, G., & Wallace, J. L. (1995). A nitric oxide-releasing nonsteroidal anti-inflammatory drug accelerates gastric ulcer healing in rats. *Gastroenterology*, *109*(2), 524-530.
2. Medeiros, J. V. R., Gadelha, G. G., Lima, S. J., Garcia, J. A., Soares, P. M. G., Santos, A. A., ... & Souza, M. H. L. P. (2008). Role of the NO/cGMP/KATP pathway in the protective effects of sildenafil against ethanol-induced gastric damage in rats. *British Journal of Pharmacology*, *153*(4), 721-727.
3. Ajiboye, K. I., & Oluwole, F. S. (2012). Possible mechanisms for the anti-ulcer protective activity of Tadalafil, a type V phosphodiesterase inhibitor on indomethacin-induced gastric ulceration in rats. *European Journal of Scientific Research*, *89*(3), 350-358.
4. Wallace, J. L., McKnight, W., Reuter, B. K., & Vergnolle, N. (2000). NSAID-induced gastric damage in rats: requirement for inhibition of both cyclooxygenase 1 and 2. *Gastroenterology*, *119*(3), 706-714.
5. Elegbe, R. A. (1978). Comparative studies on starvation-and indomethacin-induced ulcerations in albino rats. *Biochemistry and experimental biology*, *14*(2), 158-166.
6. Alphin, R. S., & Ward, J. W. (1967). Actions of hexopyrronium bromide on gastric secretion in dogs and on gastric secretion and ulceration in rats. *Archives internationales de pharmacodynamie et de therapie*, *168*(1), 82-100.
7. Sheehan, D., & Hrapchak, B. (1987). *Theory and Practice of Histotechnology*, ; Columbus. *OH-Battelle Memorial Institute*.
8. Hirose, H., Takeuchi, K., & Okabe, S. (1991). Effect of indomethacin on gastric mucosal blood flow around acetic acid-induced gastric ulcers in rats. *Gastroenterology*, *100*(5), 1259-1265.
9. Duffin, R., Shaw, C. A., & Rossi, A. G. (2008). Sildenafil reduces alcohol-induced gastric damage: just say 'NO'. *British journal of pharmacology*, *153*(4), 623-624.
10. Santos, C. L., Souza, M. H., Gomes, A. S., Lemos, H. P., Santos, A. A., Cunha, F. Q., & Wallace, J. L. (2005). Sildenafil prevents indomethacin-induced gastropathy in rats: role of leukocyte adherence and gastric blood flow. *British journal of pharmacology*, *146*(4), 481-486.
11. Zandifar, E., Sohrabi Beheshti, S., Zandifar, A., & Haghjooy Javanmard, S. (2012). The effect of captopril on impaired wound healing in experimental diabetes. *International journal of endocrinology*, *2012*.
12. Nakamura, C., Otaka, M., Odashima, M., Jin, M., Konishi, N., Horikawa, Y., ... & Watanabe, S. (2003). Rolipram, a specific type IV phosphodiesterase inhibitor, ameliorates indomethacin-induced gastric mucosal injury in rats. *Pathophysiology*, *9*(3), 195-200.
13. Khattab, M. M., Gad, M. Z., & Abdallah, D. (2001). Protective role of nitric oxide in indomethacin-induced gastric ulceration by a mechanism independent of gastric acid secretion. *Pharmacological research*, *43*(5), 463-467.