

## Post-Traumatic Orbital Emphysema: A Case Report

Jamal Oujaber<sup>1</sup>, Adil Arrob<sup>2\*</sup>, Rachid Sirbou<sup>1</sup>

<sup>1</sup>Medical and Surgical Emergency, Avicenne Military Hospital, Cadi Ayyad University, Marrakech, Morocco

<sup>2</sup>Department of Plastic Surgery, Maxillofacial and Stomatology, Avicenne Military Hospital, Cadi Ayyad University, Marrakech, Morocco

DOI: [10.36348/sjmpps.2019.v05i07.004](https://doi.org/10.36348/sjmpps.2019.v05i07.004)

| Received: 29.06.2019 | Accepted: 07.07.2019 | Published: 15.07.2019

\*Corresponding author: Adil Arrob

### Abstract

Orbital emphysema is typically a benign condition that occurs following forceful injection of air into the orbital soft tissue spaces. The authors report a frequent case of post traumatic orbital emphysema, we insist on the clinical aspects, radiological and therapeutic, and on the complications of this benign pathology.

**Keywords:** Trauma, orbital emphysema, complications.

**Copyright © 2019:** This is an open-access article distributed under the terms of the Creative Commons Attribution license which permits unrestricted use, distribution, and reproduction in any medium for non-commercial use (NonCommercial, or CC-BY-NC) provided the original author and source are credited.

### INTRODUCTION

Pneumorbity or orbital emphysema is defined as the presence of air within the orbital frame and which signs a fracture of the orbital frame with sinus communication or with the nasal fossae [1].

In most cases, it is infra-clinical and spontaneously resolving without sequelae. But it can be serious. By compromising the vascularization of the optic nerve [2] and retina [3, 4].

#### Case Presentation

A 19-year-old male presented to the emergency following a road accident for painful ocular tumefaction, major aortic chemosis, and an impossibility of palpebral occlusion, without loss of visual acuity.

He reported having a car accident few hours before with point of craniofacial impact with vomiting and initial loss of consciousness.

Clinical examination found a patient with hemodynamic and respiratory stability

- TA = 130/90 mmHg, FC = 95 bpm spo2 = 100%, and the pleuropulmonary examination is normal
- Neurological examination found a conscious patient well oriented in time and space GS =

15/15, equal and reactive pupil, no neurological motor or sensitive deficiency

- Left periorbital swelling with decreased palpebral opening with subtle subcutaneous crackling,
- The patient's eye was hard to press with conservation of the photomorphoc reflexes
- There was no decrease in visual acuity or associated oculomotor disorders
- The fundus revealed the presence of stage 1 papillary edema

A brain scan showed a fracture of the anterior stage of the skull base, passing through the left frontal sinus with pneumocephaly and left pneumorbitis.

Absence of traumatic cerebral damage, respect of the orbital walls and intra-orbital structures, especially on the left side (Fig 1-4).

Treatment consisted of medical treatment with carbonic anhydrase inhibitor DIAMOX 750mg / day DEPAKINE CR 500mg / day PREDNI 60mg / day Paracetamol 3g / day,

The patient was discharged from the hospital with the prohibition of violent bloating, sneezing and any movement that could lead to increased pressure of the upper aero-digestive tract.

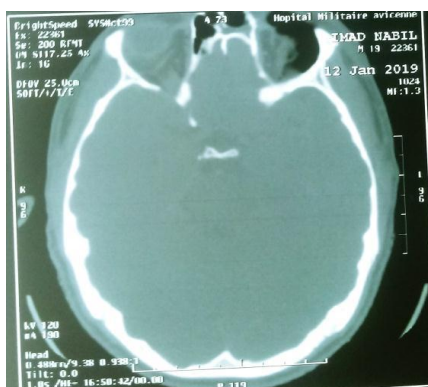

Fig-1: left pneumorbitis

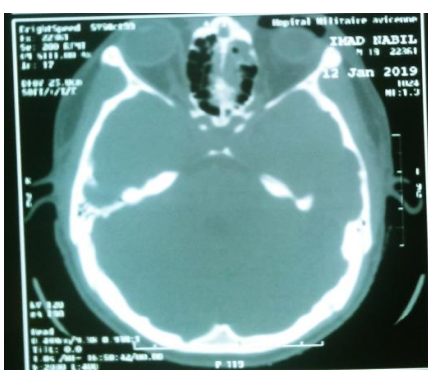

Fig-2: orbital left emphysema

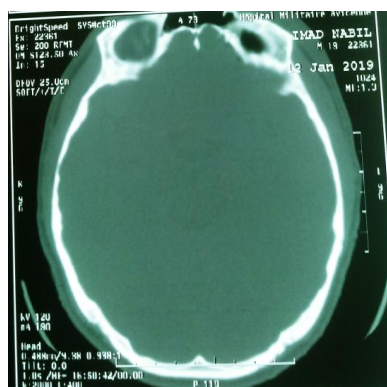


Fig-3: Fracture of the anterior floor of the skull base passing through the left frontal sinus

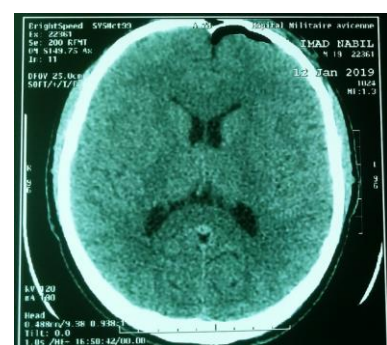

Fig-4: Left frontal pneumoencephaly

## DISCUSSION

Orbital emphysema (EO) or pneumorbity is defined as the presence of air within the orbital frame.

This is a common complication that occurs most often in a post-traumatic context [5]. However, it can be seen even without any trauma (barotrauma, infection, surgery...) [6].

The bone structure of the orbit is organized in the form of a cone with 4 walls. The lower and upper walls respond respectively to the maxillary sinus and frontal sinus, the inner wall, in turn, responds to the ethmoidal sinus. Any solution of bone continuity resulting in sinus communication with valve effect [7] can lead to pneumorbity. It should be noted that the fracture of the internal wall of the orbit is the most likely source of E.O [8].

EO is often mild and transient [9] resolving spontaneously in a variable time (usually a few days, but can persist for weeks [10] without leaving any sequelae [11].

In rare cases, EO may be serious because of a significant increase in intraocular pressure that may result in occlusion of the central artery of the retina or optic nerve compression neuropathy [12].

All these mechanisms will contribute, to varying degrees, to the decline in visual acuity objectified during the advanced stages of pneumorbity.

In addition, following a sudden increase in pressure in the upper aerodigestive tract (VADS) (bloating, sneezing, Valsalva maneuver, etc.), the air passes through the fracture site and diffuses into the orbit. If there is a valve phenomenon (orbital fat, bone fragment ...), the air cannot come out, resulting in a possible compression of the orbital content when the volume of air is greater [13].

Orbital emphysema can also occur without any trauma after violent blowing [14] endonasal surgery [15], thoracotomy [16], tooth extraction [17]. The ophthalmological complications are identical and directly related to the importance of pneumorbity.

The clinical picture of pneumorbity depends on the importance of emphysema. Hunts et al. [18] classified the EO in 4 stages according to the symptomatology: clinical latency stage I: subclinical, stage II: exophthalmia stage III: ocular globe hypertonia associated with optic neuropathy and stage visual acuity decline IV: obliteration of the central artery of the retina. With the preceding signs, a diplopia and an ophthalmoplegia can be associated [19]. Note that in all cases even minimal, the careful palpation of the eyeball will highlight the presence of crepitus [20].

The clinical examination must be completed by a fundus eye. An emergency orbital computed tomography is necessary for the diagnostic confirmation and to guide the therapeutic management [8].

The occurrence of central artery occlusion of the retina has been reported by several authors and constitutes a surgical emergency. His fear must lead to extremely urgent care [3].

In all cases of orbital emphysema, the patient must be advised to avoid any hyperpressure in the upper digestive airways, this advice constituting the main element of the treatment. Broad-spectrum antibiotic therapy is also introduced to prevent the occurrence of orbital cellulitis [5]. In stages 3 and 4 emergency surgical decompression should be performed by canthotomy or cantholysis, or more simply by needle.

## CONCLUSION

Orbital emphysema is a common and generally benign pathology, but can be serious in terms of visual prognosis.

His diagnosis is evoked by the traumatic context, the clinical examination and is confirmed by the imagery. Its management is surgical only in forms leading to nerve or vascular pain.

## REFERENCES

- Segrest, D. R., & Dortzbach, R. K. (1989). Medial orbital wall fractures: complications and management. *Ophthalmic plastic and reconstructive surgery*, 5(2), 75-80.
- Dobler, A. A., Nathenson, A. L., Cameron, J. D., Carpel, E. T., Janda, A. M., & Pederson, J. E. (1993). A case of orbital emphysema as an ocular emergency. *Retina*, 13, 166-168.
- Linberg, J. V. (1982). Orbital emphysema complicated by acute central retinal artery occlusion: case report and treatment. *Annals of ophthalmology*, 14(8), 747-749.
- Hunts, J. H., Patrinely, J. R., Holds, J. B., & Anderson, R. L. (1995). Orbital Emphysema: Staging and Acute Management. *Ophthalmic Plastic & Reconstructive Surgery*, 11(2), 147.
- Lu, T. C., Ko, P. C. I., Ma, M. H. M., & Chen, S. C. (2006). Delayed orbital emphysema as the manifestation of isolated medial orbital wall fracture. *Journal of Emergency Medicine*, 31(2), 223-224.
- Gloaguen, Y., Cochard-Marianowski, C., Potard, G., Rogez, F., Meriot, P., & Cochener, B. (2006). Emphysème orbitaire post-traumatique: à propos d'un cas. *Journal Francais d'Ophthalmologie*, 29(8), 942-e1.
- Benharbit, M., Karim, A., Lazreq, M., & Mohcine, Z. (2003). Articles Scientifiques-Communications De La SFO-Le traitement urgent de l'emphyseme orbitaire post-traumatique: a propos d'un cas. *Journal Francais d'Ophthalmologie*, 26(9), 957-959.
- Shinohara, H., Shirota, Y., & Fujita, K. (2004). Implication of differences in the incidence of orbital emphysema in ethmoidal and maxillary sinus fractures. *Annals of plastic surgery*, 53(6), 565-569.
- Key, S. J., Ryba, F., Holmes, S., & Manisali, M. (2008). Orbital emphysema—the need for surgical intervention. *Journal of Cranio-Maxillofacial Surgery*, 36(8), 473-476.
- Ababneh, O. H. (2013). Orbital, subconjunctival, and subcutaneous emphysema after an orbital floor fracture. *Clinical ophthalmology (Auckland, NZ)*, 7, 1077.
- Khader, Q. A., & Abdul-Baqi, K. J. (2010). Orbital emphysema after a protracted episode of sneezing in a patient with no history of trauma or sinus surgery. *Ear, Nose & Throat Journal*, 89(11), E12-E13.
- Khan, M. I., Clark, L., Jalil, A., & Ataulloh, S. (2011). Compressed air injury causing pneumo-orbit and xanthopsia. *Injury Extra*, 42(1), 11-12.
- Zimmer-Galler, I. E., & Bartley, G. B. (1994, February). Orbital emphysema: case reports and review of the literature. In *Mayo Clinic Proceedings*, 69(2), 115-121. Elsevier.
- Oluwole, M., & White, P. (1996). Orbital floor fracture following nose blowing. *Ear, nose & throat journal*, 75(3), 169-170.
- Neuhaus, R. W. (1990). Orbital complications secondary to endoscopic sinus surgery. *Ophthalmology*, 97(11), 1512-1518.
- Fox, R. J., Teener, J. W., & Liu, G. T. (1999). Orbital emphysema and diplopia following thoracotomy. *European journal of ophthalmology*, 9(4), 309-311.
- Buckley, M. J., Turvey, T. A., Schumann, S. P., & Grimson, B. S. (1990). Orbital emphysema causing vision loss after a dental extraction. *The Journal of the American Dental Association*, 120(4), 421-424.
- Hunts, J. H., Patrinely, J. R., Holds, J. B., & Anderson, R. L. (1994). Orbital emphysema: staging and acute management. *Ophthalmology*, 101(5), 960-966.
- Sen, D., & Chaturvedi, P. K. (2011). Orbital emphysema after sneezing: a case report. *Medical journal, Armed Forces India*, 67(3), 282.
- Papadimitriou, P., Ntomouchtsis, A., & Antoniadis, K. (2006). Delayed traumatic ocular emphysema: a case report. *Oral Surgery, Oral Medicine, Oral Pathology, Oral Radiology, and Endodontology*, 102(6), e18-e20.