

ABCs of the Occipital Aneurysmal Bone Cyst-Report on a Case

Nabil Raouzi^{1*}, Mohammed Yassaad Oudrhiri², Mohammed Khouali¹, Noureddine Oulali¹, Faycal Moufid¹

¹Neurosurgery department, CHU Mohammed VI, Mohammed Premier University, Oujda, Morocco

²Neurosurgery department, CHU Ibn Sina, Mohammed V University, Rabat, Morocco

DOI: [10.36348/sjmpps.2019.v05i06.013](https://doi.org/10.36348/sjmpps.2019.v05i06.013)

| Received: 17.06.2019 | Accepted: 26.06.2019 | Published: 30.06.2019

*Corresponding author: Nabil Raouzi

Abstract

Occipital Aneurysmal bone cyst is a rare benign tumor-like mass of the children and young adults. It is more frequent to the long bones and to the spine, but its location to the cranium is unusual. It is a lytic lesion, causing bone augmentation with a heterogeneous bloody content. Since its first description in 1942, only few cases have then been published in the literature and all have been listed in the text. We discuss through a successfully managed case of a 2 years old child the pathogenicity, the morphologic and radiologic criteria suggestive of this unusual pseudo-tumor and also discuss treatment options.

Keywords: Aneurysmal bone cyst, occipital, bone lysis, septae, surgery.

Copyright © 2019: This is an open-access article distributed under the terms of the Creative Commons Attribution license which permits unrestricted use, distribution, and reproduction in any medium for non-commercial use (NonCommercial, or CC-BY-NC) provided the original author and source are credited.

INTRODUCTION

Aneurysmal bone cyst (ABC) is a rare benign tumor-like mass of the child and young adults, representing 1-2% of all primary bone tumors (and only 3-5% of these are located to the cranial vault). It is a lytic lesion causing bone augmentation with heterogeneous bloody content, corresponding to the different stages of blood degradation. We discuss herein the case of a 2 years-old child with a large temporo-parieto-occipital location, which was successfully managed, and emphasize on the very suggestive radiological and morphological criteria of this unusual tumor and review existing literature.

CASE REPORT

A two years-old boy, with no past medical history, especially no previous traumatic event, presented to the outpatient clinic for a progressive retro-auricular mass, that started shortly after birth, and progressively getting into considerable sizes. On examination, the mass was in a left occipital location, firm, fixed and indolent, with no cutaneous inflammatory reaction, and measuring 50x40mm (Fig-1). There was a mild left cerebellar syndrome and patient was otherwise in good general condition.

Head CT and MRI scans were performed (Fig-2). On CT bone window and non-contrast images, the

mass was lytic, expanding both inner and outer tables of the occipital, temporal and parietal bone, reaching the mastoid process laterally, and containing multiple cysts separated by thin calcified septae. The density of the cysts content was heterogeneous from iso- to hyperdense. Development was more important to the intracranial space, both supra- and infratentorial, and the lesion appeared extradural. On MRI scans the lesion measured 80x75x59mm. Intra-cystic liquid intensity was variable from hypo- to hyperintensity on T1-weighted images, and iso- to hyperintensity on T2-weighted images, suggestive of unclotted blood. The mass was compressing significantly cerebral parenchyma with complete thrombosis of the lateral sinus on angiographic images.

Per-operatively, the tumor was a thin and friable bony shell, enclosing many communicating cyst cavities, filled with variable liquid content, reminiscent of the chronic subdural hematoma aspect. These cavities were lined with a thin mucosa. The tumor was completely extradural, and the underlying dura was intact (Fig 3A and 3B). Complete surgical removal was performed all around the tumor circumference, until hard bone limit. No consequent bleeding was noted. Pathology confirmed the suspected diagnosis of ABC. The postoperative course was uneventful with tumor free at 12 months.

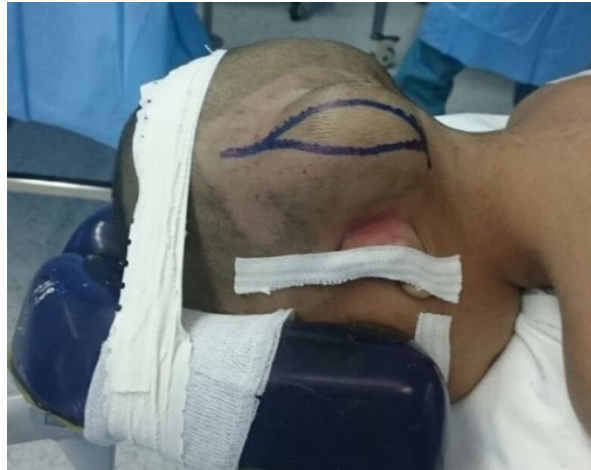

Fig-1: Preoperative image of the patient showing the occipital retromastoid mass and the operative incision planning

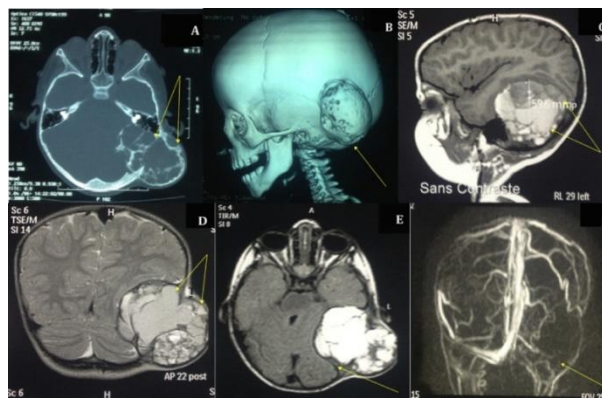


Fig-2 (panel): Preoperative imaging: A) Axial CT bone window image showing the bone augmentation and the multiple cavities and septae (arrows). B) 3D reconstruction showing the mass topography and bone lysis prints (arrow). C) T1-weighted sagittal image; the cysts signal is heterogeneous from hypo- to hyperintense (arrows). Height of the mass is 59.6mm. Note the compression of the cerebral parenchyma. D) T2-weighted coronal image; Heterogeneous signal intensity (arrows). Note the compression of the lateral sinus. E) Flair axial image showing hyperintensity of the cysts. The mass is extradural (arrow). F) Angiographic MRI reconstruction; complete thrombosis of the left lateral sinus (arrow)

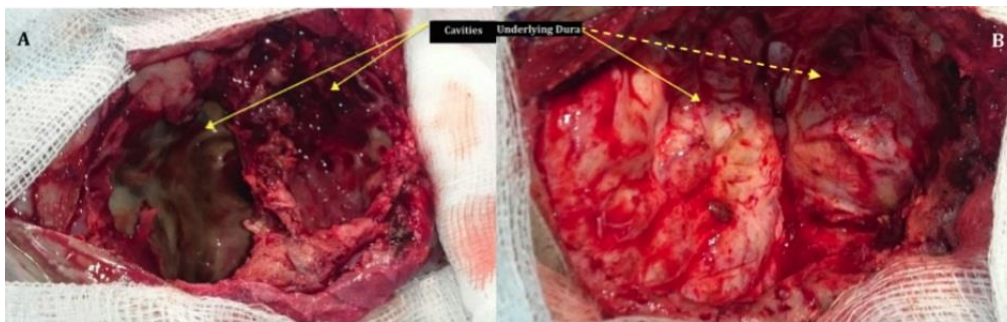


Fig-3: Operative images A) Note the multiples cavities (arrows) that constitute the mass; B) After complete resection image; supratentorial dura (continued arrow) and infratentorial dura (dashed arrow)

DISCUSSION

First described in 1942 by Jeffe *et al.*, ABC is a tumor-like mass, made of multiple cavities separated by thin septae and filled with blood lysis products [5]. It represents 1-2% of all primary bony tumors, and develops mainly in long bones (50%) and spine (20%). Location to the calvarium is rare (3-5%) and even unusual to the occipital bone [8, 13]. Literature is scarce, and to date, only 22 cases are reported (1-21), and of these only 16 cases are pure ABC of the occipital

bone with no associated pathology (Table-1) [1-10, 13, 15, 17-19, 21].

Although the exact origin is still unclear, many hypotheses are proposed to explain the pathogenicity of this lesion: A prior traumatic event causing local circulatory disturbances, or the ABC being a satellite lesion as 30% of these may be associated with an underlying pathology, or the ABC being a “de Novo” lesion as half of the cases show chromosome 16q-17p

translocations [9, 13, 16]. This latter hypothesis raises the possibility of the ABC being a neoplasm and not only a reactive lesion.

The usual age of presentation is mainly during first two decades, but rarely before age of 5, with almost no gender preference [5]. Symptoms are not specific but those of an expanding extra- and intracranial lesion that may sometimes rupture or cause acute hydrocephalous [5, 8, 18].

Radiographic imaging shows typically a well-circumscribed extradural lytic mass, with clear margins, expanding bone limits, and containing many cavities (cysts) with heterogeneous liquid-to-liquid appearance. This content varies widely from one cyst to another and appears from hypo- to hyperdensity on CT scans and from hypo- to hyperintense on T1-weighted images and hyper- to hypointense on T2-weighted images correlated to different stages of blood degradation. Theses radiological features may seem not specific, as they may be encountered in osteosarcoma, chondroblastoma, or giant cell tumor, but radiological aspects of benignity and age may add more specificity to the diagnosis [14].

Pathologic examination of surgical specimen shows cystic cavities, with bloody content, fibrous septae, and agglomerates of giant cells, with some osteoblastic reaction, but no neoplastic growth nor cellular atypia.

Treatment and management are mainly surgical, and should aim to a total excision reaching free margins. Incomplete resection, in some cases of skull base involvement, may result in recurrence as high as 70%. Many adjuvant therapies are possible if incomplete removal is achieved (sclerotherapy, calcitonin injection, radiotherapy...) but with less satisfactory results [13, 18]. Long follow up periods are necessary to assess the natural history of this pathology.

CONCLUSION

ABC of the occipital bone is a rare benign lesion of the child and young adult. Imaging features, associated to clinical and topographical data, should be highly suggestive when a lytic, well-defined, multicystic mass with heterogeneous bloody content, causing bone augmentation is encountered. Total surgical excision should be the goal.

Conflicts of Interest

The authors declare that there are no conflicts of interest regarding the publication of this article.

Disclosures: None.

REFERENCES

1. Arthur, R. J., & Brunelle, F. (1988). Computerised tomography in the evaluation of expansile lesions arising from the skull vault in childhood—a report of 5 cases. *Pediatric radiology*, 18(4), 294-301.
2. Bilge, T., Coban, O., Özden, B., Turantan, I., Türker, K., & Bahar, S. (1983). Aneurysmal bone cysts of the occipital bone. *Surgical neurology*, 20(3), 227-230.
3. Braun, J., Guilburd, J. N., Borovich, B., Goldsher, D., Mendelson, H., & Kerner, H. (1987). Occipital aneurysmal bone cyst: CT features. *Journal of computer assisted tomography*, 11(5), 880-883.
4. Chateil, J. F., Dousset, V., Meyer, P., Pedespan, J. M., San-Galli, F., Rivel, J., ... & Diard, F. (1997). Cranial aneurysmal bone cysts presenting with raised intracranial pressure: report of two cases. *Neuroradiology*, 39(7), 490-494.
5. Curtis, B. R., Petteys, R. J., Rossi, C. T., Keating, R. F., & Magge, S. N. (2012). Large occipital aneurysmal bone cyst causing obstructive hydrocephalus in a pediatric patient: Case report. *Journal of Neurosurgery: Pediatrics*, 10(6), 482-485.
6. Dávid, K., Horváth, Z., Horváth, A., & Illés, T. (1993). Aneurysmal bone cyst of the occipital bone: case report. *Surgical neurology*, 40(4), 332-335.
7. Gan, Y. C., & Hockley, A. D. (2007). Aneurysmal bone cysts of the cranium in children: Report of three cases and brief review of the literature. *Journal of Neurosurgery: Pediatrics*, 106(5), 401-406.
8. Garber, S. T., & Riva-Cambrin, J. K. (2015). Occipital aneurysmal bone cyst rupture following head trauma: case report. *Journal of Neurosurgery: Pediatrics*, 15(3), 272-275.
9. Genizi, J., Isaac, S., Dina, A., Liat, B. S., Jacob, B., Ellen, B. S., ... & Shlomi, C. (2011). Giant pediatric aneurysmal bone cysts of the occipital bone: case report and review of the literature. *Pediatric neurology*, 45(1), 42-44.
10. Han, X., Dong, Y., Sun, K., & Lu, Y. (2008). A huge occipital osteoblastoma accompanied with aneurysmal bone cyst in the posterior cranial fossa. *Clinical neurology and neurosurgery*, 110(3), 282-285.
11. Iseri, P. K., Efendi, H., Demirci, A., & Komsuoglu, S. (2005). Fibrous dysplasia of the cranial bones: a case report and review of the literature. *The Yale journal of biology and medicine*, 78(3), 141-145.
12. Itshayek, E., Spector, S., Gomori, M., & Segal, R. (2002). Fibrous dysplasia in combination with aneurysmal bone cyst of the occipital bone and the clivus: case report and review of the literature. *Neurosurgery*, 51(3), 815-818.
13. Kalina, P., & Wetjen, N. (2015). Aneurysmal bone cyst of the occipital bone. *The Journal of pediatrics*, 167(2), 496-496.
14. Lin, S. P., Fang, Y. C., Chu, D. C., Chang, Y. C., & Hsu, C. I. (2007). Characteristics of cranial aneurysmal bone cyst on computed tomography and magnetic resonance imaging. *Journal of the formosan medical association*, 106(3), 255-259.

15. Luccarelli, G., Fornari, M., & Savoiaro, M. (1980). Angiography and computerized tomography in the diagnosis of aneurysmal bone cyst of the skull: case report. *Journal of neurosurgery*, 53(1), 113-116.
16. Mattei, T. A., Mattei, J. A., Ramina, R., & Aguiar, P. H. (2005). Fibrous dysplasia in combination with aneurysmal bone cyst presenting as a subarachnoid haemorrhage. *Neurological Sciences*, 26(3), 178-181.
17. Mehboob, J., Aleem, U., & Asghar, A. H. (2011). Aneurysmal bone cyst of the occipital bone. *J Coll Physicians Surg Pak*, 21(10), 628-630.
18. Mete, M., Duransoy, Y. K., Çinar, C., Ovali, G., Temiz, P., & Selcuki, M. (2017). Giant occipital aneurysmal bone cyst caused to hydrocephalus in a child. *Child's Nervous System*, 33(11), 1871-1873.
19. Petro, M. L., & Lancon, J. A. (2001). Occipital aneurysmal bone cyst. *Pediatric neurosurgery*, 34(1), 45-46.
20. Roncaroli, F., Consales, A., Galassi, E., Bernardi, B., & Valeri, B. (2001). Occipital aneurysmal bone cyst secondary to eosinophilic granuloma. *Pediatric neurosurgery*, 35(2), 103-106.
21. Umredkar, A., & Srinivasa, R. (2012). Giant pediatric aneurysmal bone cyst of the occipital bone: Case report and review of the literature. *Neurology India*, 60(1), 126-128.