

Infectious Endocarditis with *Candida Albicans* on Aortic Prosthesis and Mitral Plasty: About A Case

Khalid Lahmadi^{1,2*}, Morad Belaouni¹, Rabii Elbahraouy¹, Mohammed Sbiti^{1,2}, Lhoucine Louzi^{1,3}, Mohammed Er-Rami^{1,2}

¹Biology laboratory Moulay Ismail Military Hospital, Meknes, Morocco

²Sidi Mohamed Ben Abdellah University, Faculty of Medicine and Pharmacy of Fes, Morocco

³Mohamed V University, Faculty of Medicine and Pharmacy of Rabat, Morocco

*Corresponding author: Khalid lahmadi

| Received: 09.06.2019 | Accepted: 16.06.2019 | Published: 30.06.2019

DOI: [10.36348/sjmpps.2019.v05i06.010](https://doi.org/10.36348/sjmpps.2019.v05i06.010)

Abstract

We report the case of an infective *Candida albicans* fungal endocarditis occurring in a 68-year-old male patient operated on for valvulopathy and with a pacemaker, with a delay of 06 years between his cardiovascular surgery and the onset of endocarditis. The diagnosis was confirmed by blood culture and echocardiography showing the presence of vegetations, the patient was then put under fluconazole with clinical and transient biological improvement before the worsening of the clinical picture and control echocardiography increase the size of his abscess of the mitral ring, which motivated the decision of a surgical treatment.

Keywords: An Infective *Candida Albicans* Fungal Endocarditis.

Copyright © 2019: This is an open-access article distributed under the terms of the Creative Commons Attribution license which permits unrestricted use, distribution, and reproduction in any medium for non-commercial use (NonCommercial, or CC-BY-NC) provided the original author and source are credited.

INTRODUCTION

Candida endocarditis is a rare and little known disease. The particular gravity of fungal endocarditis results from the intrication of multiple factors, such as: the particularly high frequency of embolic complications, the difficulty of sterilization of vegetations because of their often large size and the low intrinsic efficacy of conventional antifungal treatments in this local infectious focal point, and the underlying terrain, because they are willingly immunocompromised or have significant comorbidities, invasive procedures and / or prosthetic valves valvular prognosis. With a mortality of more than 50% [1].

We report the case of a patient with a prosthetic valve and a pacemaker who developed *Candida albicans* sepsis associated with recurrent endocarditis after antifungal therapy.

OBSERVATION

This is a 68-year-old male patient with a history of mitro-aortic valvulopathy surgically treated six years ago (aortic prosthesis and mitral repair), and a rhythm disorder for which he has benefited from a pacemaker.

Four months ago the patient experienced a predominantly nocturnal fever, profuse chills and sweats with NYHA dyspnea stage III, the cardiovascular examination found signs of right heart failure and the pulmonary examination revealed sibilant groans.

The chest x-ray showed cardiomegaly and bilateral diffuse interstitial syndrome and echocardiography a slightly dilated left ventricle. The echotomography could highlight the existence of multiple vegetations on the large mitral valve (Fig-1) with presence of abscesses in the vicinity of the mitral annulus (Fig-2).

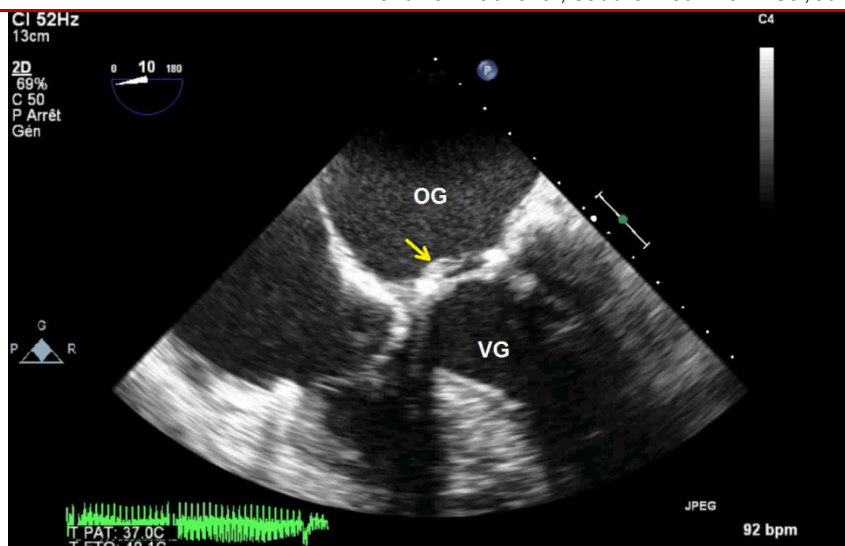


Fig-1: Transesophageal echocardiography showing vegetation at the expense of the ring and the large mitral valve

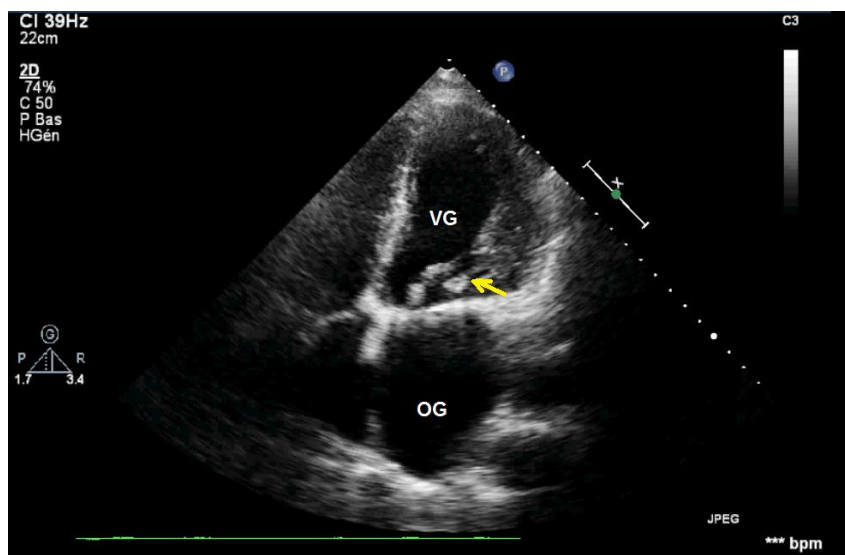


Fig-2: Trans-thoracic echocardiography showing abscess in the vicinity of the mitral annulus

The biological assessment showed hyperleucocytosis at 12530 element / mm³ and a CRP at 64 mg / l. Blood culture allowed isolation and identification of *Candida albicans*. The exploration of immunity (HIV serology and tumor markers) showed nothing special.

The patient was put on Fluconazole (Triflucan®) 400mg / day with clinical improvement (absence of fever and regression of dyspnea) and biological (normal NFS, normal CRP, absence of candidemia). One month later the patient was readmitted for relapse of his infectious endocarditis with dyspnea stage III and persistent fever at 38.5, CRP 60 and blood culture positive to *Candida albicans*. Echotomography control always noted the presence of vegetations at the same sites with increased size of the mitral abscess, the decision was made to refer the patient to the cardiovascular surgery department for surgical management of his endocarditis.

DISCUSSION

Fungal endocarditis is very rare; however, their incidence is certainly underestimated because of difficulties in demonstrating the microorganism responsible [2, 3].

In France, the annual incidence of *Candida* sp. Endocarditis is estimated to be between 10 and 25 cases, making it a rare and little known disease [4]. In Morocco, no study on the incidence of this fungal pathology has been carried out.

Fungal endocarditis is a formidable prognosis infection, since the overall mortality rate is greater than 50% [1, 5] and it is estimated at 40,3% for yeast endocarditis [1, 3]. The most common fungi are represented by the genus *Candida* sp. (53 ° / °) cases, more rarely *Aspergillus* (24 ° / °) [6].

According to the literature, *C. albicans* is the most frequently isolated species [7]. Thus, the prospective French national study on candida sp. Endocarditis (mycendo) showed that the majority of the cases collected were due to *C. albicans*. With a proportion of 60% / %, followed by candida parapsilosis, found mainly in addicts [8].

The main risk factors are:

- Valvular abnormalities are the main risk factor and are found in 64% of patients: previous valvular surgery in 54% of patients, history of bacterial endocarditis in 13% of patients, rheumatic fever, non rheumatic heart disease, prolapse mitral valve [5]. Seven cases of endocarditis *Candida* sp. on pace maker have also been reported [9, 10].
- Intravenous drug abuse is also a significant risk factor, found in 3.9 [1] to 13% [5] of patients with fungal endocarditis.
- Immunosuppression related to increased use of broad-spectrum antibiotics and corticosteroid therapy, HIV infection, cancer, as well as advances in technology over the last 20 years (extended central intravenous catheters, dialysis, immunosuppression, organ transplants and marrow allograft, cardiovascular surgery, parenteral nutrition) [1, 11].

In our patient several risk factors have come together, namely cardiovascular surgery, pacemaker placement and broad spectrum antibiotic therapy

Fungal endocarditis has a usually acute mode of presentation. The most frequently encountered clinical signs are fever, the modification of a pre-existing breath or the appearance of a new breath of regurgitation [5]. A purpura, nodules of Osler, splenomegaly are found in varying proportions [12].

Our patient experienced a predominantly nocturnal fever, profuse chills and sweats with dyspnea, cardiovascular examination found signs of right heart failure and lung examination revealed sibilant rattles.

Sometimes endocarditis is revealed by complications such as focal or diffuse neurologic signs, heart failure and dyspnea, indicating pulmonary septic emboli, peripheral emboli [5].

The diagnosis is based primarily on the positivity of blood cultures and on the other hand, on the echocardiography.

Most of the blood culture media currently used allow the growth of *Candida* yeasts. If routine blood cultures are negative but the diagnosis is strongly suspected, it is desirable to perform fungal blood cultures whose medium is optimized for yeast culture. The use of these antibiotic-containing media saves time

for microorganism detection and species diagnosis, particularly for slow-growing species (*C. glabrata*).

Moreover, these media are advantageous in cases of mixed septicemia of bacterial and fungal origin. The disadvantages of these fungal media are on the one hand a higher cost and on the other hand a larger amount of blood needed. If optimal methods are used, more than 90% of candidaemia is detectable in less than 48 hours [13].

In our patient the blood culture allowed the isolation and identification of *Candida albicans*. The purpose of echocardiography is to look for the visualization of vegetation whose diameter must be greater than three millimeters. These vegetations can sit on the cardiac valves as in the endocardium [14].

Transesophageal echography, whose sensitivity has been shown to be better than that of trans-thoracic ultrasonography for endocarditis on native valves [15]. Regarding prosthetic valve endocarditis, transthoracic ultrasonography is less efficient because of the echoes generated by the prosthesis, which mask anomalies, especially for small vegetations. Transesophageal echography avoids this pitfall, especially at the level of the mitral valves, by allowing an unobstructed view of the prosthetic valve by the left atrium and the mitral orifice, inaccessible by transthoracic ultrasound [16]. Preferentially sit at the aortic level regardless of the series of literature [4]. In our case, the echocardiography revealed the existence of multiple vegetations on the large mitral valve (Fig-1) with presence of abscesses in the vicinity of the mitral annulus (Fig-2).

No biological argument decisively guides the diagnosis of either leukocytosis or even serology, a study found significant anti-*Candida* antibody titers in nearly 40% of patients undergoing surgery cardiac, apart from any clinical sign of *Candida* sp. whereas, on the other hand, a large number of patients operated on and having candidemia did not have a significant antibody titre [12]. Serologies therefore do not seem to be of interest for diagnostic purposes, but they may nevertheless play a role in patient follow-up, since a decrease in antibodies may suggest infection control [17]. It is currently difficult to say whether this decay could guide secondary prophylaxis. The detection of *Candida* sp. PCR is, however, very promising, with excellent sensitivity, but the techniques are still under evaluation [4].

The treatment of fungal endocarditis is poorly codified in the absence of large prospective human therapeutic studies.

Candida endocarditis sp. have been recommended by the Infectious Disease Society of America [18]. These recommend the use of

amphotericin B or lipid formulations of amphotericin B as a first-intention, which should be used as early as possible after the diagnosis of Candida endocarditis, in progressive doses over two days. the usual dose being 0.7 to 1 mg / kg / day for a total dose of 2 to 3 g [19, 20], associated with 5-fluorocytosine at a dose of 100 to 200 mg / kg / j with regular biological monitoring because of its hepatic and hematological toxicity potentiated by the joint use of amphotericin B. Under no circumstances should 5-fluorocytosine be used in monotherapy because of the rapid onset of resistance, observations are reported efficacy of fluconazole alone or in combination with surgery [21].

However, in case of intolerance to amphotericin B, fluconazole seems to be a good alternative [4]. It is conventional to consider that the optimal treatment of a fungal endocarditis is based on a medico-surgical combination, especially since the infection occurs on a prosthetic valve [20, 15]. In the Ellis et al. Series, the prognosis of patients who received a medical-surgical combination tended to be better than that of patients treated exclusively medically. However, the interpretation of these percentages must be very cautious because of the retrospective nature of this study; It can thus be thought that only those patients who can withstand surgery in principle have been entrusted to the surgeon [5]. However, isolated medical treatment must be reserved for patients who are too fragile to undergo surgery or refuse surgery [21].

The need for surgery depends on the characteristics of the vegetations, which are bulky necrotic and therefore responsible for significant loss of substance, friable and therefore potentially very emboligenic. It is also based on diffusion characteristics of antifungals. Rubinstein et al. having demonstrated that the reason for the failures of medical treatment was the lack of penetration of amphotericin B into the vegetations [22].

Because of the high rate of relapse of fungal endocarditis (in the order of 30% of survivors), sometimes occurring several years after the first episode and after a very prolonged medical treatment [5], initial treatment is often followed by treatment. for long-term or lifetime maintenance, especially for prosthetic endocarditis, but some authors recommend maintenance therapy for endocarditis on a native valve [1, 5]. In the case of Candida endocarditis, the usual practice is to use oral fluconazole at a dose of 200-400 mg daily [20, 15]. Regular monitoring of these patients is necessary.

Our patient was put under fluconazole, however the evolution was marked by an aggravation after a slight improvement probably due to the lack of diffusion of the antifungal at the level of the vegetations requiring a surgical intervention.

CONCLUSION

Fungal endocarditis is a pathology that is still poorly understood and has a very poor prognosis. Prognostic improvement should be achieved by shortening the diagnostic delay and optimizing the therapeutic management.

REFERENCES

1. Pierrotti, L. C., & Baddour, L. M. (2002). Fungal Endocarditis, 1995–2000. *Chest*, 122(1), 302-310.
2. Baddley, J. W., Benjamin, D. K., Patel, M., Miró, J., Athan, E., Barsic, B., ... & Klein, J. (2008). Candida infective endocarditis. *European journal of clinical microbiology & infectious diseases*, 27(7), 519-529.
3. Lefort, A., Gantier, J. C., & Lortholary, O. (2004). Endocardites fongiques. *Réanimation*, 13(3), 197-204.
4. Abgueguen, P., Gouello, J. P., Pichard, E., Chabasse, D., Donal, E., & Alquier, P. (2002). Endocardites à Candida: étude rétrospective de 12 patients. *La Revue de médecine interne*, 23(1), 30-40.
5. Ellis, M. E., Al-Abdely, H., Sandridge, A., Greer, W., & Ventura, W. (2001). Fungal endocarditis: evidence in the world literature, 1965–1995. *Clinical Infectious Diseases*, 32(1), 50-62.
6. Le Guillou, S., Casalta, J. P., Fraisse, A., Kreitmann, B., Chabrol, B., Dubus, J. C., & Bosdure, E. (2010). Endocardite infectieuse sur cœur sain chez l'enfant: étude rétrospective de 11 cas. *Archives de pédiatrie*, 17(7), 1047-1055.
7. Abgueguen, P., Gouello, J. P., Pichard, E., Chabasse, D., Donal, E., & Alquier, P. (2002). Endocardites à Candida: étude rétrospective de 12 patients. *La Revue de médecine interne*, 23(1), 30-40.
8. Lefort, A., Chartier, L., Podglajen, I., Sendid, B., Mainardi, J. L., Bretagne, S., ... & Lortholary, O. (2009). Étude nationale prospective sur les endocardites à Candida sp.(Mycendo). *La Revue de médecine interne*, (30), S349.
9. Joly, V., Belmatoug, N., Leperre, A., Robert, J., Jault, F., Carbon, C., & Yeni, P. (1997). Pacemaker endocarditis due to Candida albicans: case report and review. *Clinical infectious diseases*, 25(6), 1359-1362.
10. Kurup, A., Janardhan, M. N., & Seng, T. Y. (2000). Candida tropicalis pacemaker endocarditis. *Journal of Infection*, 41(3), 275-276.
11. Rubinstein, E., & Lang, R. (1995). Fungal endocarditis. *European heart journal*, 16(suppl_B), 84-89.
12. Ryhänen, P., Puhakka, K., Kujala, P., Koskela, P., Silvennoinen-Kassinen, S., Kärkölä, P., & Ikäheimo, M. (1986). Candida immunity in patients undergoing surgical treatment for heart valve disease. *The Journal of cardiovascular surgery*, 27(1), 72-78.

13. Fricker-Hidalgo, H., Orenge, S., Lebeau, B., Pelloux, H., Brenier-Pinchart, M. P., Ambroise-Thomas, P., & Grillot, R. (2001). Evaluation of Candida ID, a new chromogenic medium for fungal isolation and preliminary identification of some yeast species. *Journal of clinical microbiology*, 39(4), 1647-1649.
14. Khandheria, B. K. (1993). Suspected bacterial endocarditis: to TEE or not to TEE. *Journal of Am Coll Cardiol*, 21: 222-224.
15. Melgar, G. R., Nasser, R. M., Gordon, S. M., Lytle, B. W., Keys, T. F., & Longworth, D. L. (1997). Fungal prosthetic valve endocarditis in 16 patients. An 11-year experience in a tertiary care hospital. *Medicine*, 76(2), 94-103.
16. Daniel, W. G., & Mugge, A. (1995). Transesophageal echocardiography. *New England Journal Medecine*, 332: 1268-1279.
17. Venditti, M., De Bernardis, F., Micozzi, A., Pontieri, E., Chirletti, P., Cassone, A., & Martino, P. (1992). Fluconazole treatment of catheter-related right-sided endocarditis caused by *Candida albicans* and associated with endophthalmitis and folliculitis. *Clinical infectious diseases*, 14(2), 422-426.
18. Pappas, P. G., Rex, J. H., Sobel, J. D., Filler, S. G., Dismukes, W. E., & Walsh, T. J. (2004). Infectious Diseases Society of America. Guidelines for treatment of candidiasis. *Clinical infectious diseases*, 38:161-189.
19. Muehrcke, D. D. (1995, January). Fungal prosthetic valve endocarditis. In *Seminars in thoracic and cardiovascular surgery*, 7(1), 20-24.
20. Gilbert, H. M., Peters, E. D., Lang, S. J., & Hartman, B. J. (1996). Successful treatment of fungal prosthetic valve endocarditis: case report and review. *Clinical infectious diseases*, 22(2), 348-354.
21. Isalska, B. J., & Stanbridge, T. N. (1988). Fluconazole in the treatment of candidal prosthetic valve endocarditis. *BMJ: British Medical Journal*, 297(6642), 178-179.
22. Rubinstein, E., Noriega, E. R., Simberkoff, M. S., & Rahal Jr, J. J. (1974). Tissue penetration of amphotericin B in *Candida* endocarditis. *Chest*, 66(4), 376-377.