

Morphometric and Morphologic Study of the Vermiform Appendix in Nigerian Cadavers

Edibamode E. I, Adheke M. O*, Paul, J. N, Onwuli B.C

Department of Anatomy, Faculty of Basic Medical Sciences, College of Health Sciences, University of Port Harcourt, Nigeria

*Corresponding author: Adheke M. O

| Received: 02.03.2019 | Accepted: 07.03.2019 | Published: 30.03.2019

DOI: [10.36348/sjmpps.2019.v05i03.001](https://doi.org/10.36348/sjmpps.2019.v05i03.001)

Abstract

Background: The vermiform appendix is a wormlike diverticulum, arising from the posteromedial wall of the caecum, about 2cm from the ileocecal orifice. A cadaveric study was conducted to ascertain the average length, the most recurrent position and the location of the vermiform appendix with respect to the tenia coli. **Materials and Methods:** The study had a sample size of 41 cadavers gotten from the anatomical laboratory of five Universities within the south-south geopolitical zones in Nigeria. The length of the vermiform appendix was measured using a broom stick placed at its base to get the whole length of the vermiform appendix, stretched from base to its tip then measured with a digital vernier calliper to deduce the length. This procedure is carried out two or more times and the average is taken. **Results and Discussions:** The average length of the vermiform appendix irrespective of sex was 8.7 ± 0.89 cm, while the average length for males and females were 8.80 ± 0.9 cm and 8.36 ± 0.73 cm respectively. The location of the vermiform appendix to the taenia coli was found constant at the confluence of the three muscular bands of the taenia coli which forms the musculature of the vermiform appendix. The most common position of the tip of the vermiform appendix was the retrocaecal position-22(53.7%), while the other positions are pelvic-11(26.8%), postileal-4(9.8%), subcaecal-3(7.3%) and preileal-1(2.4%). None was observed for the paracaecal position. **Conclusion:** The morphometry and the morphology of the vermiform appendix in Nigerian cadavers have been observed to follow a trend with respect to its length and position which is in tangent with most findings over the world.

Keywords: vermiform, diverticulum, appendix, cadaver.

Copyright © 2019: This is an open-access article distributed under the terms of the Creative Commons Attribution license which permits unrestricted use, distribution, and reproduction in any medium for non-commercial use (NonCommercial, or CC-BY-NC) provided the original author and source are credited.

INTRODUCTION

The vermiform appendix is a wormlike diverticulum, arising from the posteromedial wall of the caecum, about 2cm from the iliocaecal orifice [1]. It was first described by Leonardo da Vinci in 1492. Due to the abundance of patients presented with appendicitis and the subsequent need for appendectomy, anatomists and anatomical scientists have been keen on carrying out researches as to perform better and safer surgical procedures on the vermiform appendix [2]. Anatomically, the position of the appendix is extremely variable more than any other organ and if it is too long, the appendix may extend to any part of the body [3]. The ultimate position of the appendix is profoundly influenced by the changes in position and shape which the caecum undergoes during development and growth [4]. In general, however, some studies describe a significant relationship between its location and acute appendicitis. A study in Nigeria by Ojeifo *et al.*, on the position of the vermiform appendix in Nigerians, using 548 post-surgical and post-mortem subjects showed retrocaecal to be 45.07%, subcaecal, pelvic, pre-ileal,

post-ileal and ectopic were 2.37%, 25%, 1.82%, 14.78%, 6.39% and 4.74% respectively [5]. In another study, an examination of 154 patients that underwent appendectomy, in the University of Gondar teaching hospital, Ethiopia, it was observed that the retrocaecal position was the most common with 112 (72.7%), followed by the pelvic position, with 18 (11.69%), the pre-ileal position was 16 (10.39%) and subcaecal with 8 (5.19%), with no cases of other positions recorded [6]. Mwachaka *et al.*, did a study to observe the relation of the vermiform appendix, to the spinoumbilical line, which is the average distance between the anterior superior iliac spine and umbilicus and found the base of the appendix to be located along the spinoumbilical line in 25 (52.1%) cases and in the remaining, it was not located in the spinoumbilical line [7]. Other studies have also been able to give varying description and analysis on the length of the vermiform appendix, subsequent sexual dimorphic features and susceptibility to inflammation of the position of the vermiform appendix [2]. Ashindoitiang *et al.*, observed that the length of the vermiform appendix in his study on 80 patients presented with acute appendicitis in Nigeria is

on the average 0.4cm longer in males than in females [8]. Hence, a strong association has been established between locations of the appendix and the development of advanced appendicitis, resulting in longer hospital stays and in high incidence of gangrene and perforation [9]. Therefore, the morphologic and morphometric study of the vermiform appendix is being re-reviewed so as to ascertain if there is at present, recent variations as compared to the past. The study aims at investigating the different positions and morphometric variations of the vermiform appendix in Nigerian cadavers.

MATERIALS AND METHODS

The research was carried out in five Universities within South-south and South-east geopolitical zones of Nigeria (Southern Nigeria). The universities visited for the study include; University of Port-Harcourt, Choba, Rivers State. Niger Delta University, Amassoma, Bayelsa State, Imo State University, Owerri, Imo State, Abia State University, Uturu, Abia State and Madonna University, Elele, Rivers State. A sample size of 41 cadavers from the anatomical laboratories of the aforementioned tertiary institutions were used based on convenience and availability (convenience sampling). Only adult cadavers who had their abdominal organs intact were included in the study. The cadavers were laid in the anatomical (supine) position; a horizontal incision was taken with the use of a scalpel from the mid-axillary line to the xiphosternal junction. A vertical midline incision from the xiphosternal junction to the pubic symphysis was done and followed to the anterior superior iliac spine. The skin and fascia of the abdominal region were reflected to gain access to the abdominal contents, where the vermiform appendix was located and critically examined. The location of the vermiform appendix with respect to the taenia coli was noted, the position with respect to the tip was also noted and the length was traced with a broomstick from the

base of the vermiform appendix throughout its stretched length to the tip of the appendix. This procedure was carried out two or more times and the average length was taken to avoid errors. The broomstick was further measured using a digital vernier caliper, the length was recorded in millimeters and further converted to centimeters.

The data being a primary data were obtained from dissecting laboratories in the Department of Human Anatomy of Universities in the Southern part of Nigeria, in accordance with the Anatomy Act, Chapter 17 of the Nigerian Constitution which allows any student attending a course of study in a school of anatomy licensed under this act to examine anatomically the body of any person deceased, if permitted or directed so to do by a person who had at the time of giving such permission or direction had power, in pursuance of the provisions of the act to permit or cause the body to be examined.

The resulting data gotten from the study was subjected to statistical analysis using Statistical Package for Social Sciences (SPSS) version 20 for Pearson's Chi-square in order to determine the relationship (or association) between the sex (gender) and position of vermiform appendix. Results were presented in the form of frequency tables and bar chart and considered statistically significant when probability was less than 5% ($p < 0.05$).

RESULTS AND DISCUSSIONS

Position of the vermiform appendix

From this present study, the position of vermiform appendix with respect to sex, revealed still the retrocaecal position to be the highest of 22 out of the 41 cadavers accounting for 53.7%, followed by the pelvic position of 26.8% (11 out of the 41 cadavers).

Table-1: Position, Frequency and Percentage Frequency of Vermiform Appendix in 41 cadavers studied

Position	Retrocaecal	Pelvic	Postileal	Subcaecal	Paracaecal	Preileal	Total
Frequency	22	11	4	3	0	1	41
Percentage	53.7%	26.8%	9.8%	7.3%	0.0%	2.4%	100%

This is in agreement to Wakeley who worked on 10,000 cadavers and recorded a high percentage frequency of retrocaecal vermiform appendix position of 62.2% while the pelvic position of vermiform appendix was 31.01%. Subcaecal, preileal and postileal vermiform appendix positions were 2.26%, 1% and 0.4% respectively [3]. Patel and Naik both worked on

50 Indian cadavers, observed the retrocaecal-64%, pelvic-30%, postileal-4% and subcaecal-2% [10]. Clegg-Lamprey *et al.*, also found a predominant retrocaecal position (67.3%), pelvic (21.6%), preileal (4.9%), postileal (3.8%) and paracaecal (2.4%) [11]. This pattern of frequencies in the positional variation in vermiform appendix have been consistent.

Table-2: Position, Frequencies and Percentage Frequencies of Vermiform Appendix in Male and Female Cadavers

Position	Retrocaecal	Pelvic	Postileal	Subcaecal	Paracaecal	Preileal	Total
Males	18 (43.9%)	7(17.0%)	4 (9.8%)	2 (4.9%)	0 (0.0%)	1 (2.4%)	32(78.0%)
Females	4 (9.8%)	4 (9.8%)	0 (0.0%)	1 (2.4%)	0 (0.0%)	0 (0.0%)	9 (22.0%)
Total	22 (53.7%)	11(26.8%)	4 (9.8%)	3 (7.3%)	0 (0.0%)	1 (2.4%)	41(100.0%)

From the table above, it was observed that out of the 22 retrocaecal positions, males account for 18 (56.25%) out of 32 total males used while females accounted for 4 out of 9 females used (44.44%). The statistical level of association in sexual dimorphism revealed no association since P-value (0.53) was greater than 0.05.

However, this tends to differ from studies by Gopalipour *et al.*, who worked on 117 Indian cadavers and Katzurski *et al.*, who worked on 103 Ghanian cadavers. According to Gopalipour *et al.*, pelvic position of the vermiform appendix is the common position with percentage frequency of 33.3% followed by retrocaecal 32.45%, preileal 18.8% subcecal 12.8% and postileal 2.6% [12]. Katzurski *et al.*, observed the pelvic to be 43% in his study which was the highest as well [13].

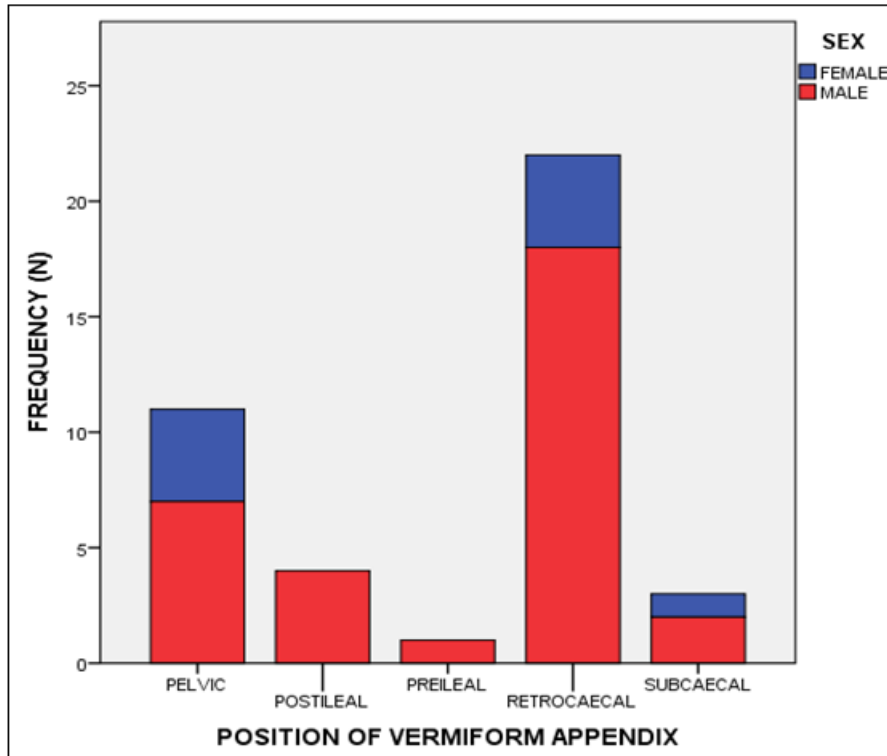


Fig-1: A Bar Chart Showing the Frequency of Occurrence of the Various Positions of the Vermiform Appendix in Sexes

Length of the vermiform appendix

Table-3: Length of Vermiform Appendix in the Total Population (N=41)

	Length (cm) in Males	Length (cm) in Females
Mean \pm SD	8.80 \pm 0.92	8.36 \pm 0.73
Std. Error of mean	0.16	0.24
Median	8.80	8.60
Minimum	7.10	7.60
Maximum	11.70	9.70

Table-4: Length of Vermiform Appendix in the Vermiform Appendix (Males = 32 & Females = 9)

	Length (cm)
Mean \pm S.D	8.70 \pm 1.40
Median	8.60
Maximum	7.10
Minimum	11.70
Standard Error of Mean	1.40

The average length of the vermiform appendix from this present study was 8.7 \pm 1.4cm. The mean \pm S.D for male category was 8.80 \pm 0.92cm while that of the female category was 8.36 \pm 0.73. This is in close

proximity with the findings of Ajmani and Ajmani who found out that the average length of the appendix as 9.5 cm in males and 8.7 cm in females [14]. Buschard and Kjaeldgaard reported that the length of the vermiform

appendix varies from 2 cm to 20 cm, with an average length of 9 cm [15]. These differences may be either due to genetic factors or lifestyle factors like nutritional regimens [16].

From the results, the statistical level of association in sexual dimorphism revealed that there was no relationship between the variables since $P > 0.05$.

CONCLUSION

This study has revealed the average length of vermiform appendix in Nigeria to be 8.7 ± 0.89 cm with the males and females measuring 8.80 ± 0.92 cm and 8.36 ± 0.73 cm respectively with no statistical level of association in sexual dimorphism. The prevalent position of vermiform appendix from this study is the retrocaecal position while the least prevalent is paracaecal. The relationship of vermiform appendix to the caecum of taenia coli was still the constant position arising from the confluence of the three longitudinal bands of the taenia coli.

Acknowledgements

We appreciate everyone who assisted us in course of the research, members of staff of the Department of Anatomy, University of Port Harcourt, Nigeria.

Source of funding

Self-funding

Conflict of interest

We write to state that there is no conflict of interest.

REFERENCES

1. Chaurasia, B. D. (2004). *Human anatomy; Regional and applied*. 4th edition. CBS Publishers and distributors. New Delhi. 223.
2. Shruthi, B. N., Balakrishna., & Shubha, R. (2013). Promonteric Position of Vermiform Appendix and its Vasculature: A Case Report. *Journal of Medical and Health Sciences*, (1):1-4
3. Wakeley, C. P. (1933). The position of the vermiform appendix as ascertained by an analysis of 10,000 cases. *Journal of anatomy*, 67(1), 277-283.
4. Manisha, C., Kapadia, D. M., Kanani, S. D., Patel, J. P., & Shah, R. K. (2013). A study of morphology of vermiform appendix in 200 cases. *International Journal of Medical Research and Health Sciences*, 2(4), 780-785.
5. Ojeifo, J. O., Ejiwunmi, A. B., & Iklaki, J. (1989). The position of the vermiform appendix in Nigerians with a review of the literature. *West African journal of medicine*, 8(3), 198-204.
6. Abegaz, B. A., Woldeyes, D. H., Awoke, D. G., & Kiros, M. D. (2016). A study of the variations of positions of vermiform appendix in appendicitis patients in Northern Ethiopia. *Journal of Experimental and Clinical Anatomy*, 15(2), 73.
7. Mwachaka, P., El-busaidy, H., Sinkeet, S., & Ogeng'o, J. (2014). Variations in the position and length of the vermiform appendix in a black Kenyan population. *East African medical journals*, 1(1): 1-5.
8. JA, A., & Ibrahim, N. A. (2012). Anatomical variations of appendix in patients with acute appendicitis among two major tribes in Lagos Nigeria. *International Journal of Medicine and Medical Sciences*, 2(3), 72-76.
9. Zern, J. T. (1995). The appendix: little, big trouble. *Delhi Medical Journals*, 67(1): 326-334.
10. Patel, S., & Naik, A. (2016). Anatomical variations in the vermiform appendix: *Journal of dental and medical sciences*, 15(4): 106-109.
11. Clegg-Lamprey, J. N., Armah, H., Naaeder, S. B., & Adu-Aryee, N. A. (2006). Position and susceptibility to inflammation of vermiform appendix in Accra, Ghana. *East African medical journal*, 83(12), 670-678.
12. Golalipour, M. J., Arya, B., Azarhoosh, R., & Jahanshahi, M. (2003). Anatomical variations of vermiform appendix in south-east Caspian sea (Gorgan-Iran). *J Anat Soc India*, 52(2), 141-143.
13. Katzarski, M., Gopal, U. R., & Brady, K. (1979). Blood supply and position of the vermiform appendix in Zambians. *Medical journal of Zambia*, 13(2), 32-34.
14. Ajmani, M. L., & Ajmani, K. (1983). The position, length and arterial supply of vermiform appendix. *Anatomischer anzeiger*, 153(4), 369-374.
15. Buschard, K., & Kjaeldgaard, A. (1973). Investigation and analysis of the position, fixation, length and embryology of the vermiform appendix. *Acta Chirurgica Scandinavica*, 139(3), 293-298.
16. Tofighi, H., Taghadosi-Nejad, F., Abbaspour, A., Behnoush, B., Salimi, A., Dabiran, S., ... & Okazi, A. (2013). The anatomical position of appendix in Iranian cadavers. *International journal of medical toxicology and forensic medicine*, 3(4), 126-130.