

## Disease Von Hippel-Lindau: About A Case and Review of the Literature

A. El Ouafi\*, F. El Alami, A. Bouzidi, S. Iferkhas, A. Laktaoui

Ophthalmology Service Military Hospital Moulay Ismail Meknes, Morocco

\*Corresponding author: A. El Ouafi

| Received: 10.12.2018 | Accepted: 19.12.2018 | Published: 28.02.2019

DOI: [10.36348/sjmpps.2019.v05i02.012](https://doi.org/10.36348/sjmpps.2019.v05i02.012)

### Abstract

**Introduction:** Von Hippel-Lindau disease (VHL) is a multi-systemic disease characterized by abnormal multiplication of blood vessels, with haemangioblastomas and cysts, as well as other neoformations in the blood Several organs. We report the case of a patient; we try to put the point on this pathology. **Case Report:** 14-year-old patient, consults for a BAV of the OD whose examination finds an intra vitreous haemorrhage,retinal capillary haemangioma and a lower exudative retinal detachment. The patientreceived an IVT of anti VEGF initially followed by an endocular surgery. Postoperative visual acuity was not improved with a follow-up of 6 months. **Discussion:** The clinical definition of VHL disease is based on the presence of two major lesions, one of which is hemangioblastoma. The absence of family history, or a single injury in the presence of a family history. Complementary examination is based on angiographyto fluorescein. Complications can range from simple exudates to DR or even phtyse of the globe. The treatmentis essentially based on argon laser coagulation, cryotherapy, anti-VEGF and retinovitealstage of complications. **Conclusion:** VHL is a hereditary disorder with multi-systemic involvement, hence the interest of an examination complete follow-up, regular monitoring and genetic counseling in any patient suspected of having the diseaseas well as his family.

**Keywords:** Von, Hippel-Lindau, disease, (VHL).

**Copyright © 2019:** This is an open-access article distributed under the terms of the Creative Commons Attribution license which permits unrestricted use, distribution, and reproduction in any medium for non-commercial use (Non-Commercial, or CC-BY-NC) provided the original author and source are credited.

### INTRODUCTION

Von Hippel Lindau disease (VHL) is a syndrome precancerous family with autosomal dominant inheritance, several organs can be affected: eye, CNS, liver, kidney, spleen, pancreas ...Retinal angiomas is the manifestation eyepiece the most common. The diagnosis of this condition is clinical, confirmed by genetics. Treatment and prognosisvisual depend on the location of the hemangioma and the occurrence of complications.

We report the case of a patient followed for the disease from VHL. Through this observation, we try to put the point on this pathology, in order to understand its physiopathology, recognize the means of clinical and paraclinical diagnosis, complications and therapeutic.

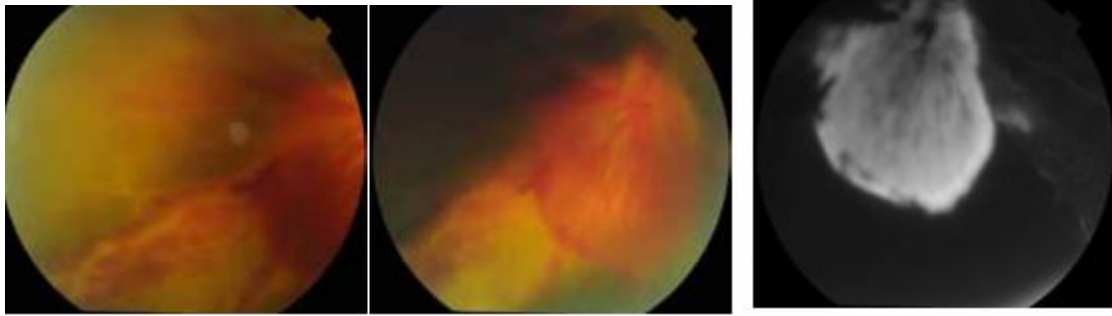
### CASE REPORT

A 14-year-old patient from a consanguineous marriage consults for a decrease in the visual acuity of the right eye whose examination finds a visual acuity

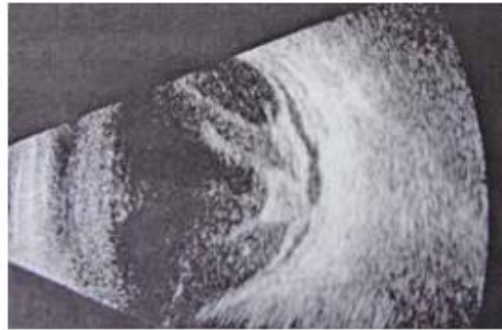that cannot be improved to see the hand move, a normal anterior segment, a fund of the eye showing inferior vitreous hemorrhage with a juxtapapillary capillary haemangioma and a lower exudative retinal detachment (DR) (Fig-1). In the left eye, visual acuity is at 10/10 and the rest of the exam is strictly normal.

Fluorescein angiography is performed and confirms the diagnosis with the presence of retinal angiomas. Ocular ultrasound shows intra vitreous haemorrhageand retrohyaloid dense lower with membrane sextensive fibrovascular associated with a tractional DR localised inferior (Fig-2). Abdominal ultrasound shows thepresence of right renal cyst. A brain MRI does not show no lesions in the central nervous system. The patient received an intravitreous injection of anti-VEGF first followed by endocular surgery.

Postoperative visual acuity has not been improved with a minimum of six months.



**Fig-1: Angiographic images showing angioma papillary capillary**



**Fig-2: Ultrasound appearance of associated papillary angioma intravitreal haemorrhage**

## DISCUSSION

Von Hippel-Lindau disease is a multi-systemic disease autosomal dominant, characterized by a multiplication of abnormal blood vessels, with hemangioblastomas and cysts, as well as other neoplasms in several organs. With the exception of renal cell carcinoma, all these tumors are benign. The incidence is 3 per 100,000 and the average age of discovery is 25 years. The disease is due to a mutation of the VHL gene, which is part of tumor suppressor genes located on the short arm of chromosome 3 [1, 2]. The six major lesions are hemangioblastoma of the neuraxis (mainly cerebellum and spinal cord) [3], hemangioblastoma of the retina, clear cell renal cancer and / or renal cysts [4], pheochromocytoma [5], cysts and / or pancreatic neuroendocrine tumors [6] and tumor of the endolymphatic sac [7]. The clinical definition is based on the presence of two major lesions including a hemangioblastoma in the absence of family history, or a single lesion in the presence of a family history. Differential diagnosis is essentially represented by the sporadic forms of tumors observed during VHL disease, it is necessary to systematically search for the condition, especially in a subject young or when they are multiple [8]. Regarding ocular involvement, retinal hemangioblastoma is characteristic and indicative of the disease in 30% of cases [1]. It manifests itself either by an endophytic hemangioma;

It starts in chronological order by a small lesion red located in the capillary bed between an arteriolar and an arteriole, becoming a small nodule well delimited, thereafter a round orange-yellow mass with dilatation and tortuosity of the feeder artery and drainage vein for at last, become a white fibrous

angioma, devoid of vessels; or a juxtapapillary exophytic hemangioma, less frequent, from the external retina [1]. Angiography with fluorescein shows an early hyperfluorescence and leakage. Complications are represented by hard exudates surrounding the tumor or macula [9], macular edema and cellophane maculopathy, retinal detachment traction, rhegmatogenous or exudative, intravitreal hemorrhage, secondary glaucoma and phthisis of the globe. The classification of Vail [9] defined 4 stages,

Stage I: Formation of angiomas and retinal arteriovenous dilatation,

Stage II: Appearance of hemorrhages and lipid deposits forming a macular star or retinitis circled around the tumor

Stage III: Massive exudation and detachment of the retina and

Stage IV: Absolute glaucoma, uveitis and visual loss.

The management of ocular involvement, includes several modalities, including photodynamic therapy for small peripheral lesions [10], with the condition of absence of fibrosis and exaggerated vitreomacular tractions [11], intense and long impacts of 200 to 400  $\mu\text{m}$  (0.5 to 1 second) to penetrate deeply into the angioma, they are repeated as necessary until the sustainable treatment of the angioma, it is necessary to avoid the vein of drainage with possibility of impact on the feeder artery to reduce flow, the index of success is the regression of exudation, fibrosis, and the normalization of the caliber of the vessels. Cryotherapy

can be helpful for larger peripheral lesions size or in case of associated exudative retina detachment [9]. Brachytherapy reserved for larger lesions [12-14]. Retinovitreal surgery is being considered for severe cases of retinal capillary haemangioblastomas associated with serous DR, vascularized pre-retinal fibrosis or not and neo-vessels on the tumor or pre-papillary [14-17]. And finally, anti-VEGF systemically [18] or intravitreal [14] but of low efficiency. Disease surveillance should be annual, and should include a physical, ophthalmologic examination from 5 years, and half-yearly between 10 and 30 years, an ultrasound scan from 16 years, and 24h urine to detect pheochromocytoma from 10 years old. Screening every two years with abdominal and cerebral MRI from the age of 15 years old. Genetic counseling is indicated in all patients with whom the disease is suspected and with their families.

## CONCLUSION

VHL disease is a hereditary condition with multi systemic where the interest of a complementary examination comprehensive, regular monitoring and genetic counseling in any patient whose disease is suspected.

## REFERENCES

- Webster, A. R., Maher, E. R., & Moore, A. T. (1999). Clinical characteristics of ocular angiomas in von Hippel-Lindau disease and correlation with germline mutation. *Archives of Ophthalmology*, 117(3), 371-378.
- Richards, F. M., Webster, A. R., McMahon, R., Woodward, E. R., Rose, S., & Maher, E. R. (1998). Molecular genetic analysis of von Hippel-Lindau disease. *Journal of internal medicine*, 243(6), 527-533.
- Richard, S., Campello, C., Taillandier, L., Parker, F., & Resche, F. (1998). Haemangioblastoma of the central nervous system in von Hippel-Lindau disease. French VHL Study Group. *Journal of internal medicine*, 243(6), 547-553.
- Neumann, H. P., Bender, B. U., Berger, D. P., Laubenberger, J., Schultze-seemann, W., Wetterauer, U., ... & LIPS JM, C. O. R. N. E. L. I. S. (1998). Prevalence, morphology and biology of renal cell carcinoma in von Hippel-Lindau disease compared to sporadic renal cell carcinoma. *The Journal of urology*, 160(4), 1248-1254.
- Eisenhofer, G., Lenders, J. W., Linehan, W. M., Walther, M. M., Goldstein, D. S., & Keiser, H. R. (1999). Plasma normetanephrine and metanephrine for detecting pheochromocytoma in von Hippel-Lindau disease and multiple endocrine neoplasia type 2. *New England Journal of Medicine*, 340(24), 1872-1879.
- Neumann, H. P., Dinkel, E., Brambs, H., Wimmer, B., Friedburg, H., Volk, B., ... & Wiestler, O. D. (1991). Pancreatic lesions in the von Hippel-Lindau syndrome. *Gastroenterology*, 101(2), 465-471.
- Choo, D., Shotland, L., Mastroianni, M., Glenn, G., van Waes, C., Linehan, W. M., & Oldfield, E. H. (2004). Endolymphatic sac tumors in von Hippel-Lindau disease. *Journal of neurosurgery*, 100(3), 480-487.
- Müller, H., Bürki, N., Gillissen, S., Gürtler, M., Imhof, H. G., Keller, U. O., ... & Trutmann, E. (2006). La maladie de von Hippel-Lindau (VHL): diagnostic et traitement. In *Forum Médical Suisse*, 6(3), 70-76. EMH Media.
- Wong, W. T., & Chew, E. Y. (2008). Ocular von Hippel-Lindau disease: clinical update and emerging treatments. *Current opinion in ophthalmology*, 19(3), 213-217.
- Lane, C. M., Turner, G., Gregor, Z. J., & Bird, A. C. (1989). Laser treatment of retinal angiomas. *Eye*, 3(1), 33-38.
- Schmidt, D., Natt, E., & Neumann, H. P. H. (2000). Long-term results of laser treatment for retinal angiomas in von Hippel-Lindau disease. *European journal of medical research*, 5(2), 47-58.
- Atebara, N. H. (2002). Retinal capillary hemangioma treated with verteporfin photodynamic therapy. *American journal of ophthalmology*, 134(5), 788-790.
- Kreusel, K. M., Bornfeld, N., Lommatzsch, A., Wessing, A., & Foerster, M. H. (1998). Ruthenium-106 brachytherapy for peripheral retinal capillary hemangioma. *Ophthalmology*, 105(8), 1386-1392.
- Mennel, S., Meyer, C. H., & Callizo, J. (2010). Combined intravitreal anti-vascular endothelial growth factor (Avastin®) and photodynamic therapy to treat retinal juxtapapillary capillary hemangioma. *Acta ophthalmologica*, 88(5), 610-613.
- Gaudric, A., Korobelnik, J. F., Quentel, G., & Coscas, G. (1987). Traitement du décollement de rétine au cours de l'angiomasose de von Hippel: à propos de deux cas. *Bulletin des sociétés d'ophtalmologie de France*, 87(12), 1357-1358.
- Gaudric, A., Krivosic, V., Duguid, G., Massin, P., Giraud, S., & Richard, S. (2011). Vitreoretinal surgery for severe retinal capillary hemangiomas in von Hippel-Lindau disease. *Ophthalmology*, 118(1), 142-149.
- McDonald, H. R., Schatz, H., Johnson, R. N., Abrams, G. W., Brown, G. C., Brucker, A. J., ... & Meyers, S. (1996). Vitrectomy in eyes with peripheral retinal angioma associated with traction macular detachment. *Ophthalmology*, 103(2), 329-335.
- Girmens, J. F., Erginay, A., Massin, P., Scigalla, P., Gaudric, A., & Richard, S. (2003). Treatment of von Hippel-Lindau retinal hemangioblastoma by the vascular endothelial growth factor receptor inhibitor SU5416 is more effective for associated

macular edema than for  
hemangioblastomas. *American journal of*  
*ophthalmology*, 136(1), 194-196.