

# Comparative Study of Corneal Endothelial Cell Loss in Phacoemulsification and Manual Small Incision Cataract Surgery (MSICS)

Dr. R. S Chauhan<sup>1\*</sup>, Ashok Rathi<sup>1</sup>, J. P Chugh<sup>1</sup>, Twinky Bhutia<sup>2</sup>, Apoorva Goel<sup>3</sup>

<sup>1</sup>Professor, Regional Institute of Ophthalmology, Pt. B. D. Sharma, Postgraduate Institute of Medical Sciences, Rohtak, India

<sup>2</sup>Regional Institute of Ophthalmology, Pt. B. D. Sharma, Postgraduate Institute of Medical Sciences, Rohtak, India

<sup>3</sup>Resident, Regional Institute of Ophthalmology, Pt. B. D. Sharma, Postgraduate Institute of Medical Sciences, Rohtak, India

\*Corresponding author: Dr. R. S Chauhan

| Received: 07.02.2019 | Accepted: 16.02.2019 | Published: 28.02.2019

DOI: [10.36348/sjmpps.2019.v05i02.007](https://doi.org/10.36348/sjmpps.2019.v05i02.007)

## Abstract

A comparative analysis of endothelial cell loss was done after manual small incision cataract surgery and phacoemulsification with 50 patients in each group in a tertiary care eye hospital in India. Follow up was done upto 8 weeks for visual acuity, mean endothelial cell density, corneal thickness and change in hexagonality. Analysis was done on TOPCON- 3000P specular microscope. Males and females were equally distributed mainly in 51-60 years of age group. The visual acuity in group A (phacoemulsification) was 6/6 in 68% patients while in group B it was 6/6 in 40% patients. There was more decrease in mean endothelial cell density in group A (phacoemulsification) 4.24% vs 3.87%. Corneal edema occurred in both the groups initially but was not statistically significant. The overall loss of hexagonal cells is not statistically significant between phacoemulsification and manual small incision cataract surgery. All through our study, there was more corneal edema, endothelial cell loss and decrease in hexagonality in phacoemulsification group. However, the difference was not statistically significant. Hence, both the surgeries are safe pertaining to corneal endothelial health.

**Keywords:** Phacoemulsification, Manual small incision cataract surgery (MSICS), Endothelial cell, Central corneal thickness, Hexagonal cells, Specular microscope.

**Copyright © 2019:** This is an open-access article distributed under the terms of the Creative Commons Attribution license which permits unrestricted use, distribution, and reproduction in any medium for non-commercial use (Non-Commercial, or CC-BY-NC) provided the original author and source are credited.

## INTRODUCTION

Cornea is a transparent, avascular outermost layer of the eye which has further six layers namely the epithelium, bowman's membrane, stroma, pre-desemet's layer, descemet's membrane and the endothelium. Corneal Endothelium is a Monolayer of hexagonal cells which is rich in mitochondria. There are 5,00,000 endothelial cells per cornea and the Adult density is 2500 cells/mm sq approximately. Functions of corneal endothelium include Regular fluid and solute transport and Maintenance of corneal optical transparency via Active Na/K ATPase Pump. Thickness of cornea Reaches adult size by 3 years of age. Thereafter, there is a gradual but insignificant decrease in the thickness of this tissue. The rate of corneal deswelling after edema which is measured as percentage recovery per hour is significantly higher in young patients than in older ones [1-4].

Intraocular surgeries are one of the leading cause of endothelial injury and cataract surgeries comprise of 80% eye surgeries. With time cataract

surgeries have undergone abundant changes and now-a-days sutureless surgeries like MSICS and ultrasonic phacoemulsification have replaced conventional intacapsular surgeries. Conventional surgeries had a relatively higher incidence of intraocular infection, slower rate of visual recovery and higher post operative astigmatism [5, 6].

Phacoemulsification refers to modern cataract surgery which uses ultrasonic energy during which the phaco probe moves at a speed of 40,000 times/sec., which emulsify the lens & aspirates it through a 2.8-3.2mm incision and allows foldable IOL implantation. The benefit being faster functional and morphological recovery. On the other hand the hallmark of manual small incision cataract surgery is its self sealing tunnel architecture with an incision size of 6.0-6.5 mm which necessitates larger incision than phaco and rigid IOL implantation.

In both the surgeries, the surgical trauma leads to endothelial cell loss. The traumatized endothelium

continues to loose cells and endothelial dysfunction may develop gradually years after the surgery. It has been seen that after surgical trauma the human endothelium shows practically no proliferative activity and the damaged area is covered by means of cell migration [7, 8]. There is a definitive correlation between the endothelial cell density and the corneal thickness as moderate damage to corneal endothelium during the surgery can cause a transient increase in corneal thickness.

Corneal endothelial cell loss can be measured with different instruments, including contact specular microscopes, non-contact specular microscopes (NCSM), and confocal microscopes while Central corneal thickness can be assessed by various techniques such as USP, Orbscan, contact specular microscopy, NCSM and Pentacam. The availability of quick, accurate, non invasive methods of CCT assessment is essential for the effective monitoring of corneal endothelial health. One such technique widely used is the new automated noncontact specular microscope (NCSM) Topcon SP-3000P (Topcon Corporation, Tokyo, Japan), which captures an image of the corneal endothelium and assesses corneal thickness simultaneously [9, 10].

To evaluate the degree of surgical trauma, endothelial status and corneal edema, a detailed study of corneal thickness and endothelial cell count was carried out in both types of cataract surgeries.

## MATERIALS & METHODS

### Study Design

- This case-control study was conducted in Regional Institute of Ophthalmology (RIO), Pt. B.D. Sharma PGIMS, Rohtak over a span of 1 year.
- The study group consisted of 100 patients which were further divided into two groups (A & B) of 50 eyes each who had undergone phacoemulsification and SICS respectively.

### Inclusion Criteria

- Age >50 years who agreed to have surgery and were willing to complete the schedule of postoperative follow up were included in this study.

### Exclusion Criteria

- Traumatic or complicated cataract
- Co-existing glaucoma
- History of chronic ocular inflammation
- History of prior surgery
- Patients with nuclear sclerosis
- Frequent use of any eye drops other than preservative free artificial tears.

### Preoperative evaluation

Informed and written consent was taken from all patients. Detailed history regarding age, gender, any previous history of any ocular trauma, surgery, usage of eye drops if any was taken. Complete ocular examination was performed including best corrected visual acuity using Snellen's acuity chart, anterior and posterior segment examination by slit lamp examination, intraocular pressure measurement and fundus examination. The corneal endothelial cell counts, frequency of hexagonal cells and central corneal thickness were analyzed using Topcon SP 3000 P Specular microscope.

### Methodology

#### Preoperative Medication

- Tablet acetazolamide and alprazolam was given a night before surgery and one hour before surgery.
- Topical broad spectrum antibiotic drops were instilled 3-4 times a day before surgery.
- Topical NSAIDS drops were given 3-4 times the day before surgery to prevent inflammation and intraoperative miosis.
- A combination of tropicamide 0.8% and phenylephrine 5% eye drops were instilled 3-4 times an hour before surgery to achieve mydriasis.

#### Anaesthesia

All patients were operated under topical anaesthesia. The anaesthetic solution used was lignocaine 2% and bupivacaine 0.5% with hyaluronidase 5 IU/ml mixed with 1 in 1 lac adrenaline.

#### Surgical Procedure

In group A phacoemulsification was performed where a 2.8-3.2 mm temporal clear corneal incision was given and a self sealing tunnel was made. Anterior chamber was entered with the help of a 3.2 mm keratome and was maintained using the viscoelastic hydroxypropyl methylcellulose. Continuous curvilinear capsulorhexis was done with a 26 G needle which was followed by hydrodissection and hydrodelineation. Sideport was made two to three clock hours away from mainport to provide entry to the second instrument used to manipulate the lens. Nucleus was emulsified in posterior chamber which was followed by removal of endonucleus. Cortex and epinucleus were aspirated. Foldable posterior chamber IOL was implanted and dialed and stromal hydration was done to prevent wound leak. Subconjunctival gentamycin and dexamethasone was given. Patch and bandage was done.

In group B small incision cataract surgery was performed where a 6.0-6.5 mm frown shaped incision was given and a self sealing partial thickness sclera tunnel was formed and the tunnel extended approximately 1.0-1.5 mm in cornea. The anterior chamber was entered with the help of a 3.2 mm keratome. Trypan blue dye was injected and washed

with ringer lactate to stain the anterior capsule of the lens. Anterior chamber was maintained using the viscoelastic Hydroxypropyl methylcellulose. Continuous curvilinear capsulorhexis was done with a 26 G needle. Hydrodissection was done and the nucleus was prolapsed in the anterior chamber which was expressed out using irrigating wire vectis. The epinucleus and the residual cortical matter was aspirated using a two way irrigation and aspiration cannula. Rigid PMMA PCIOL was implanted in the bag and dialed. Stromal hydration was done to prevent wound leak. The conjunctival flap was replaced over the incision and the edges were opposed with a cautery. Subconjunctival gentamycin and dexamethasone was given in the end.

### Postoperative Evaluation

Bandage was opened on the next day and the eye was cleaned with aseptic care. Postoperative evaluation included- best corrected visual acuity, slit lamp examination, centering of IOL, fundal glow, digital tonometry and specular microscopy.

### Postoperative Medications

It included oral antibiotics, oral analgesics, acetazolamide, topical antibiotics, topical cycloplegics and topical NSAIDS.

### Follow Up

After postoperative day 1 subsequent follow ups were done after 1 week and 8 weeks after surgery. All the postoperative follow ups included evaluation of best corrected visual acuity, slit lamp examination, centering of IOL, fundal glow, digital tonometry and specular microscopy to analyse corneal endothelial cell count, central corneal thickness and hexagonal cells.

### Statistical Analysis

At the end of the study the above parameters were compared and analyzed using Student's t-test (paired and unpaired).

## OBSERVATIONS AND RESULTS

The present study was conducted in regional institute of ophthalmology, Pt. B.D. Sharma PGIMS Rohtak. It was a case control study in which the study group included 100 patients which were further divided into two groups (A & B) of 50 eyes each who had undergone phacoemulsification and SICS respectively. The study was conducted to compare the safety profile of phacoemulsification and SICS on cornea.

**Table-1: Demographic profile**

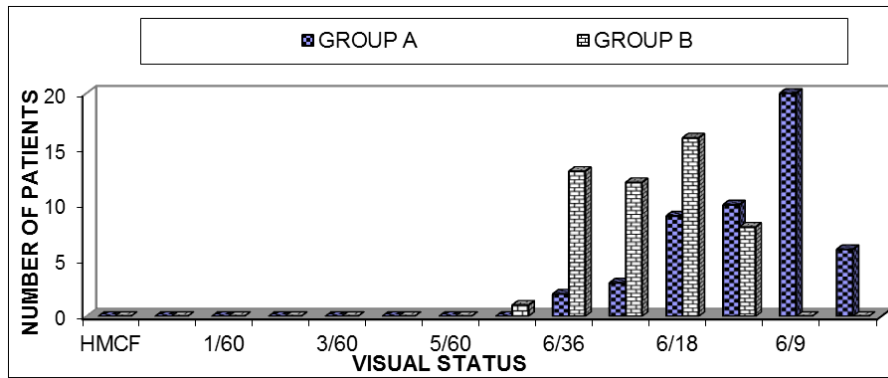
	Group A (Phacoemulsification)	Group B ( SICS)
Age (50-60 years)	70%	80%
Sex (Male: Female)	56:44	52:48
Socio economic Status (Low)	60%	70%
Cataract (Grade I:Grade II)	54:46	38:62

Table-1 shows that maximum patients undergoing cataract surgery were in age group of 51-80 years. Maximum number of patients 35(70%) in group A and 40(80%) in group B were in the age group of 51-60 years. Out of 50 patients, 28 patients (56%) were male and 22 patients (44%) were female in group A while 26 patients (52%) were male and 24 patients

(48%) were female in group B. Most of the patients i.e. 60% belonged to low socio economic status in group A while 70% patients in group B belonged to low socio economic. Most of the patients, 23 out of 50 (46%) in group A were having grade 2 nuclear cataract while 19 out of 50 (38%) in group B had grade 1 nuclear cataract.

**Table-2: Visual status after one week of surgery**

Visual Status	Group A (Phacoemulsification) N=50	Group B (MSICS) N=50
6/6	6(12%)	0
6/9	20(40%)	0
6/12	10(20%)	8(16%)
6/18	9(18%)	16(32%)
6/24	3(6%)	12(24%)
6/36	2(4%)	13(26%)
6/60	0	1(2%)



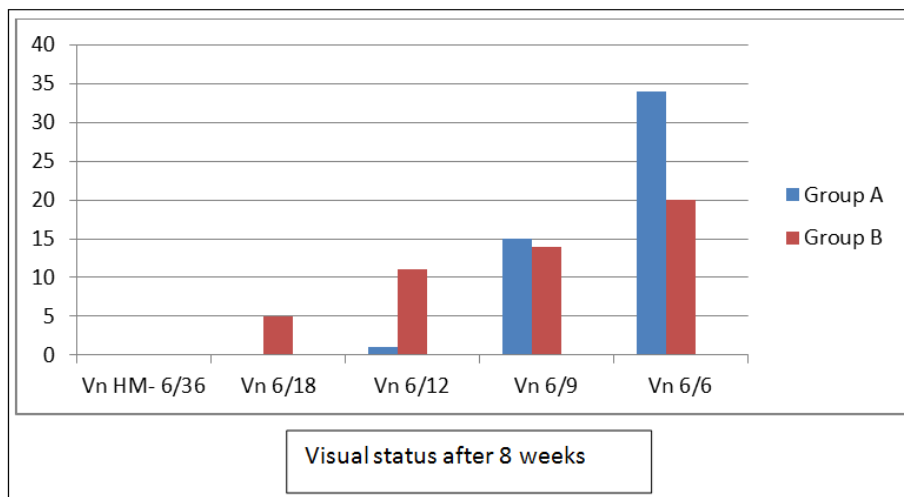
**Fig-1: Graph Showing Visual Status after 1st Week of Surgery**

Table-2 and Figure-1 show that at first week of follow up, maximum number of patients (40%) had BCVA of 6/9 in group A and in group B maximum

number of patients (32%) had BCVA of 6/18. Maximum vision recorded in Group A was 6/36 and 6/60 in Group B.

**Table-3: Visual status after 8 weeks of surgery**

Visual Status	Group A (Phacoemulsification)	Group B (SICS)
6/6	34(68%)	20(40%)
6/9	15(30%)	14(28%)
6/12	1(2%)	11(22%)
6/18	0	5(10%)



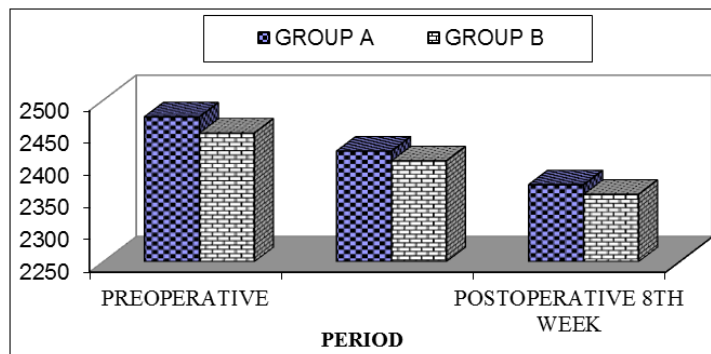
**Fig-2: Visual Status after 8 weeks in both groups**

Table-3 and Figure-2 show that after 8 weeks of surgery, maximum number of patients (68%) in group A had 6/6 BCVA while 40% patients in group B

had 6/6. Minimum BCVA in group A (2%) was 6/12 and in group B (10%) was 6/18.

**Table-4: Mean endothelial cell density in both groups**

Period	Group A (Phacoemulsification)	Group B (MSICS)
Preoperative	2474	2449
P.O. 1 <sup>st</sup> week	2421 (↓2.14%)	2406 (↓1.75%)
P.O. 8 <sup>th</sup> week	2369 (↓4.24%)	2354 (↓3.87%)



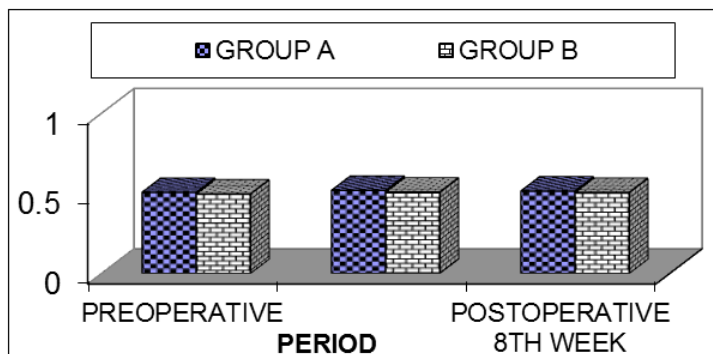
**Fig-3: Graph Showing Mean Endothelial Cell Density GROUP A VS. GROUP B**

Table-4 and Figure-3 show the mean endothelial cell density in the preoperative period and at the end of 1 week and 8 weeks of surgery. It was observed that one week after surgery in group A, the endothelial cell density had decreased by 2.14% while the decrease was 4.24% at the end of 8<sup>th</sup> week after

surgery. In group B the corresponding decrease was observed to be 1.75% after 1<sup>st</sup> week and 3.87% after 8 weeks of surgery. When statistical analysis was done the decrease in endothelial cell density between the two groups was found to be statistically insignificant.

**Table-5: Mean corneal thickness in both the groups**

Period	Group A (Phacoemulsification)	Group B (SICS)
Preoperative	0.506 mm	0.496mm
P.O.1 <sup>st</sup> week	0.518mm (↑2.37%)	0.507mm (↑2.21%)
P.O.8 <sup>th</sup> week	0.514mm (↑1.58%)	0.505mm (↑1.81%)



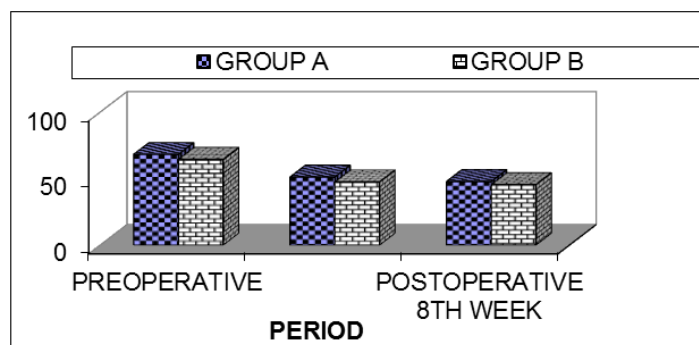
**Fig-4: Graph Showing Mean Corneal Thickness GROUP A VS. GROUP B**

Table-5 and Figure-4 shows that when the mean corneal thickness was observed in the pre-operative period, at the end of 1<sup>st</sup> and 8<sup>th</sup> week of surgery, in group A the mean corneal thickness had increased by 2.37% at the end of one week of surgery. However, over the next few weeks, the corneal thickness decreased and at the end of 8 weeks of

surgery, the increase in the corneal thickness was 1.58% of the preoperative values. Corresponding increase in group B was 2.21% and 1.81% at the end of 1<sup>st</sup> and 8<sup>th</sup> week of surgery. When statistical analysis was done the increase in the corneal thickness between the two groups was found to be statistically insignificant.

**Table-6: Mean hexagonal cells in both the groups**

Period	Group A (phacoemulsification)	Group B (SICS)
Preoperative	68.19	64.44
P.O.1 <sup>st</sup> week	51.20 (↓33.18%)	47.49 (↓35.69%)
P.O. 8 <sup>th</sup> week	47.82 (↓42.59%)	45.49 (↓41.64%)



**Fig-5: Graph Showing Mean Hexagonal Cells (In Percent) GROUP A VS. GROUP B**

Table-6 and Figure-5 shows the mean hexagonal cells in preoperative period, at the end of 1<sup>st</sup> week and 8<sup>th</sup> week post surgery. It was observed that in group A as compared to the preoperative percentage of hexagonal cells there was a decrease of 33.18% of hexagonal cells at the end of one week of surgery and a total decrease of 42.59% at the end of 8<sup>th</sup> week post surgery. In group B the corresponding decrease was observed to be 35.69% and 41.64% at the end of 1<sup>st</sup> and 8<sup>th</sup> week of surgery. Hence, there was a gradual decrease in the hexagonal cells postoperatively in both the groups. When statistical analysis was done the decrease in the hexagonal cells postoperatively between the two groups was found to be statistically insignificant.

## DISCUSSION

Endothelium is physiologically the most active layer of cornea and its cells undergo a decrease in their density after any intraocular surgery and as cataract surgery is one of the most commonly performed intraocular surgery. Hence, it is very important to determine its role in causing endothelial insult.

In our study, the mean age of patients in group A was  $57.28 \pm 5.8$  years and in group B  $58.48 \pm 7.2$  years. These results are almost similar to the study done by Gogate P *et al.*, in which the mean age of patients in phacoemulsification group was 63.7 years and in SICS group was 62.7 years [11]. In a study done by Trnavec B *et al.*, on 26 patients, the mean age of patients in phacoemulsification group was 69.3 years and in SICS group was 70.7 years [12].

In our study, out of 100 patients, 54 patients were males and 46 were females. In a similar study performed by Ramalingam MDK *et al.*, out of 160 patients, 84 patients were males and 76 patients were female [13].

In our study, out of 100 patients, 65 patients belonged to low socioeconomic status. Similar results have been reported by Nowak R [14].

In our study 23 out of 50 (46%) patients in group A were having grade 2 nuclear cataract while 19

out of 50 (38%) patients in group B had grade 1 nuclear cataract. This is comparable to the study done by Ramalingam MDK *et al.*, where out of 80 patients, 23 (28.75%) had grade 2 nuclear cataract in group A and 19 out of 80 patients (23.75%) in group B had grade 3 nuclear cataract [13].

In our study, at first week of follow up, maximum number of patients (40%) had BCVA of 6/9 in group A and in group B maximum number of patients (32%) had BCVA of 6/18. Maximum vision recorded in Group A was 6/36 and 6/60 in Group B after 8 weeks of surgery, maximum number of patients (68%) in group A had 6/6 BCVA while 40% patients in group B had 6/6. Minimum BCVA in group A (2%) was 6/12 and in group B (10%) was 6/18. Our results are comparable with those reported by Ravalico G *et al.*, in which 20 patients were operated by phacoemulsification and 20 patients were operated by SICS. Though the visual acuity was better 7 days after phacoemulsification, after 30 days no difference was observed in the visual outcome between the two groups [15].

The mean endothelial cell density in the preoperative period and at the end of 1 week and 8 weeks of surgery were analysed in our study. It was observed that one week after surgery in group A, the endothelial cell density had decreased by 2.14% while the decrease was 4.24% at the end of 8<sup>th</sup> week after surgery. In group B the corresponding decrease was observed to be 1.75% after 1<sup>st</sup> week and 3.87% after 8 weeks of surgery. Trnavec B *et al.*, [12] did a similar comparative study on endothelial cell loss after phaco and SICS in which the endothelium was examined one day after operation and the 7<sup>th</sup> to 10<sup>th</sup> day after operation. It was observed that there was a decrease in the endothelial cell density after operation in group A (16.43%) and also in group B (18.53%). However, this difference was not significant. In another study conducted by Ohrloff C *et al.*, [16], the mean endothelial cell loss after phacoemulsification was 7.9% and after SICS was 7.1%. A study done by Stumpf S *et al.*, [17] shows no significant difference in the endothelial loss pre and postoperatively when compared between phacoemulsification and SICS.

In our study when the mean corneal thickness was observed in the pre-operative period, at the end of 1<sup>st</sup> and 8<sup>th</sup> week of surgery, in group A the mean corneal thickness had increased by 2.37% at the end of one week of surgery. However, over the next few weeks, the corneal thickness decreased and at the end of 8 weeks of surgery, the increase in the corneal thickness was 1.58% of the preoperative values. Corresponding increase in group B was 2.21% and 1.81% at the end of 1<sup>st</sup> and 8<sup>th</sup> week of surgery. Srinivasan et al performed a similar study in which they concluded that though there was an initial loss of endothelial cells, increase in the corneal thickness and changes in cell morphology, the values returned to near normal within 3 months of surgery [18]. Similar results were shown in the studies conducted by Binder P *et al.*, Polack F *et al.*, Lundberg and Schultz R *et al.*, [19-22].

In our study, the mean hexagonal cells in preoperative period, at the end of 1<sup>st</sup> week and 8<sup>th</sup> week post surgery. It was observed that in group A as compared to the preoperative percentage of hexagonal cells there was a decrease of 33.18% of hexagonal cells at the end of one week of surgery and a total decrease of 42.59% at the end of 8<sup>th</sup> week post surgery. In group B the corresponding decrease was observed to be 35.69% and 41.64% at the end of 1<sup>st</sup> and 8<sup>th</sup> week of surgery. Our study is supported by the study conducted by Trnavec *et al.*, in this case [12].

## CONCLUSIONS

- The Mean endothelial cell density decrease in Phacoemulsification group is 2.14% after 1<sup>st</sup> week and 4.24% after 8<sup>th</sup> week. While in SICS group it is 1.75% after 1<sup>st</sup> week and 3.8% after 8<sup>th</sup> week.
- Endothelial cell loss was higher in phacoemulsification than SICS, but it was statistically not significant.
- Corneal thickness though it increased initially after surgery but it decreased to its pre-operative value after surgery.
- There is a Strong co-relation between endothelial density and corneal thickness. The Hexagonal cells decreased after surgery, but the degree of cell loss is not related to the incision site.
- The overall loss is not statistically significant.
- All the relevant parameters in Phacoemulsification and SICS surgery are more or less the same in relation to cornea. Hence, in the present Indian scenario, the surgeon can choose any of the two surgeries without any hesitation when it comes to corneal endothelial health postoperatively.

## REFERENCES

1. Tuft, S. J., & Coster, D. J. (1990). The corneal endothelium. *Eye*, 4(3), 389-424.
2. Murphy, C., Alvarado, J., Juster, R., & Maglio, M. (1984). Prenatal and postnatal cellularity of the human corneal endothelium. A quantitative histologic study. *Investigative ophthalmology & visual science*, 25(3), 312-322.
3. Polse, K. A., Brand, R., Mandell, R., Vastine, D., Demartini, D., & Flom, R. (1989). Age differences in corneal hydration control. *Investigative ophthalmology & visual science*, 30(3), 392-399.
4. Siu, A., & Herse, P. (1993). The effect of age on human corneal thickness: statistical implications of power analysis. *Acta ophthalmologica*, 71(1), 51-56.
5. Shepherd, J. (1997). Induced astigmatism in small incision cataract surgery. *Journal of Cataract & Refractive Surgery*, 23, 1389-1393.
6. Meisler, D. M., & Mandelbaum, S. I. D. (1989). Propionibacterium-associated endophthalmitis after extracapsular cataract extraction: review of reported cases. *Ophthalmology*, 96(1), 54-61.
7. Bourne, W. M., & Kaufman, H. E. (1976). Specular microscopy of human corneal endothelium in vivo. *American journal of ophthalmology*, 81(3), 319-323.
8. Bourne, W. M., & O'Fallon, W. M. (1978). Endothelial cell loss during penetrating keratoplasty. *American Journal Ophthalmology*, 85, 760-766.
9. Martin, R., de Juan, V., Rodriguez, G., Fonseca, S., & Martin, S. (2008). Contact lens-induced corneal peripheral swelling differences with extended wear. *Cornea*, 27(9), 976-979.
10. Martin, R., de Juan, V., Rodriguez, G., Fonseca, S., & Martin, S. (2009). Contact lens-induced corneal peripheral swelling: Orbscan repeatability. *Optometry and vision science*, 86(4), 340-349.
11. Gogate, P., Deshpande, M., & Nirmalan, P. K. (2007). Why do phacoemulsification? Manual small-incision cataract surgery is almost as effective, but less expensive. *Ophthalmology*, 114(5), 965-968.
12. Trnavec, B., Cuvala, J., Cernák, A., & Vodrážková, E. (1997). Comparison of corneal endothelial cells after ECCE and phacoemulsification of the lens. *Ceska a slovenska oftalmologie: casopis Ceske oftalmologicke spolecnosti a Slovenske oftalmologicke spolecnosti*, 53(4), 240-243.
13. Ramalingam, M. D. K., Parmar, P., Salman, A., & Jesudasan, N. (2004). Corneal endothelial density after phacoemulsification and manual small incision cataract surgery- a comparison. In Raju NSD, editor. Proceedings of the 62<sup>nd</sup> Annual conference of AIOS Varanasi India, 198.
14. Nowak, R. (2008). SICS--a cost effective alternative to phacoemulsification for developing countries in Nepal. *Klinika oczna*, 110(1-3), 92-97.
15. Ravalico, G., Tognetto, D., Palomba, M. A., Lovisato, A., & Baccara, F. (1997). Corneal endothelial function after extracapsular cataract extraction and phacoemulsification. *Journal of Cataract & Refractive Surgery*, 23(7), 1000-1005.

16. Ohrloff, C., & Zubcov, A. A. (1997). Comparison of phacoemulsification and planned extracapsular extraction. *Ophthalmologica*, 211(1), 8-12.
17. Stumpf, S., & Nosé, W. (2006). Endothelial damage after planned extracapsular cataract extraction and phacoemulsification of hard cataracts. *Arquivos brasileiros de oftalmologia*, 69(4), 491-496.
18. Srinivasan, S., Rajan, M., & Mohan, S. (2004). Corneal thickness and endothelial density before and after phacoemulsification for different cataracts. In Raju NSD, editor. Proceedings of the 62<sup>nd</sup> Annual Conference of AIOS Varanasi India, 207.
19. Binder, P. S., Sternberg, H., Wickham, M. G., & Worthen, D. M. (1976). Corneal Endothelial Damage Associated by Phacoemulsification. *American journal of ophthalmology*, 82(1), 48-54.
20. Polack, F. M., & Sugar, A. (1976). The phacoemulsification procedure. II. Corneal endothelial changes. *Investigative Ophthalmology & Visual Science*, 15(6), 458-469.
21. Lundberg, B., Jonsson, M., & Behndig, A. (2005). Postoperative corneal swelling correlates strongly to corneal endothelial cell loss after phacoemulsification cataract surgery. *American journal of ophthalmology*, 139(6), 1035-1041.
22. Schultz, R. O., Glasser, D. B., Matsuda, M., Yee, R. W., & Edelhauser, H. F. (1986). Response of the corneal endothelium to cataract surgery. *Archives of Ophthalmology*, 104(8), 1164-1169.