

Prosthetic Surgery of Inflammatory Coxitis

Youssef Benyass*, Bouchaib Chafry, Salim Bouabid, Driss Benchebba, Mostapha Boussouga

Department of Orthopedic Trauma, Mohamed V Military Hospital, University Mohamed V - Souissi Rabat Morocco

Original Research Article

*Corresponding author

Youssef Benyass

Article History

Received: 08.06.2018

Accepted: 19.06.2018

Published: 30.06.2018

DOI:

10.36348/sjmps.2018.v04i06.010



Abstract: Ankylosing spondylitis and rheumatoid arthritis are the most common chronic inflammatory rheumatism. Their localization at the level of the hip stresses severely the functional prognosis. We report a retrospective series of 40 total hip prostheses performed in 32 patients with inflammatory coxitis, collected in the Traumatology and Orthopedics Department at the Mohammed V Military Hospital in Rabat between 2008 and 2016. The average age at the time of the intervention was 42 years with a clear male predominance. All patients were followed in consultation with a clinical and paraclinical examination. Coxitis following ankylosing spondylitis is the most frequently encountered in our series (65.6%). The rating of Postel Merle d'Aubigné was used to assess the functional status of the hip before and after surgery. The total hip prosthesis was cementless in 37 cases and cemented in 03 cases. The clinical results for the 32 patients after a mean follow-up of 04 years were very satisfactory in (88%) of the cases. The objective of this study is to evaluate our functional results and to show the interest of total hip arthroplasty in this type of pathology, in order to improve the quality of life of these often young patients.

Keywords: Ankylosing spondylitis, cementless prosthesis, cemented prosthesis, hip, rheumatoid arthritis.

INTRODUCTION

Ankylosing spondylitis (AS) and rheumatoid arthritis (RA) are the most common chronic inflammatory rheumatism. Their localization at the level of the hip strikes heavily the functional prognosis.

The revolution in total hip arthroplasty has played a key role in the functional future of young patients with inflammatory coxitis by improving their quality of life and their degree of independence. It is currently the surgical treatment of choice of rheumatoid coxites and coxites of the AS.

The purpose of our work is to evaluate our functional results and to show the interest of total hip arthroplasty in this type of pathology, in order to improve the quality of life of these often young patients.

MATERIALS AND METHODS

This is a retrospective serie of 40 total hip prosthesis (PTH) performed in 32 patients with inflammatory coxitis. 08 patients underwent bilateral arthroplasty. This serie is collected between January 2008 and December 2016 at the service of Traumatology and Orthopedics at the Mohammed V Military Hospital in Rabat.

The overall average age of our patients was 42 years with extremes ranging from 24 to 68 years old. Our study had a clear male predominance. It consisted of 20 male patients (62.5%) and 12 female patients (37.5%). The coxite most frequently encountered in our series is that encountered during the AS, which

accounted for 65.6% of cases, while rheumatoid coxitis accounted for only 34.4% of cases. The background treatment was based on methotrexate (MTX) in 04 patients with AS and 02 patients with RA, and based on anti TNF alpha in 06 patients with AS and 04 patients with RA. The duration of progression of the disease was variable, 08 years on average, with extremes ranging from 02 years to 20 years.

Clinically, all of our patients had symptoms of pain and functional discomfort to mobility and walking. We have taken the criteria of Postel and Merle d'Aubigné (PMA), in order to assess the clinical state and the function of the hip of our patients before surgery (pain, mobility and walking). 89% of the hips had an overall PMA less than or equal to 9, with an overall average of 7.72. A radiological assessment was performed in our patients to analyze the hip to operate and also the dorso-lumbar spine (Fig 1-2).

The indication of the total arthroplasty of the hip in our patients was put in front of the very painful severe stiffness and the bone ankylosis with limitation of the walk and the activities of the daily life. All of our patients underwent general anesthesia, of which four cases were surgically intubated with a fiberscope because of stiffness of the jaw and ankylosis of the

cervical spine. Patients who have been on MTX treatment have not discontinued it. For TNF alpha, it was stopped 2 to 4 weeks before surgery.

The postero-external route was performed in all our patients. The osteotomy of the femoral neck was performed after dislocation of the femoral head which was not always easy because of soft tissues retraction and periarticular calcifications. Sometimes the extraction of the head was done after osteotomy of the cervix, in case of ankylosis, and we went directly to the preparation of the acetabulum with the help of the motorized cutters of increasing sizes to resect the cartilage remaining until the bone and restore a hemispherical shape to the bony acetabulum. Non-cemented double mobility PTHs were used in 37 hips (Fig. 3), and cemented in 03 hips, in one hip a Kerboul-type support ring with fragmentation of the spongy head that was used for autografting filling of the acetabulum (Fig. 4). No additional bone gestures were used in our series.

All our patients resumed their medical treatments from the first day, except the anti-TNF alpha

which were resumed after 2 weeks. Rehabilitation was started from the first day with information on the actions that easily cause dislocations in order to avoid them.

RESULTS

Our results were evaluated according to the PMA score with a mean follow-up of 04 years (01 year-09 years). Overall, our results are very satisfactory (88%) (Fig.5). The average score before surgery was 7.72, and then went to 15 on average after arthroplasty. The best results are for mobility, which went from 2.55 to 5.33 on average.

The radiological evaluation was based on radiographs of the pelvis from the front, as well as X-rays of the operated hip from the front, taking the entire prosthesis. The careful study of successive radiographs and their confrontation with the early postoperative radiograph constitute the main time of the monitoring of PTH that has been implanted in order to detect early complications such as periprosthetic calcifications and loosening. No intraoperative or postoperative complications were noted in our series.

Table-1: Functional Results by Series

authors	Number of arthroplasties	RESULTS		
		Excellent and Good %	Medium %	Bad %
Sochart [12]	43 PTH	81	19	0
Williams [13]	86 PTH	73	13	14
Wegrzyn [14]	63 PTH	81	19	0
Notre série	40 PTH	88	12	0

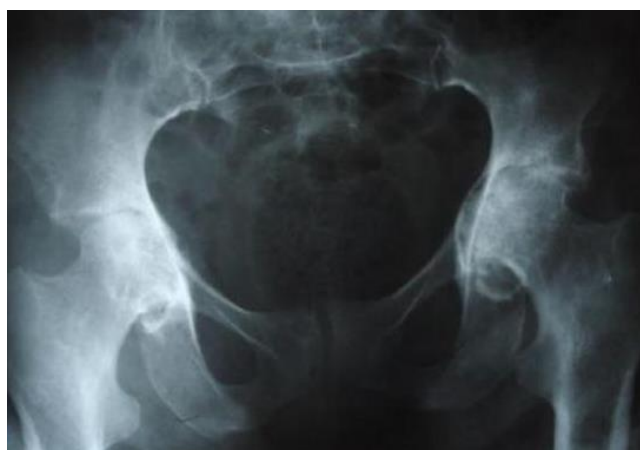


Fig-1: X-ray of the pelvis showing bilateral coxite on RA

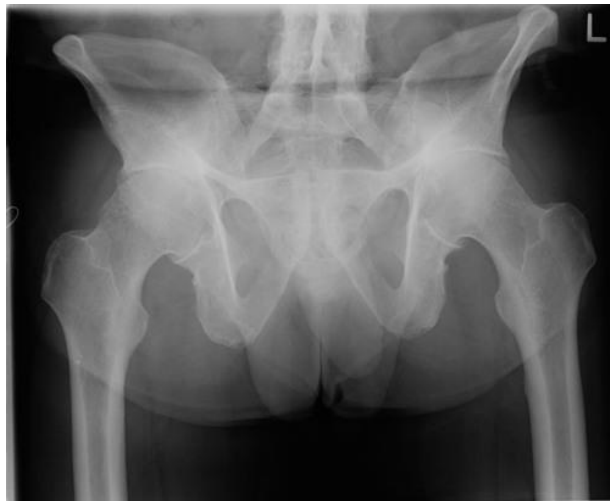

Fig-2: X-ray of pelvis showing bilateral coxite on AS

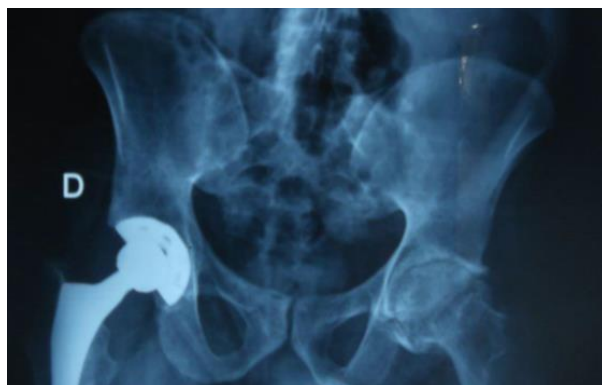

Fig-3: Pelvis radiograph showing a straight uncemented PTH on AS

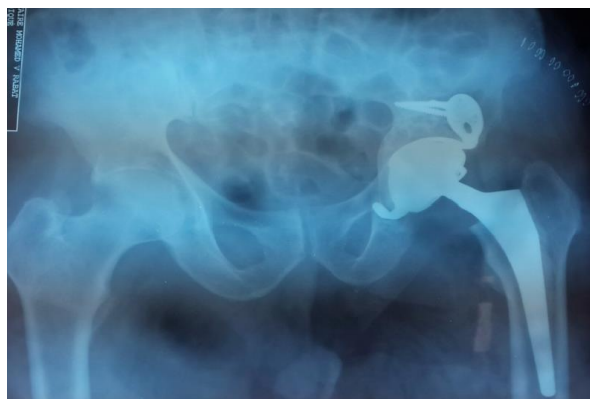


Fig-4: Pelvis X-ray showing a cemented left PTH with Kerboull ring

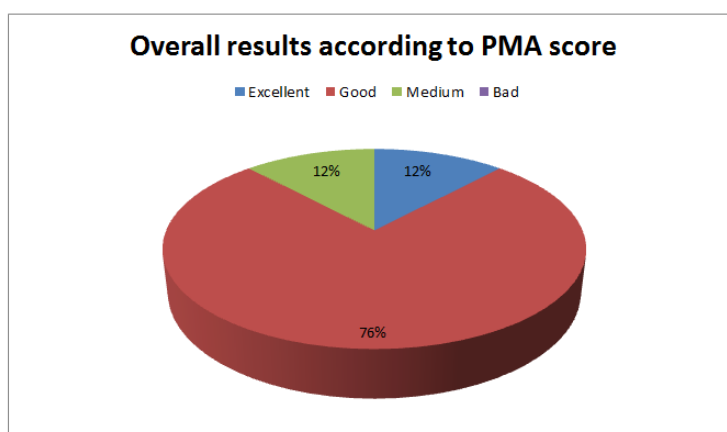


Fig-5: Percentage of Clinical Outcomes at Last Consultation

DISCUSSION

Inflammatory coxitis occurs in often young patients. The AS is most often responsible. Diagnosis as well as early management by medical treatment and rehabilitation delays the use of surgery [1], but once the ankylosis is installed, hip replacement surgery finds its place as quickly as possible to avoid to reach the stage of disabling large deformities [1], even if the age of the patients is too young because it could have an influence on the aseptic loosening. In our series, the average age of operated patients was 42 years old. This is higher than that found in the literature where it varies between 31 and 37 years [2, 3], because in the Moroccan context, patients do not easily accept surgical treatment and they are discouraged by the high cost of the surgery in case of non-management by an organism.

Most patients with inflammatory coxitis and candidates for total hip arthroplasty are already under different therapies, which favor the occurrence of an infectious complication or delay of healing in the event of surgery, hence the interest of respecting duration of stop before the surgery and a time of recovery after the surgery. For anti-TNF α drugs, a stopping time of at least 2 weeks for Etanercept and at least 4 weeks for Infliximab and Adalimumab is recommended, if there are no circumstances of risk [4]. They should not be restarted until at least two weeks after surgery and only after complete healing and absence of sepsis [5]. In our series we respected the time to stop before surgery (2 to 4 weeks) and the recovery time after surgery (at least 2 weeks) in all our patients on anti TNF α . For methotrexate (MTX), EULAR's new recommendations for use of MTX advocate its continued use during orthopedic surgery. Despite the risks of infection and the risk of delayed postoperative healing [6]. In our series, patients did not interrupt MTX. No cases of infectious complication or delayed healing were noted.

The choice of anesthesia is done individually for each patient, collaboration between the surgeon and the anesthesiologist is necessary for a good planning of the anesthesia technique, and to be ready to overcome

the difficulties due to the stiffness of the jaw and to spinal ankylosis. In this regard, we had four cases of visual intubation under fiberscope, knowing that general anesthesia was the rule in our series.

The approach of the coxofemoral remains a personal choice of the operator. It allows a good exposure which conditions both the quality of the surgical procedure, the positioning of the prosthetic parts, and therefore the functional result. The postero-external route is currently the most used [7].

The choice of the prosthesis in inflammatory coxitis remains until today an unclear point. This condition influences the operative technique and the final functional result when implanting prosthesis. Cemented PTHs have the most hindsight and the best results [8]. Moreover, few publications have reported the use of uncemented PTH during inflammatory coxitis. In the Tang series, the longevity of cemented PTH was 100% at 5 years and 96.8% at 10 years, while that of uncemented prostheses was around 95.5% at 5 and 10 years and dropped sharply to 63, 6% at 11 years [9].

In our series the PTHs put in place had a metal / polyethylene friction couple and double mobility in all cases. They were cementless in 37 hips and cemented in 03 hips, including one with a Kerboull-type support ring.

In front of ankylosis following AS, two important points must be emphasized:

- Prevent prosthetic malpositions, ensuring the orientation of the pelvis during the installation in operating table.
- Prevent the risk of peri-prosthetic ossification by establishing a postoperative based Indomethacin treatment dose of 75 mg daily for 03 weeks [10].

In our series all the patients received the treatment based on indomethacin postoperatively.

In patients with RA, disturbances of bone metabolism are responsible for thinning proximal cortical, and trochanteric and acetabular osteoporosis. This promotes acetabular protrusion that has become specific to rheumatoid coxitis [11]. In addition, the deformation in quasi-articular ankylosis makes difficult the coxo femoral dislocation during arthroplasty. It requires the realization of cervicotomy with the head in place and its extraction to avoid fracture intraoperatively. The reconstruction of the acetabulum is essential in case of acetabular protrusion, it allows obtaining a satisfactory clinical outcome, and also extending the life of prosthetic. In our study the acetabulum was reconstituted in a single patient by the use of fragments of the head cancellous chips to fill the acetabular rear bottom and its fixation with a Kerboul ring. The retraction of the soft tissues is also one of the elements that influence the function of the PTH in these patients; it can touch the anterior soft parts and be responsible for a flossum. This requires the disinsertion of the anterior muscles. In our series, all our patients benefited from a good capsular release and a refocusing of the prosthetic head.

Our functional results were appreciated following the rating of Postel Merle d'Aubigné. The average score before the intervention was 7.72, and had increased to 15 on average. The best results for mobility went from 2.77 to 5.33. The pain went on average from 2.5 to 5 (5 hips have complete indolence). On average, walking increased from 2.44 to 4.61. Overall, the results were excellent too good in 88% of cases, average in 12% of cases. Our results are generally in line with most other series (Table 1). They reflect a significant improvement in the quality of life of patients, mainly related to the disappearance of pain, mobility and the restoration of walking.

CONCLUSION

Total hip arthroplasty has improved the quality of life of patients with inflammatory coxitis. These patients are young and disabled because of their illness, for which the recovery of autonomy allows to find a socioprofessional development close to normal.

But total hip prostheses pose long-term infectious and mechanical problems (wear, loosening ...) limiting their longevity. For this surgery to be effective, various conditions are necessary, including multidisciplinary care with good collaboration between surgeon, rheumatologist and physiotherapist.

At the end, detailed studies are necessary to know the distant future of these implanted prostheses in young and active patients, because they will be subjected for many years to activities which can generate the wear of the materials and the loosening of the prosthetic parts.

ACKNOWLEDGEMENTS

This manuscript was prepared during the corresponding author's training and was supported by the authors.

REFERENCES

1. Hamdi, W., Alaya, Z., Ghannouchi, M. M., Haouel, M., & Kchir, M. M. (2012). Facteurs associés à un mauvais pronostic fonctionnel et à un remplacement prothétique de la coxite au cours de la spondylarthrite ankylosante. *Revue du rhumatisme*, 79(1), 91-92.
2. Caton, J., Courpied, J. P., Ferreira, A., & Hamadouche, M. (2004). La prothèse totale de hanche. In *4th symposium Charnley International Lyon* (pp. 130-135).
3. Bangjian, H., Peijian, T., & Ju, L. (2012). Bilateral synchronous total hip arthroplasty for ankylosed hips. *International orthopaedics*, 36(4), 697-701.
4. Ledingham, J., & Deighton, C. O. (2005). Update on the British Society for Rheumatology guidelines for prescribing TNF α blockers in adults with rheumatoid arthritis (update of previous guidelines of April 2001). *Rheumatology*, 44(2), 157-163.
5. Ding, T., Ledingham, J., Luqmani, R., Westlake, S., Hyrich, K., Lunt, M., ... & Ostor, A. (2010). BSR and BHPR rheumatoid arthritis guidelines on safety of anti-TNF therapies. *Rheumatology*, 49(11), 2217-2219.
6. Veetil, B. M. A., & Bongartz, T. (2012). Perioperative care for patients with rheumatic diseases. *Nature Reviews Rheumatology*, 8(1), 32.
7. Moore, A. T. (1957). The self-locking metal hip prosthesis. *JBJS*, 39(4), 811-827.
8. Lahrach, K., & Boutayeb, F. (2014). Le traitement prothétique des coxites inflammatoires-à propos d'une série continue de 85 cas. *Revue de Chirurgie Orthopédique et Traumatologique*, 100(7), S222-S223.
9. Joshi, A. B., Markovic, L., Hardinge, K., & Murphy, J. C. (2002). Total hip arthroplasty in ankylosing spondylitis: an analysis of 181 hips. *The Journal of arthroplasty*, 17(4), 427-433.
10. Trueta, J., & Harrison, M. H. M. (1953). The normal vascular anatomy of the femoral head in adult man. *The Journal of bone and joint surgery. British volume*, 35(3), 442-461.
11. Combe, B. (2009). Polyarthrite rhumatoïde: Clinique et Diagnostic. *Etudes*.
12. Sochart, D. H., & Porter, M. L. (1997). Long-term results of total hip replacement in young patients who had ankylosing spondylitis. Eighteen to thirty-year results with survivorship analysis. *JBJS*, 79(8), 1181-9.
13. Gao, Y., Wang, B., Xie, Z. K., Shen, P. F., Zheng, C., & Qu, Y. X. (2015). Total hip arthroplasty for ankylosing spondylitis: the spine-pelvis sagittal balance and quality of life. *Journal of Clinical Rehabilitative Tissue Engineering Research*, (4), 516-521.

14. Lesur, E., & Laude, F. (2004). Arthroplastie totale de hanche par voie anterieure et son evolution mini-invasive. *EMC-Rhumatologie-Orthopedie*, 1(5), 445-453.