

**Unusual Cause of Nasal Obstruction: Tornwaldt Cyst**

Hemmaoui B\*, Sahli M, Errami N, Moumni M, Balouki, M, Jahidi A, Zalagh M, Benariba F

Department of Otorhinolaryngology, Mohammed V Military Teaching Hospital, Faculty of medicine and pharmacie, Mohammed V-Souissi University, Rabat, Morocco

**Case Report****\*Corresponding author**

Hemmaoui B

**Article History**

Received: 11.05.2018

Accepted: 19.05.2018

Published: 30.05.2018

**DOI:**

10.36348/sjimps.2018.v04i05.022



**Abstract:** Tornwaldt's cyst is an uncommon midline nasopharyngeal cyst that arises from the pharyngeal bursa on the posterior nasopharynx. They represent as a communication between notochord remnants and the pharyngeal endoderm. Occlusion of this communication results in the formation of Tornwaldt's cyst. Development of these cysts has been linked to scarring from prior adenoidectomy and nasopharyngeal inflammation. It is usually small and accidentally diagnosed on rhinoscopy, computerized tomography (CT) or magnetic resonance imaging (MRI). Clinical symptoms of nasopharyngeal cysts may include fullness in the ear, tinnitus, nasal obstruction, dysphagia, dysarthria, dysphonia, odynophagia, halitosis, cephalgia, or stiffness of cervical muscles. We report a case of a 24-year-old male with as an isolated nasal obstruction and discuss the clinical, radiological features, and the differential diagnosis of these cysts.

**Keywords:** Tornwaldt cyst, nasal obstruction, MRI, Marsupialization.

**INTRODUCTION**

Thornwaldt's cyst (TC) is a rare benign lesion at the posterosuperior wall of the nasopharynx above the adenoids [1, 2]. It is a congenital remnant of notochord and pharyngeal ectoderm in the posterior nasopharynx [3, 4]. It is usually small and accidentally diagnosed on rhinoscopy, computerized tomography (CT) or magnetic resonance imaging (MRI) [5]. Trauma, inflammation or infection can lead to obstruction of the draining orifice of the nasopharyngeal bursa producing a TC.

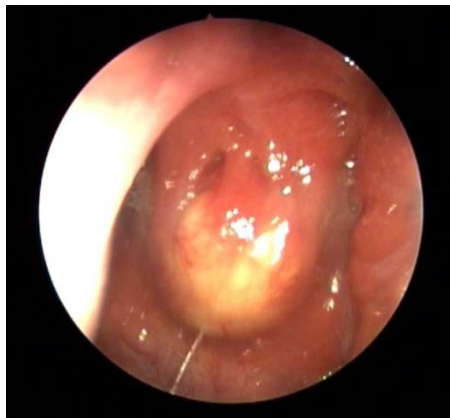TC have reported prevalence of 0.2–5% and although most are asymptomatic, their location and continuity with the respiratory epithelium renders them vulnerable to infection. It is present in about 4% of autopsied patient with age incidence between 15 and 30 years [5].

**CASE REPORT**

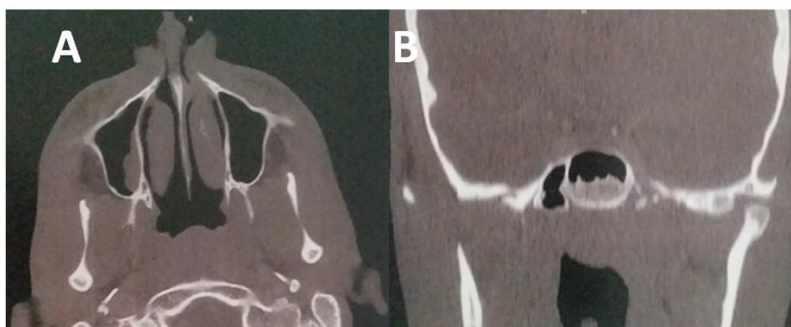
A 24-year-old man came to our hospital complaining of progressive nasal obstruction that had lasted for 1 year. He had no history of headache, postnasal drip, nasal operation or trauma. Endoscopic endonasal examination showed a mass with a yellow color in the central party and a diameter of almost 2 cm located in the midline of the nasopharynx and slightly lateralized at the right (Figure-1). Computed tomography of the nasopharyngeal space showed a thickening of the posterior wall of the cavum whose anterior edge bomb at the level of the light of the

nasopharynx, and magnetic resonance imaging (MRI) showed a lesional formation, interesting the roof of the cavum, of lobules contours, measuring 12 mm of diameter, being in hypersignal in T1 and hyposignal in T2 evoking a tornwald cyst (Figure-2 A, B, C and D). No intracranial communication and bony destruction were found. from the endoscopic and radiological data the diagnosis of a tornwaldt cyst was made.

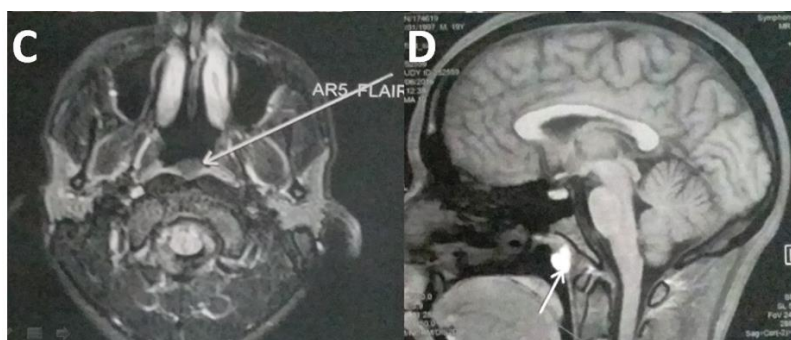
Endoscopic surgery was performed under general anesthesia. we incised the cyst and removed the contenu of the cyst piece by piece. Some yellowish to brownish discharge was noted within the mass. The patient was discharged 5 days later. Histopathology confirmed the diagnosis of teh tornwaldt cyst. At the 3 years follow-up, the patient had made an uneventful recovery, and nasopharyngoscopic examination demonstrated good wound healing and no sign of recurrence.



**Fig-1: Endoscopic appearance of the Tornwaldt cyst**



**Fig-2A & B: CT scan showed a thickening of the posterior wall of the cavum whose anterior edge bomb at the level of the light of the nasopharynx**



**Fig-2C & D: IRM showed a lesional formation, interesting the roof of the cavum, of lobules contours, measuring 12 mm of diameter, being in hypersignal in T1 and hyposignal in T2 evoking a tornwaldt cyst**

## DISCUSSION

Mayer was the first to describe a cyst-like mass in the posterior wall of the nasopharynx in 1840. In 1885, Thornwaldt presented 26 cases of nasopharyngeal cysts and described both the clinical symptoms and his methods of treatment in detail. In 1912, Huber, in a description of the embryologic formation of Thornwaldt's bursa, reported that a potential space could develop in the nasopharynx at the point where the notochord retained its union with the pharyngeal endoderm [2, 3].

It is present in about 4% of autopsied patient with age incidence between 15 and 30 years. There is no sex predilection [6].

It may result either spontaneously or secondary to mechanical obstruction by trauma or inflammation of the pharyngeal bursa [1, 4]. The diagnosis of Thornwaldt's disease begins with a history of symptoms, followed by confirmation by nasopharyngoscopy and image study [1].

The most common symptoms include fullness in the ear, tinnitus, nasal obstruction, dysphagia, dysarthria, dysphonia, odynophagia, halitosis, cephalgia, or stiffness of cervical muscles [6]. Our patient did not have any of these symptoms except for nasal obstruction.

Nasopharyngoscopy usually shows a smooth, submucosal, midline cystic mass superior to the adenoid

pad. The size of the symptomatic lesion is usually more than 20–25 mm in diameter [2, 3].

TC are best observed by MRI, they are round and well circumscribed with sharp contours and are located in the posterior nasopharynx, usually in the midline between the longus capitus muscles [4]. The lesion usually has a characteristic high signal intensity on T2-weighted and intermediate to high signal intensity on T1-weighted MRI imaging. The variation in signal intensity on T1-weighted images may be related to differences in protein content or hemorrhage in the cyst [3]. On CT scan a low density, well capsulated mass in the roof of nasopharynx is suggestive of Tornwaldt cyst [5]. MRI in our patient showed a cyst measuring 12 mm.

Differential diagnosis of this cyst is branchial cleft cyst, Rathke's pouch cyst, adenoid retention cyst, meningoceles or meningoencephaloceles, sphenoid sinus mucoceles, and nasopharyngeal carcinoma [3, 4, 6].

Treatment of Tornwaldt's cysts is recommended only for those that are symptomatic. Asymptomatic cysts may just be incidental findings on radiologic studies and require no intervention. Surgical treatment in symptomatic patient is advisable. Excision or Marsupialization of the cyst is the surgery of choice. Procedure can be done with help of nasal endoscope and microdebrider. Aspiration alone leads to recurrence [5, 6].

## CONCLUSION

Tornwaldts cyst is a rare benign lesion that may present in many ways. In this case, our patient presented, uniquely, with isolated nasal obstruction. . Some controversy exists regarding the true etiology of Tornwaldts cysts. Classically, it is described as a notochord remnant. Others indicate this may be iatrogenic occlusion of normal structures after adenoidectomy or chronic inflammation. It should be noted that the lesion was missed on CT imaging and easily demonstrated on MRI. Treatment of Tornwaldt cysts is only recommended if they are symptomatic

## REFERENCES

1. El-Anwar MW, Amer HS, Elnashar I, Askar SM, Ahmed AF. 5 years follow up after transnasal endoscopic surgery of Thornwaldt's cyst with powered instrumentation. *Auris Nasus Larynx*. 2015 Feb 1;42(1):29-33.
2. Kwok P, Hawke M, Jahn AF, Mehta MA. Tornwaldt's cyst: clinical and radiological aspects. *The Journal of otolaryngology*. 1987 Mar;16(2):104-7.
3. Lin JH, Tai CF, Lee KW, Ho KY, Kuo WR, Wang LF. Huge Thornwaldt's cyst: a case report. *The*

*Kaohsiung journal of medical sciences*. 2006 Oct 1;22(10):524-8.

4. Wilcox, R. A., & Pathi, R. (2007). Tornwaldt's cysts are sometimes a bit of a headache. *Internal medicine journal*, 37(1), 67-68.
5. Baisakhiya N, Deshmukh P, Pawar V. Tornwaldt cyst: a cause of neck pain and stiffness. *Indian Journal of Otolaryngology and Head & Neck Surgery*. 2011 Jul 1;63(1):147.
6. Voth SE, Hanna JP, Zwillenberg D. Tornwaldt's cyst: Clival erosion with reconstitution after treatment. *International Journal of Pediatric Otorhinolaryngology Extra*. 2011 Jan 1;6(1):36-8.