

Primary Tuberculosis of the Temporalis Muscle: A Case Report

Adil Arrob*, Abdeljalil abouchadi

Department of plastic and maxilla-facial surgery, avicenne military hospital, cadia ayyad university, Marrakech, Morocco

Case Report

*Corresponding author

Adil Arrob

Article History

Received: 07.05.2018

Accepted: 18.05.2018

Published: 30.05.2018

DOI:

10.36348/sjimps.2018.v04i05.014



Abstract: Tuberculosis of the temporalis muscle is a rare clinical entity. Diagnosis is difficult because there are no specific clinical, radiological or biological signs of the disease. Only bacteriological and histopathological findings can confirm the diagnosis. Treatment is based on anti-tuberculous drugs and allows usually a favourable evolution. The aim of this paper is to report a case of primary tuberculosis of the temporalis muscle in a 67-year-old female, and to stress the corresponding diagnostic pitfalls.

Keywords: Tuberculosis, Temporal Muscle.

INTRODUCTION

Primary tuberculous pyomyositis (PM) is a rare entity constituting less than 1% of skeletal tuberculosis [1]. This can mimic inflammatory myositis or rarely cancer and can create diagnostic confusion for surgeon. It should always be considered as a rare but possible aetiology of myositis [2]. Tubercular myositis in an immunocompetent patient without underlying bony involvement is an unusual presentation and its pathogenesis is still unclear [3, 4]. We present a case of primary tubercular pyomyositis of the temporalis muscle.

CASE PRESENTATION

A 67-year-old woman, consulted in our formation for a right temporal mass that has been evolving for about 6 months (Fig. 1). She denied a history of diabetes mellitus, intravenous drug addiction or other major systemic diseases. She reported no recent trauma, insect bites and skin infections.

On physical examination, marked swelling in the right temporal area, but no erythema was detected over that area. There was no lymphadenopathy. The remainder of the physical examination was unremarkable. Laboratory results revealed an elevated white blood cell count at 14.k.

A maxillofacial tomodensitometry showed a straight, heterogeneous intramuscular collection (Fig-2). Magnetic resonance imaging (MRI) showed a partitioned fluid mass embedded in the temporal muscle (Fig-3). In front of the pseudo-tumoral aspect, we carried out a large excision of the atrophic temporal muscle by hemi-coronal way under general anesthesia, with bacteriological and anatomo-pathological studies (Fig-4).

Intravenous amoxicillin and clavulanate potassium were prescribed for treatment of the infection. Routine bacterial (aerobic and anaerobic) and fungal cultures of the pus yielded no growth. However, the microscopic examination showed numerous acid-fast bacilli, and an assay based on polymerase chain reaction showed a positive result for *Mycobacterium tuberculosis*.

Chest X-ray revealed no nodules or other possible abnormalities caused by *Mycobacterium tuberculosis*. The treatment was changed to antituberculosis agents, including isoniazid, rifampicin, pyrazinamide and ethambutol.

After 9 months of treatment the patient was well with no discomfort and so the medication was discontinued.

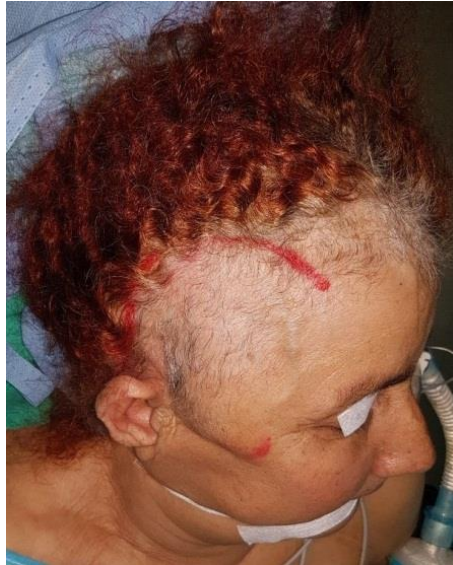

Fig-1: Right temporal swelling

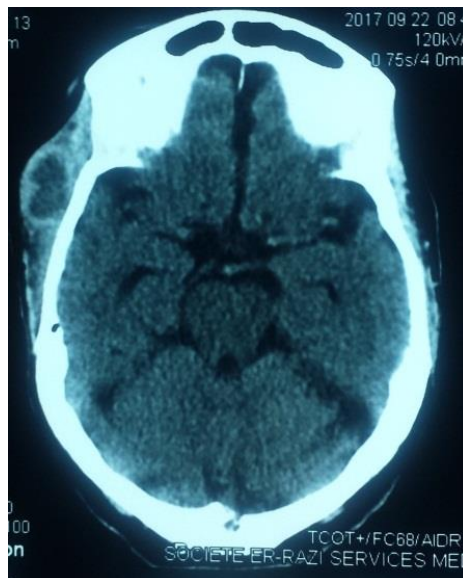

Fig-2: computed tomography in axial section: Intra temporal muscle abscess

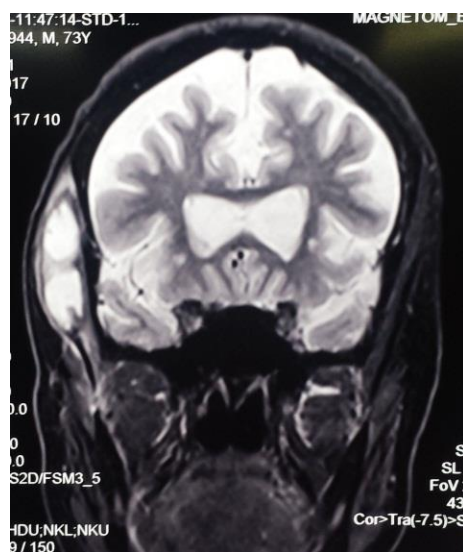


Fig-3: Cranio-facial MRI shows a temporal collection with thick wall

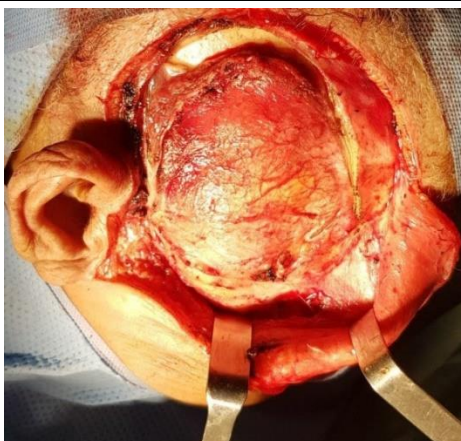


Fig-4: Intraoperative photo, hemi-coronal approach.

DISCUSSION

Extra pulmonary infection accounts for 40% of all tuberculosis cases [2]. Common sites of extra pulmonary tuberculosis are lymph nodes and abdomen. Musculoskeletal tuberculosis occurs only in 3% of cases. Tuberculosis of the striated muscle is rare even in countries where tuberculosis is a relatively common disease [4].

Normally, skeletal muscle is highly resistant to bacterial infection and abscess formation [5]. Most cases from temperate regions involve patients with an underlying immuno-compromised condition. PM predominantly involves a single large muscle such as the muscles of the thigh, back, buttock or arm. To our knowledge, this is case report of tuberculous PM involving the temporal muscle.

Clinical manifestations are usually nonspecific. This might lead to diagnostic dilemma. Tubercular pyomyositis is commonly misdiagnosed as a soft tissue sarcoma, parasitic infection like cysticercosis or hydatid cyst, and inflammatory myositis or hematoma with secondary infection because of its close resemblance clinically [6].

There is usually a delay in diagnosis because of its atypical presentation, lack of knowledge of the disease, absence of early specific signs, and a large number of differentials. High index of clinical suspicion is the key in diagnosis especially in endemic areas. Blood investigations usually are normal [7].

DNA-PCR is a highly sensitive investigation especially to differentiate tubercular from non tuberculous mycobacteria which cause soft tissue infection. With its multiplanar capability and contrast for soft tissue, MRI is the investigation of choice. Most cases of M. tuberculosis myositis are initially diagnosed as bacterial pyomyositis. Although it is difficult to differentiate between M. tuberculosis and Staphylococcal pyomyositis in the early stage of

disease, MRI findings can help to distinguish between them [8].

MRI is superior to CT in the detection and characterization of the swelling in order to differentiate it from malignancy [9].

No specific guidelines exist for the management of tuberculous pyomyositis [10], though the cornerstone happens to be early diagnosis and anti-tubercular chemotherapy. "Effective drainage" of the abscess must be ensured. This may be done by aspiration [9] or by surgical exploration.

CONCLUSION

Although isolated muscle tuberculosis is a rare entity, it must always be taken into consideration as a differential diagnosis for isolated muscle swelling, especially in a country with a high tuberculosis endemic. The diagnosis is mainly bacteriological and / or pathological. Treatment uses anti-bacillary chemotherapy alone or in combination with surgery. The prognosis is often favorable when the care is early.

REFERENCES

1. Abdelwahab, I. F., Bianchi, S., Martinoli, C., Klein, M., & Hermann, G. (2006). Atypical extraspinal musculoskeletal tuberculosis in immunocompetent patients: part II, tuberculous myositis, tuberculous bursitis, and tuberculous tenosynovites. *Canadian Association of Radiologists Journal*, 57(5), 278.
2. Wang, W., Lin, F. C., Tsao, T., & Lu, J. (2007). Tuberculous myositis: an unusual presentation of extrapulmonary tuberculosis. *Journal of Microbiology Immunology and Infection*, 40(1), 79.
3. Chewolkar, V., Bichile, L., & Patel, H. (2009). Pyomyositis with multifocal osteomyelitis—an uncommon presentation of skeletal tuberculosis. *J Assoc Physicians India*, 57, 706.
4. Bonomo, R. A., Graham, R., Makley, J. T., & Petersilge, C. A. (1995). Tuberculous pyomyositis: an unusual presentation of disseminated

- Mycobacterium tuberculosis infection. *Clinical infectious diseases*, 20(6), 1576-1577.
5. Brown, J. D., & Wheeler, B. (1984). Pyomyositis: report of 18 cases in Hawaii. *Archives of internal medicine*, 144(9), 1749-1751.
 6. Modi, M. A., Mate, A. D., Nasta, A. M., & Gvalani, A. K. (2013). Primary tuberculous pyomyositis of quadriceps femoris in an immunocompetent individual. *Case reports in infectious diseases*, 2013.
 7. Sen, R. K., Tripathy, S. K., Dhatt, S., Saini, R., Aggarwal, S., & Agarwal, A. (2010). Primary tuberculous pyomyositis of forearm muscles.
 8. Kim, J. Y., Park, Y. H., Choi, K. H., Park, S. H., & Lee, H. Y. (1999). MRI of tuberculous pyomyositis. *Journal of computer assisted tomography*, 23(3), 454-457.
 9. Batra, S., Ab, M. N., Barwick, C., & Kanvinde, R. (2007). Tuberculous pyomyositis of the thigh masquerading as malignancy with concomitant tuberculous flexor tenosynovitis and dactylitis of the hand. *Singapore medical journal*, 48(11), 1042-1046.
 10. Jang, E. Y., Lee, S. O., Choi, S. H., Sung, H., Kim, M. N., Kim, B. J., ... & Woo, J. H. (2007). Case of pyomyositis due to Mycobacterium haemophilum in a renal transplant recipient. *Journal of clinical microbiology*, 45(11), 3847-3849.