

## To Study Effect of Transversus Abdominis Plane Block Using 0.25% Levobupivacaine on Post-Operative Analgesia in Patients Undergoing Open Prostatectomy

Anju Gautam<sup>1</sup>, Nidhi Sharma<sup>2\*</sup>, Rajan Godwin<sup>3</sup>

<sup>1</sup>Assistant Professor, Department of Anaesthesiology, N.S.C.B. Medical College, Jabalpur, MP, India

<sup>2</sup>Consultant Anaesthesiologist, Department of Anaesthesiology, N.S.C.B. Medical College, Jabalpur, MP, India

<sup>3</sup>Associate Professor, Department of Anaesthesiology, N.S.C.B. Medical College, Jabalpur, MP, India

### Original Research Article

#### \*Corresponding author

Nidhi Sharma

#### Article History

Received: 27.10.2018

Accepted: 03.11.2018

Published: 07.11.2018

#### DOI:

10.36348/sjimps.2018.v04i11.007



**Abstract:** Patients undergoing surgery are most feared of postoperative pain. All the techniques for multimodal analgesia has some or the other side effects. Transversus abdominis plane (TAP) block is newer, effective and comparatively simpler to perform and provides better and denser pain relief than pharmacological agents. It could be used in abdominal and inguinal surgeries. This randomized control study was conducted on 60 male patients of ASA grade 1 and 2 undergoing open prostatectomy after taking ethics committee approval. In group L (n = 30), 0.25% Levobupivacaine hydrochloride (20ml) and in group S (n=30), 20 ml of normal saline was given through TAP block after completion of surgery. Time of first rescue analgesia and total dose of analgesic consumption for 24 hour postoperatively along with pain visual analogue scale (VAS) were measured and compared along with other vitals like heart rate, SBP, DBP and MAP. Postoperatively, TAP block using levobupivacaine just after completion of surgery results in better analgesia in post-operative period in patients undergoing open prostatectomy. Time of rescue analgesia in group L was 209.3±27.25min and in group S was 70.6±9.8 min. Also total analgesic dose consumption and VAS score in postoperative period was significantly low in levobupivacaine group when compared with the saline or control group (p<0.05). TAP block using levobupivacaine 0.25% in open prostatectomy patients provide better analgesia in postoperative period and reduces amount of total analgesic consumption and thus the side effects associated with the later.

**Keywords:** Analgesia, Levobupivacaine, Normal saline, open prostatectomy, TAP block.

### INTRODUCTION

Skin incision is the most painful step of any surgical procedure. The aim of postoperative pain treatment is to minimize patient discomfort, facilitate early mobilization and functional recovery and prevent acute pain developing into chronic pain [1].

Post-operative pain if remain untreated, may cause severe complications like hypertension, tachycardia, myocardial ischemia, angina, inability to cough, reduced mobility, increased morbidity and post-surgical stress to the patient concerned[2].

Pharmacological agents like opioids, ketamine, nonsteroidal anti-inflammatory drugs, alpha-2 agonists, and paracetamol or regional procedures like epidural catheterization are usual methods of post-operative pain relief [3]. Ilioinguinal nerve block and hypogastric nerve block are kind of direct nerve blocks for the purpose of pain relief in lower abdominal surgeries.

Transversus abdominis plane (TAP) block is newer, effective and comparatively simpler to perform. It along with ilioinguinal nerve and hypogastric block, also blocks the lower intercostal (T7 – T11) thus provides better and denser pain relief [4]. In TAP block, nerves of anterior abdominal wall are desensitized by injecting long acting local anesthetic solution between internal oblique and transverses abdominis muscle via lumbar triangle of Petit which is formed posteriorly by the latissimus dorsi muscle and anteriorly by the external oblique and iliac crest forms its base. Thus it is very useful for patients inguinal hernia repair, abdominoplasty, caesarean section, prostatectomy and colorectal surgery [5, 6].

Levobupivacaine, an S (-) isomer of racemic bupivacaine is a newer long acting local anaesthetic with a lower toxicity (especially cardiac) and similar potency as bupivacaine [7].

This study is aimed to assess the effects of transversus abdominis plane block using

Levobupivacaine for post-operative analgesia patients undergoing open prosectomy under subarachnoid block.

## MATERIALS AND METHODS

The present study was carried out after obtaining approval from the ethical committee. The present study was done on 60 male patients of ASA grade I & II of age group 35-70 years scheduled for elective inguinal hernia surgeries.

### Exclusion Criteria

BMI <18 or >35kg/m<sup>2</sup>, preoperative opioid or nonsteroidal anti-inflammatory drug treatment for chronic pain, chronic hepatic, renal failure, cardiac and neurological disease, known allergy to local

anaesthetic, alcohol /drug abuse and infection at the injection site.

### Consent

Details of procedure were explained to all the patients during preanaesthetic assessment and an informed and written consent was obtained.

### Patients' grouping

60 male patients of ASA grade I & II scheduled for open prosectomy under spinal anaesthesia were divided into 2 groups (n=30 each) randomly using envelope technique depending upon the drug given through TAP block after completion of surgery as below:

Group L (n = 30)	0.25% Levobupivacaine hydrochloride (20ml)
Group S (n = 30)	20 ml of normal saline

### Preparation of the patient

*Preoperative assessment* a thorough preoperative evaluation was done including history, general physical examination, systemic examination, airway and spine. Counseling was done and informed consent was taken.

### Pre-medication

Pre-operative fasting of 8 hours, intradermal sensitivity test was performed and inj. Glycopyrolate 0.01 mg/kg IV 30 minutes before the induction of anaesthesia.

Upon arrival of the patient in the operation room, intravenous access with 18G cannula established and 500 mL of crystalloid infusion started. All the baseline vital parameters like heart rate, SBP, DBP, MAP, ECG and SPO2 were monitored.

Under all aseptic precautions, cleaning, painting, draping is done in sitting position and Sub-arachnoid block is induced with 25 gauge spinal needles in L<sub>3</sub> – L<sub>4</sub> intervertebral space. After confirmation of free flow of cerebrospinal fluid, 3.0ml of 0.5% Bupivacaine (heavy) is injected intrathecally, patient was made supine and effect was checked up to desired level of T<sub>10</sub> for prostate surgery. All the vital parameters like heart rate, SBP, DBP, MAP, ECG and SPO2 were monitored throughout the procedure.

After accomplishment of the procedure, under all aseptic precautions cleaning and painting was done. Nerve stimulator with insulated needle at 1miliampere current is used. Firstly, needle is advanced through triangle of Petit at right angles to the skin in coronal plane until resistance was encountered. Further advancement of the needle results in first pop-up feel indicating lying of needle plane between external and

internal oblique fascial layers. Further traversing resulted in a second "pop" indicative of entry into transversus abdominis plane. Twitching of external oblique muscle was appreciated externally as confirmation of the space and current was reduced down to 0.3-0.4 miliampere and then 0.25% levobupivacaine or saline was injected after aspiration according to the study group.

Readings of vital parameters i.e. heart rate, SBP, DBP, MAP and ECG were recorded before induction of sub-arachnoid block as baseline and then at induction 0, 5, 10, 30, 60 min. and at 120 min intervals intraoperatively and then post-operatively recorded at 0 min, 1, 4, 16, 20 and 24 hours after surgery. Time of first rescue analgesia and total dose of analgesic consumption for 24 hour postoperatively along with pain visual analogue scale (VAS) were also measured and compared. Adverse effects such as hypotension, bradycardia, nausea, vomiting, headache, dizziness, constipation and cardiovascular instability were also recorded.

The observations were recorded and subjected to statistical analysis using student's "t" test and for qualitative variables chi square test was used. The observations recorded in both the groups were tabulated and statistical analysis was carried out by using SPSS version 17 statistical software. For intergroup comparison, p > 0.05 and p < 0.05 were considered as insignificant & significant respectively. p < 0.01 was considered as highly significant.

## RESULTS

Data obtained from the patients involved in study were analyzed. The mean age, weight, sex, type of surgery and duration of anaesthesia were comparable in the two study groups as shown in table 1.

**Table-1: Showing demographic variables in study groups**

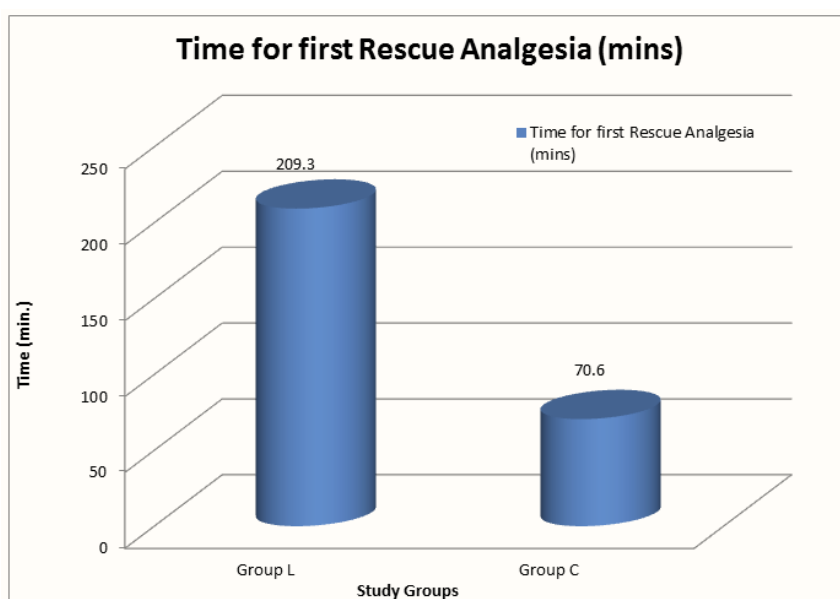
Demographic data	Group L	Group C
Age	57.06±10.63	55.20±9.57
Weight	58.36±12.15	56.53±9.25
Sex (male)	100%	100%
Duration of surgery	54.23 ± 6.47	54.4 ± 7.23

Preoperative heart rate, systolic, diastolic and mean blood pressure level were comparable in all the three groups. Intraoperatively, vitals like heart rate,

SBP, DBP and MAP were measured at various time intervals and difference is found to be statistically insignificant ( $p > 0.05$ ).

**Table-2: Mean (±SD) time for first rescue analgesia in two groups**

Variable	Group L (n=30)	Group C (n=30)
	Mean± SD	Mean± SD
Time for first Rescue Analgesia (mins)	209.3±27.25	70.6±9.8



**Table-3: Total analgesic (tramadol) consumption in 24 hr (mg) and vas score mean (±sd) in two groups**

Variable	Group L (n=30)	Group C (n=30)
	Mean± SD	Mean± SD
Total analgesic Dose (mg)	240.3±49.34	396.6±41.38
VAS score	5.07±0.11	6.60±0.39

**DISCUSSION**

Unrelieved pain after surgery can interfere with sleep and physical functioning and can negatively affect a patient's well-being on multiple levels [8]. Inadequate pain control may result in increased morbidity or mortality [9]. Pharmacological agents like opioids, ketamine, nonsteroidal anti-inflammatory drugs, alpha-2 agonists, and paracetamol or regional procedures like epidural catheterization are usual methods of post-operative pain relief [3]. Despite this overwhelming rationale for effective postoperative pain control, clinically the results are not satisfactory [10]. TAP block is a regional nerve block used to provide analgesia to anterior and lateral abdominal wall which involve injection of long acting local anaesthetic through lumbar triangle of petit into the plane between

the transversus abdominis and internal oblique muscle to block the thoracolumbar intercostal nerves [11].

Levobupivacaine, an S (-) isomer of racemic bupivacaine is a newer long acting local anaesthetic with a lower toxicity (especially cardiac) and similar potency as bupivacaine [7].

Selected groups were comparable for the demographic variables like age and weight parameters, type and duration of surgery and sex with  $P > 0.05$

Heart rate, SBP, DBP and MAP were comparable in both the study groups throughout the perioperative period except at the time before the need of rescue analgesia as the pain started.

Nanze Y *et al.* [12] found no significant change in HR, SBP, DBP and MAP perioperatively in three study groups at various time interval ( $p > 0.05$ ).

Bhattacharjee S *et al.* [13] in their study with TAP block in patients undergoing total abdominal hysterectomy found no significant changes in HR, SBP, DBP and MAP in study groups postoperatively.

Kabariety R E *et al.* [14] & Venkatraman R *et al.* [15] observed that no significant change in HR, SBP, DBP and MAP post-operatively among all the three groups they took in their study at various time intervals ( $p > 0.05$ ).

The time for first rescue analgesia in group L was significantly more as compared to group C ( $p < 0.05$ ) thus, Levobupivacaine hydrochloride (0.25%) seems to provide longer duration of analgesia as compared to the control group.

Saxena A *et al.* [16] concluded that patient given saline made their first request for analgesics significantly sooner than the levobupivacaine group ( $p < 0.05$ ).

Cansiz K H *et al.* [17] concluded that time for first rescue analgesic dose was earlier in control group as compare to Levobupivacaine group ( $p < 0.05$ ).

Thus the above studies did earlier show result in favour of our study. Also, total analgesic consumption at 24 hours between two groups was significantly less in group L as compared to control group ( $p < 0.05$ ).

Papagiaunopoulou P *et al.* [18] showed lesser consumption of analgesics in Levobupivacaine group and Ropivacaine group ( $p < 0.01$ ) in comparison of control ( $p < 0.001$ ) group.

Mohamed A Z E A *et al.* conclude that total dose of tramadol required less in 0.5% ropivacaine group when compared with the control group.

Peterson P L *et al.* [19] Sinha *et al.* [20] & Mankikar M G *et al.* [21] concluded with less VAS score in drug group when compared to the control group thus, all shows result in accordance with our study.

## CONCLUSION

This study was carried out to study effect of transversus abdominis plane block using levobupivacaine for post-operative analgesia in patients undergoing open prosectomy.

We conclude that TAP block using 0.25% levobupivacaine when given at the end of open prosectomy,

results in less analgesia requirement in 24 hours, prolongation of time of first rescue analgesia and reduced VAS score in levobupivacaine group thus shows better post-operative analgesia when compared to the control group.

## REFERENCES

1. Corke, P. (2013). Postoperative pain management. *Aust Prescr.* 36(6):202-5.
2. Mishra, A. K., Afzal, M., Mookerjee, S. S., Bandyopadhyay, K. H., & Paul, A. (2013). Pre-emptive analgesia: Recent trends and evidences. *Indian Journal of Pain*, 27(3), 114.
3. Sharma, P. (2013). Evaluation of postoperative analgesic efficacy of transversus abdominis plane block after abdominal surgery: A comparative study. *Journal of natural science, biology, and medicine*, 4(1), 177.
4. Salman, A. E., Yetişir, F., Yürekli, B., Aksoy, M., Yildirim, M., & Kiliç, M. (2013). The efficacy of the semi-blind approach of transversus abdominis plane block on postoperative analgesia in patients undergoing inguinal hernia repair: a prospective randomized double-blind study. *Local and regional anesthesia*, 6, 1.
5. Rafi, A. N. (2001). Abdominal field block: a new approach via the lumbar triangle. *Anaesthesia*, 56(10), 1024-1026.
6. Hebbard, P., Fujiwara, Y., Shibata, Y., & Royse, C. (2007). Ultrasound-guided transversus abdominis plane (TAP) block. *Anaesthesia and intensive care*, 35(4), 616-618.
7. Bajwa, S. J. S., & Kaur, J. (2013). Clinical profile of levobupivacaine in regional anesthesia: A systematic review. *Journal of anaesthesiology, clinical pharmacology*, 29(4), 530.
8. Corke, P. (2013). Postoperative pain management. *Australian Prescriber*. Dec;36(6).
9. Rajesh, A. (2015). Safety and efficacy of tramadol compared to diclofenac in relieving postoperative pain. *Journal of Evidence Based Medicine and Healthcare*, 2(21), 3103-3110.
10. Vadivelu, N., Mitra, S., & Narayan, D. (2010). Recent advances in postoperative pain management. *The Yale journal of biology and medicine*, 83(1), 11.
11. Mukhtar, K. (2009). Transversus abdominis plane (TAP) block. *J NYSORA*, 12, 28-33.
12. Yu, N., Long, X., Lujan-Hernandez, J. R., Succar, J., Xin, X., & Wang, X. (2014). Transversus abdominis-plane block versus local anesthetic wound infiltration in lower abdominal surgery: a systematic review and meta-analysis of randomized controlled trials. *BMC anesthesiology*, 14(1), 121.
13. Bhattacharjee, S., Ray, M., Ghose, T., Maitra, S., & Layek, A. (2014). Analgesic efficacy of transversus abdominis plane block in providing effective perioperative analgesia in patients undergoing total abdominal hysterectomy: a randomized controlled

- trial. *Journal of anaesthesiology, clinical pharmacology*, 30(3), 391.
14. El-Kabariety, R. (2013). Tramadol as an adjuvant to levobupivacaine in an ultrasound-guided transversus abdominis plane block in women undergoing abdominal hysterectomy. *Ain-Shams Journal of Anaesthesiology*, 6(3), 304-304.
  15. Venkatraman, R., Abhinaya, R. J., Sakthivel, A., & Sivarajan, G. (2016). Efficacy of ultrasound-guided transversus abdominis plane block for postoperative analgesia in patients undergoing inguinal hernia repair. *Local and regional anesthesia*, 9, 7.
  16. Saxena, A., Gupta, A., Mitra, D., Singhal, J., & Agarwal, M. (2016). To evaluate the efficacy of novel approach to transversus abdominis plane block for postoperative analgesia after abdominal surgeries. *Saudi Surgical Journal*, 4(1), 29.
  17. Cansız, K. H., Yedekçi, A. E., Şen, H., Özkan, S., & Dağlı, G. (2015). The effect of ultrasound guided transversus abdominis plane block for caesarean delivery on postoperative analgesic consumption. *Gulhane Medical Journal*, 57(2).
  18. Papagiannopoulou, P., Argiriadou, H., Georgiou, M., Papaziogas, B., Sfyra, E., & Kanakoudis, F. (2003). Preincisional local infiltration of levobupivacaine vs ropivacaine for pain control after laparoscopic cholecystectomy. *Surgical Endoscopy and Other Interventional Techniques*, 17(12), 1961-1964.
  19. Petersen, P. L., Hilsted, K. L., Dahl, J. B., & Mathiesen, O. (2013). Bilateral transversus abdominis plane (TAP) block with 24 hours ropivacaine infusion via TAP catheters: a randomized trial in healthy volunteers. *BMC anesthesiology*, 13(1), 30.
  20. Sinha, S., Palta, S., Saroa, R., & Prasad, A. (2016). Comparison of ultrasound-guided transversus abdominis plane block with bupivacaine and ropivacaine as adjuncts for postoperative analgesia in laparoscopic cholecystectomies. *Indian journal of anaesthesia*, 60(4), 264.
  21. Mankikar, M. G., Sardesai, S. P., & Ghodki, P. S. (2016). Ultrasound-guided transversus abdominis plane block for post-operative analgesia in patients undergoing caesarean section. *Indian journal of anaesthesia*, 60(4), 253.