

Original Research Article

Immunohistochemical analysis of expression of Estrogen Receptor on surface epithelial ovarian neoplasms and its role as a prognostic marker in them

Mahak Wadhwa¹, Khushboo Juneja², Vaibhav Gupta³, Samreen Khan⁴, Nazoora Khan⁵, Abhishek Singh⁶

¹Consultant Pathologist, Pt. Deen Dayal Upadhyay Joint Hospital, Aligarh, U. P.

²Assistant Professor, Department of Community Medicine, SMS & R, Sharda University, Greater Noida, U.P.

³Consultant Microbiologist, Pt. Deen Dayal Upadhyay Joint Hospital, Aligarh, U. P.

⁴Senior Resident, Department of Community Medicine, J.N.M.C.H., A.M.U

⁵Professor, Department of Pathology, J.N.M.C.H., A.M.U.

⁶Assistant Professor, Department of Community Medicine, SHKM Govt. Medical College, Nalhar, Haryana

*Corresponding Author:

Dr. Khushboo Juneja

Email: khushboojuneja22@gmail.com

Abstract: Cancer of the ovary represents about 30% of all gynaecological cancers. Surface epithelial tumours are the most commonly diagnosed subgroup. The present study included 80 cases of ovarian tumours diagnosed over a period of 5 years (4 years retrospective and 1 year prospective). The tumours were broadly classified into benign, borderline and malignant groups. The strength of ER expression increased on progressing from benign to malignant tumour morphology. An increase in ER staining grade was observed with increasing FIGO stage. Anti-ER therapy may potentially be of use in patients with advanced disease.

Keywords: Estrogen receptor, Surface epithelial ovarian neoplasms.

INTRODUCTION

Ovarian cancers are one of the most common causes of mortality among females the world over, ranking next to cervical, breast and colorectal cancer. The global age standardised incidence of ovarian carcinoma is 6.1 per 1 lac population and the mortality rate is 4.2 per 1 lac population. India is not far behind, with an incidence of 4.9 per 1 lac population and a mortality rate of 3.6 per 1 lac population [1]. A direct action of gonadal steroids in ovarian carcinogenesis has been suggested [2, 3]. Translated proteins of estrogen (ER) and progesterone receptor (PR) have been detected in both normal ovarian tissue and in malignant ovarian tumors [2, 4, 5].

AIMS AND OBJECTIVES

- To identify and subtype benign and malignant epithelial ovarian neoplasms and apply immunohistochemical marker ER on tissue sections.
- To assess Estrogen Receptor expression in relation to FIGO stage.

MATERIALS & METHODS

The present study was conducted on 80 patients presenting with signs and symptoms of ovarian neoplasms attending the outdoor and indoor clinics of

the Department of Obstetrics and Gynaecology, Jawaharlal Nehru Medical College, Aligarh Muslim University, Aligarh, (U.P) over a period of 5 years (4 years retrospective and 1 year prospective), from 2010 to 2014. A detailed history, findings of clinical examination, including local examination and relevant investigations were recorded in each case. Routine histopathological and immunohistochemical examination of sections from the surgical specimens of surface epithelial ovarian neoplasms was conducted in the Department of Pathology.

Tumours sections were cut for immunohistochemical assay of Estrogen Receptors (3-4 μ in thickness). These were taken on poly-L-lysine coated clean glass slides. One positive and negative control was set up simultaneously and stained according to the following protocol: Positive control taken was Invasive ductal carcinoma breast for ER. Negative controls were Primary antibody omission. Sections were stained according to the following IHC protocol. For the assessment of **Estrogen Receptor** immunohistochemically stained slides were examined for proportion and intensity of staining of tumor cells. Final scoring was done using Histo score (H-Score) system as described by Farooq *et al.* [6].

H-Score= 3 x percentage of strongly staining nuclei + 2 x percentage of moderately staining nuclei +

percentage of weakly staining nuclei, giving a range of 0 to 300.

GRADING	TOTAL H-SCORE	INTERPRETATION
0	0-50	Negative
1	51-100	Weakly Positive
2	101-200	Moderately Positive
3	201-300	Strongly Positive

The statistical analysis was carried out using SPSS software (v.15.0, USA). **Chi square** or **Fisher's exact test**. p value of <0.05 was considered to be statistically significant. Descriptive data were tabulated

as numbers and percentages. Pictorial representations in the forms of bar diagrams and pie charts were provided wherever necessary.

SEROUS CYSTADENOMA (IHC)

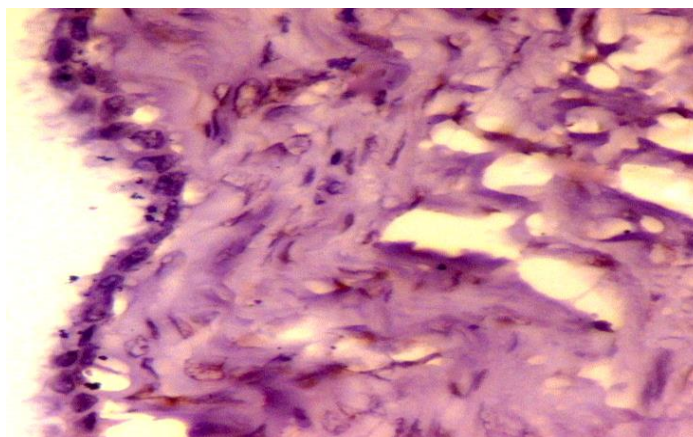


Fig-1: IHC for ER showing negative ER expression (10x)

SEROUS BORDERLINE TUMOUR (IHC)

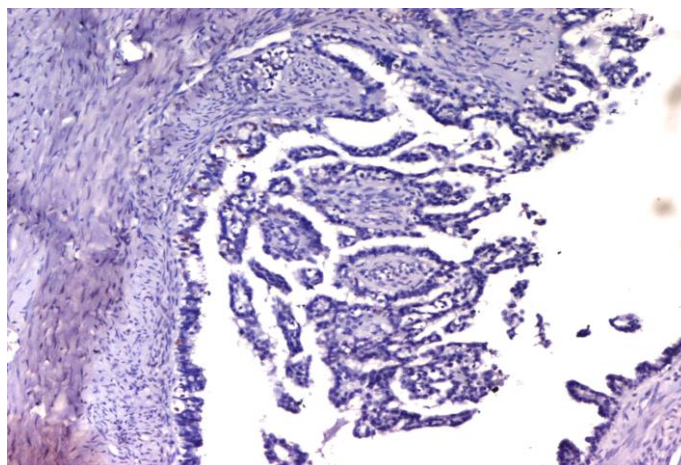


Fig-2: IHC for ER showing negative ER expression (10x)

SEROUS CYSTADENOCARCINOMA (IHC)

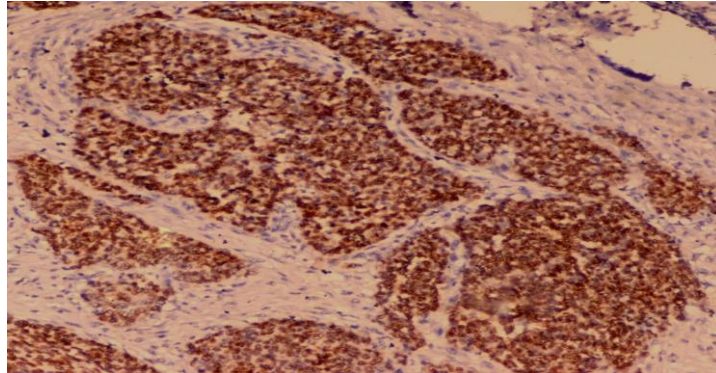


Fig-3: IHC for ER showing strong (3+) nuclear positivity in tumour cells (10x)

MUCINOUS CYSTADENOMA (IHC)

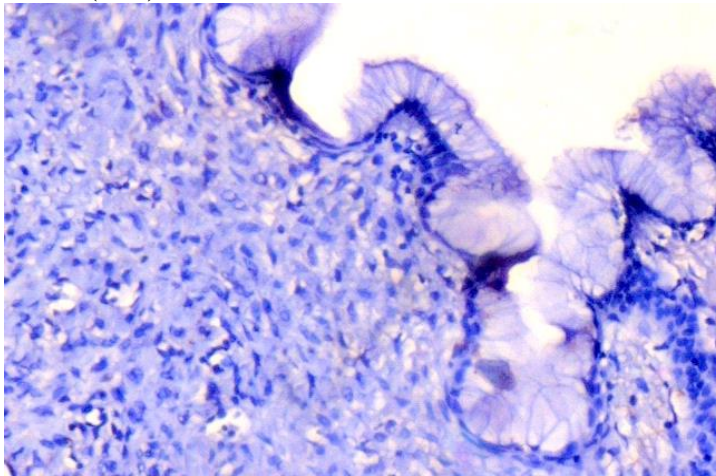


Fig-4: IHC for ER showing negative ER expression (10x)

MUCINOUS BORDERLINE TUMOUR (IHC)

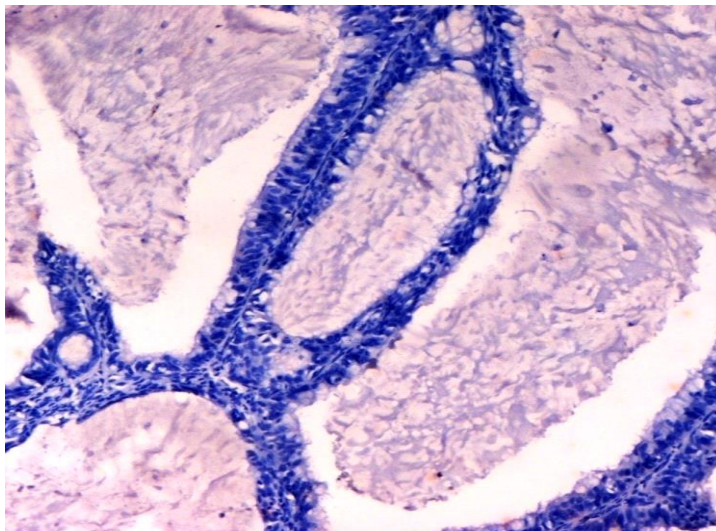


Fig-5: IHC for ER showing negative ER expression (10x)

MUCINOUS CYSTADENOCARCINOMA (IHC)

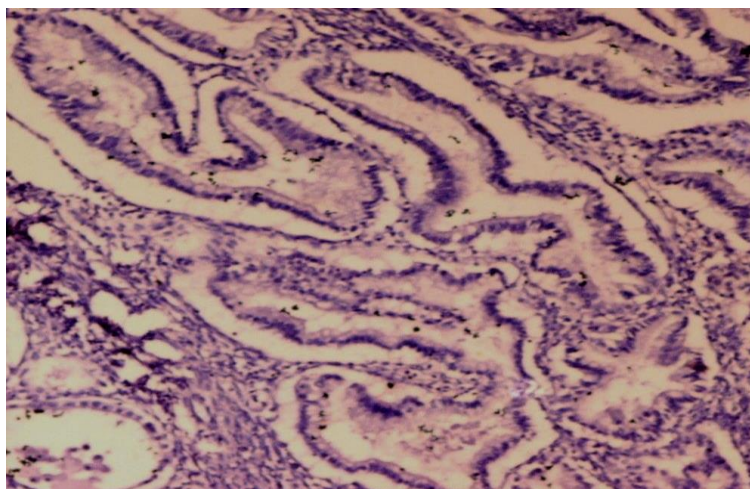


Fig-6: IHC for ER showing negative ER expression (10x)

RESULTS

Total cases (80) of surface epithelial ovarian tumours were broadly classified into 3 main categories depending on the diagnosis. A. Benign tumours B.Borderline tumours. C. Malignant tumours.

Chart 1. show the distribution of cases of surface epithelial ovarian tumours according to age. The

peak incidence of all epithelial ovarian tumours was observed in the 5th decade (26 cases-32.5%), followed by 20 cases in the age group of 21 to 30 years. In this study, the youngest patient was 15 years old, diagnosed with mucinous cystadenoma and the oldest was 65 years old, diagnosed with serous cystadenocarcinoma.

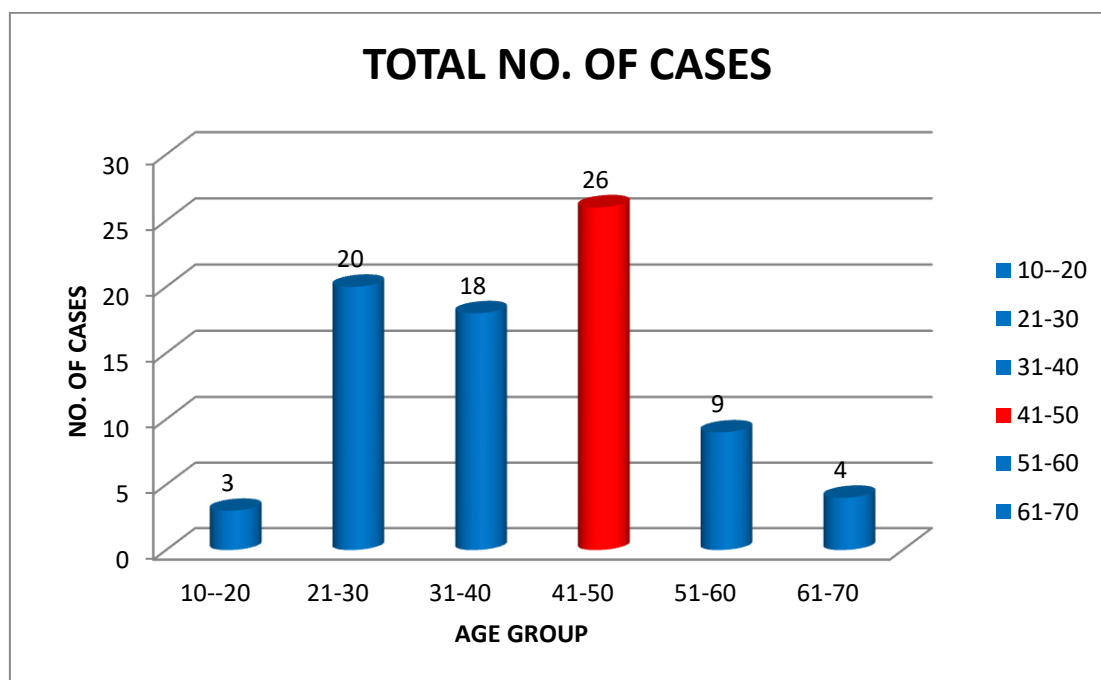


Chart-1: Distribution of cases of surface epithelial ovarian tumours according to age.

Chart 2 shows the breakup of surface epithelial ovarian tumours according to different types has been depicted in Figure 2. Benign tumours were reported in 45 cases constituting 56.3% of all tumours.

Borderline tumours were 8 in number, accounting for only 10% of all tumours, while malignant cases were 27 in number (33.75%).

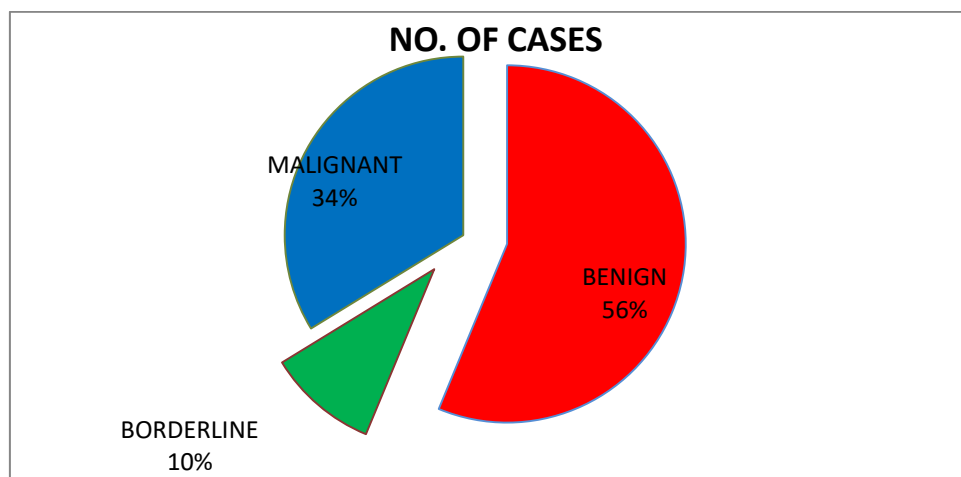


Chart-2: Distribution of cases according to different types of surface epithelial ovarian tumours

Immunohistochemical staining for ER was carried out in 40 neoplasms. Table 1 show ER expression in surface epithelial ovarian tumours. Most of the benign tumours (70.5%) and borderline tumours (85.7%) stained negative while the majority of

malignant tumours showed strong (3+) positivity for estrogen receptor (37.5%). In case of borderline tumours, the majority showed negative staining. The difference in ER expression across the 3 different categories of ovarian tumours was significant ($p < 0.05$).

Table-1: ER expression in different types of surface epithelial ovarian tumours

S No.	Tumour Type	ER staining grade				Total	P value
		0	1+	2+	3+		
1	Benign	12(70.5%)	3(17.6%)	2(11.9%)	0(0%)	17	P<0.05
2	Borderline	6(85.7%)	0(0%)	0(0%)	1(14.3%)	7	
3	Malignant	5(31.2%)	2(12.5%)	3(18.8%)	6(37.5%)	16	
	Total	23	5	5	7	40	

Table 2 show the ER expression in different histopathological types of surface epithelial ovarian tumours. In Benign type, Serous cystadenomas showed negative ER staining in 88.9% of cases (fig.1) while 50% of mucinous cystadenomas were ER negative (fig.4). The difference in expression of ER between serous cystadenomas and mucinous cystadenomas was not significant ($p > 0.05$). Both serous and mucinous borderline tumours showed negative staining with ER in majority of cases (fig.2 and fig.5 respectively). The

difference in expression of ER between serous and mucinous borderline tumours was not significant ($p > 0.05$). ER expression in malignant surface epithelial ovarian tumours is that majority (60%) of serous cystadenocarcinomas exhibited strong positivity (3+) (fig. 3), while most (67%) of mucinous cystadenocarcinomas were stained negative for ER (fig.6). The difference in ER expression in serous cystadenocarcinomas was significant as compared to mucinous cystadenocarcinomas ($p < 0.05$).

Table-2: ER expression in different histopathological types of surface epithelial ovarian tumours

S No.	Histopathological Diagnosis	ER staining grade				Total	P value
		0	1+	2+	3+		
Benign							p>0.05
1	Serous Cystadenoma	8(88.9%)	1(11.1%)	0(0%)	0(0%)	9	
2	Mucinous Cystadenoma	4(50%)	2(25%)	2(25%)	0(0%)	8	
	Total	12	3	2	0	17	
Borderline							p>0.05
1	Serous Borderline Tumour	5(83.3%)	0(0%)	0(0%)	1(16.7%)	6	
2	Mucinous Borderline Tumour	1(100%)	0(0%)	0(0%)	0(0%)	1	
	Total	6	0	0	1	7	
Malignant							p<0.05
1	Serous Ca	1(1%)	0(0%)	3(30%)	6(60%)	10	
2	Mucinous Ca	4(67%)	2(33%)	0(0%)	0(0%)	6	
	Total	5	2	3	6	16	

Table 3 depict the variation in ER expression in relation to FIGO stage in surface epithelial ovarian carcinomas. Majority of the tumours which exhibited strong (3+) positivity for ER was in stage III (66.6%). Most of the stage I tumours were negative for ER. An

increase in the H- score was noted on progressing from stage I to stage III. On comparing the ER expression between these three stages, the difference was found to be statistically significant ($p < 0.05$).

Table-3: ER expression in relation to FIGO stage in surface epithelial ovarian carcinomas

S No.	Stage	ER staining grade				Total	P value
		0	1+	2+	3+		
1	FIGO I	4(100%)	0(0%)	0(0%)	0(0%)	4	$p < 0.05$
2	FIGO II	1(17%)	2(33%)	1(17%)	2(33%)	6	
3	FIGO III	0(0%)	0(0%)	2(33.4%)	4(66.6%)	6	
Total		5	2	3	6	16	

DISCUSSION

The benign tumours were seen mainly in 3rd decade of life whereas malignant tumours were more common in the 5th decade. Similar observations were recorded by other studies [7, 8]. Out of these 80 cases of surface epithelial ovarian tumours, 45 were benign (56.3%), 8 were borderline (10%) and 27 were malignant (33.7%). Similarly, Pilli *et al.* [7] observed benign tumours to be more common (75.2%) followed by borderline (2.8%) and malignant tumours (21.9%). Farooq *et al.* [6] also noted that out of 144 cases of surface epithelial ovarian tumours, 75% cases were benign, 3.48% were borderline and 21.52% were malignant. Our findings are in accordance with the observations of these two studies. On histopathological examination of the tissue sections, serous cystadenomas were more frequently diagnosed (55.5% of the total) as compared to mucinous cystadenomas (44.5%). Our results are in agreement with those of Kanthikar *et al.* [9] who reported the serous variants to be more common amongst the cystadenomas.

Again, in both the borderline and malignant histopathological categories, serous tumours were more common in comparison to mucinous tumours. Lenhard *et al.* [8] reported similar findings. In their data, serous cystadenocarcinomas constituted 70.5% of all tumours while mucinous cystadenocarcinomas were only 13.5% of the total. Immunohistochemical staining for ER and EGFR was carried out in 40 neoplasms. Out of these 40 cases, 17 were benign, 7 were borderline and 16 were malignant.

In our study, ER expression was lower in the benign group, with only 30% tumours showing ER positivity. While majority of benign tumours showed negative staining, a strong (3+) positivity was recorded in most cases of malignant tumours (37.5%). This was in agreement with the findings of Farooq *et al.* [6] who observed ER expression in 20% of benign tumours and 61.5% of malignant tumours. Similarly, in a study by Damiao *et al.* [10] also reported similar finding. Of note is the observation that, in our study, the difference in ER immunoreactivity across the different categories of

tumours (benign, borderline and malignant) was statistically significant ($p < 0.05$). ER expression in benign surface epithelial ovarian tumours was negative in both serous cystadenomas and mucinous cystadenomas (88.9% and 50% of cases respectively). Importantly, our results parallel those of other workers. Farooq *et al.* [6] reported ER to be negative in 80% of benign ovarian tumours. Similar observations were published where only 29% of benign tumours showed ER positivity [11].

Both serous and mucinous borderline tumours showed negative staining with ER in majority of cases. The difference in expression of ER between serous and mucinous borderline tumours was not significant ($p > 0.05$).

In our study, strong (3+) ER positivity was noted in serous cystadenocarcinomas as compared to mucinous cystadenocarcinomas where majority of tumours exhibited negative ER expression. Also, the difference in ER expression between serous and mucinous cystadenocarcinomas was significant ($p < 0.05$). Farooq *et al.* [6] also reported ER positivity to be higher in serous cystadenocarcinomas as compared to mucinous cystadenocarcinomas. Similar results were obtained in the study where estrogen receptor expression was positive in 70.5% of serous carcinomas as compared to mucinous carcinomas, where only 13.5% of cases showed ER positivity [8].

This difference in ER expression between serous and mucinous tumours may be attributed to the fact that STAT-3 is overexpressed in serous cystadenocarcinomas while mucinous cystadenomas are associated with other pathways. Since, estrogen receptors act through the STAT-3 pathway, ER expression is expected to be higher in serous cystadenocarcinomas than mucinous malignant tumours [12].

Majority of the tumours showing strong ER positivity (3+) were in FIGO stage III (66.6%), while stage I tumours had negative staining. ER expression

became progressively stronger with advancing disease stage. Also the difference in ER expression between different stages was significant ($p < 0.05$). Farooq *et al.* [6] also observed that ER positivity in ovarian cancers increased with increasing FIGO stage. Similar observations were made by Hogdall *et al.* [13] where an increase in ER expression was noted with increasing stage of the tumour. Kurman *et al.* [14] reported that early stage ovarian carcinomas express mutations in K-RAS and PTEN genes. However, advanced stage carcinomas are characterized by mutations in TP53 and STAT-3 genes. Since ER acts through the STAT-3 pathway, this may explain why ER expression becomes more evident with advancing stage.

CONCLUSION

Our findings indicate that estrogen has a role to play in ovarian carcinogenesis and anti-estrogen therapy may benefit patients who are either refractory to platinum therapy or those who develop early resistance to platinum. This is especially applicable to serous neoplasms as this group has consistently shown strong ER positivity. This opens up possible avenues of research regarding treatment, especially in platinum refractory and resistant cases. Estrogen receptor expression can be used as prognostic marker in surface epithelial ovarian carcinomas as its expression increases with FIGO staging.

Acknowledgment

I would like to express my profound gratitude to all the participants for their co-operation and for their immense faith they reposed in me.

REFERENCES

1. Ferlay, J., Shin, H. R., Bray, F., Forman, D., Mathers, C., & Parkin, D. M. (2012). Cancer Incidence and Mortality Worldwide: IARC CancerBase No. 10 [Internet]. International Agency for Research on Cancer, Lyon, France. GLOBOCAN 2008 v1. 2.
2. Clinton, G. M., & Hua, W. (1997). Estrogen action in human ovarian cancer. *Critical reviews in oncology/hematology*, 25(1), 1-9.
3. Risch, H. A. (1998). Hormonal etiology of epithelial ovarian cancer, with a hypothesis concerning the role of androgens and progesterone. *Journal of the National Cancer Institute*, 90(23), 1774-1786.
4. Rao, B. R., & Slotman, B. J. (1991). Endocrine factors in common epithelial ovarian cancer. *Endocrine reviews*, 12(1), 14-26.
5. Münstedt, K., Steen, J., Knauf, A. G., Buch, T., von Georgi, R., & Franke, F. E. (2000). Steroid hormone receptors and long term survival in invasive ovarian cancer. *Cancer*, 89(8), 1783-1791.
6. Farooq, S., Tasleem, R., Nazir, N., Reshi, R., & Hassan, Z. (2013). Histopathological Pattern of Ovarian Neoplasms and Estrogen and Progesterone Receptor Expression in Primary Epithelial Tumours and Their Histopathological Correlation. *International Journal of Current Research and Review*, 5(21), 70.
7. Pilli, G. S., Suneeta, K. P., Dhaded, A. V., & Yenni, V. V. (2002). Ovarian tumours: a study of 282 cases. *Journal of the Indian Medical Association*, 100(7), 420-423.
8. Lenhard, M., Tereza, L., Heublein, S., Ditsch, N., Himsl, I., Mayr, D., ... & Jeschke, U. (2012). Steroid hormone receptor expression in ovarian cancer: progesterone receptor B as prognostic marker for patient survival. *BMC cancer*, 12(1), 553.
9. Kanthikar, S. N., Dravid, N. V., Deore, P. N., Nikumbh, D. B., & Suryawanshi, K. H. (2014). Clinico-Histopathological analysis of neoplastic and non-neoplastic lesions of the ovary: A 3-Year prospective study in Dhule, North Maharashtra, India. *Journal of clinical and diagnostic research: JCDR*, 8(8), FC04.
10. De Sousa Damião, R., Fujiyama Oshima, C. T., Stávale, J. N., & Gonçalves, W. J. (2007). Analysis of the expression of estrogen receptor, progesterone receptor and chicken ovalbumin upstream promoter-transcription factor I in ovarian epithelial cancers and normal ovaries. *Oncology reports*, 18(1), 25-32.
11. Sylvia, M. T., Kumar, S., & Dasari, P. (2012). The expression of immunohistochemical markers estrogen receptor, progesterone receptor, Her-2-neu, p53 and Ki-67 in epithelial ovarian tumors and its correlation with clinicopathologic variables. *Indian journal of pathology and microbiology*, 55(1), 33.
12. Mhawech-Fauceglia, P., Afkhami, M., & Pejovic, T. (2012). MET/HGF signaling pathway in ovarian carcinoma: Clinical implications and future direction. *Pathology research international*, 2012.
13. Høgdall, E. V., Christensen, L., Høgdall, C. K., Blaakaer, J., Gayther, S., Jacobs, I. J., ... & Kjaer, S. K. (2007). Prognostic value of estrogen receptor and progesterone receptor tumor expression in Danish ovarian cancer patients: from the 'MALOVA' ovarian cancer study. *Oncology reports*, 18(5), 1051-1059.
14. Kurman, R. J., Visvanathan, K., Roden, R., Wu, T. C., & Shih, I. M. (2008). Early detection and treatment of ovarian cancer: shifting from early stage to minimal volume of disease based on a new model of carcinogenesis. *American journal of obstetrics and gynecology*, 198(4), 351-356.