

Case Report

Cryptococcus neoformans: An Opportunistic Pathogen with an Unusual Presentation in a Renal Transplant Recipient

Nathany Shrinidhi¹, Sagar Siddharth², Sharma Swati³, Prabhu Ravindra⁴, K.E. Vandana⁵

¹Department of Pathology, Kasturba Medical College, Manipal, Manipal University, India.

²Department of Microbiology, Kasturba Medical College, Manipal, Manipal University, India.

³Department of Pathology, Kasturba Medical College, Manipal, Manipal University, India

⁴Department of Nephrology, Kasturba Medical College, Manipal, Manipal University, India

⁵Department of Microbiology, Kasturba Medical College, Manipal, Manipal University, India

*Corresponding Author:

Sharma Swati

Email: swatisharma79@yahoo.com

Abstract: Cryptococcal infection is characteristically associated with immunocompromised status. In most cases, the skin lesions represent a sentinel finding for disseminated cryptococcal infection. We describe a case of a 34 year old male, a solid organ transplant recipient (SOT), on immunosuppression, presenting with necrotising fasciitis of right lower limb. On microbiological and histopathological examination, a diagnosis of disseminated cryptococcal infection was made. In this report, we describe the spectrum of disease associated with *Cryptococcus*, its life cycle, pathogenesis and Immune Reconstitution Inflammatory Syndrome (IRIS). Cryptococcosis is a serious infection among SOT recipients, with diverse clinical features. This report underscores the need for a multidisciplinary clinical research and education from the Indian perspective.

Keywords: *Cryptococcus*, opportunistic, renal transplant

INTRODUCTION

Cryptococcus neoformans, an encapsulated, heterobasidiomycetous, opportunistic human pathogen, is now common worldwide, owing to the dramatic increase in immunocompromised people over the last two decades [1]. It is the third most common fungal pathogen in SOT recipients following candida and aspergillus [2]. The most common manifestation of this infection is meningitis although secondary involvement of skin and lungs are well documented in literature. This has been attributed to haematological dissemination. Disseminated cryptococcosis is defined by 1) a positive culture from at least two different sites, or 2) a positive blood culture[3] The French Cryptococcosis Study Group in 2003 demonstrated skin to be a portal of entry and a potential source of succeeding disseminated infection in SOT recipients [4]. We report here a case of cutaneous Cryptococcosis in a renal transplant recipient, with due consent obtained from him.

CASE REPORT

A 34 year old male patient, a known case of haemodialysis-dependent IgA nephropathy underwent renal transplant in February 2015 at our hospital. The transplant was a live related donor and it was a 2/6 mismatch. The pre-transplant kidney biopsy revealed

focal mesangioproliferative glomerulonephritis with IgA deposits with focal crescents – class III Haas classification [5]. The postoperative period subsequent to transplant was uneventful and the patient was discharged with basiliximab induction and triple immunosuppression comprising of calcineurin inhibitors, tacrolimus, prednisolone and mycophenolate mofetil along with routine anti-hypertensives and nutrition supplements. Subsequently, the patient was admitted for repeated transplant biopsies, which revealed acute cell-mediated rejection with acute tubular injury, however he was managed conservatively.

In January 2016, the patient presented with rising serum creatinine and persistent thrombocytopenia. He was evaluated for BK virus nephropathy, JC Polyoma virus, Parvovirus B19 and Cytomegalovirus (CMV) infections. Viral Polymerase Chain Reaction (PCR) for BK virus and CMV DNA were positive whereas Parvovirus B19 yielded a negative result. Urine examination for decoy cells was negative indicating the absence of JC Polyoma virus. The patient was managed with intravenous ganciclovir for CMV and intravenous immunoglobulin for BK virus nephropathy and subsequent reports of the aforementioned were negative.

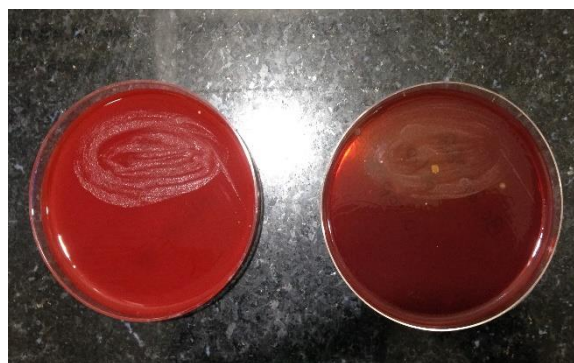


Fig 1a. Small, moist, non-haemolytic colonies on Blood Agar; 1b. Pinpoint colonies on MacConkey Agar

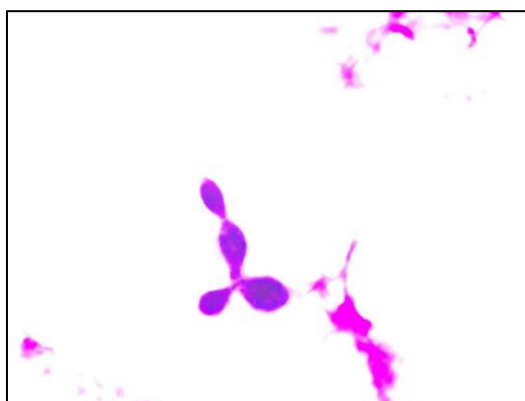


Fig-2: Gram positive, round, budding yeast cells, x 1000, Gram Stain

In October 2016, he presented with complaints of pain, swelling, and redness in the right lower limb. On local examination, ulcers were noted on the right thigh and near the ankle. There was no history of trauma, hence a clinical diagnosis of necrotising fasciitis was considered. The serum creatinine at admission was 7.1 mg/dl (normal range 0.6-1.4 mg/dl). A Venous Doppler was done to rule out deep vein thrombosis. The blood and ascitic fluid sent for cultures in BacT/Alert Automated Blood Culture System revealed *C. neoformans*. Gram stain showed moderate

pus cells and numerous Gram positive, encapsulated, round, budding yeast cells suggestive of *Cryptococcus spp.* The patient underwent four wound debridement surgeries for the ulcers, and the tissues were submitted for histopathological examination. Microscopy showed features of necrotising fasciitis with numerous spherical, narrow-based, budding, encapsulated yeast cells. The yeast cells were positive for periodic acid Schiff (PAS) and mucicarmine suggesting *C. neoformans*, correlating with culture reports.

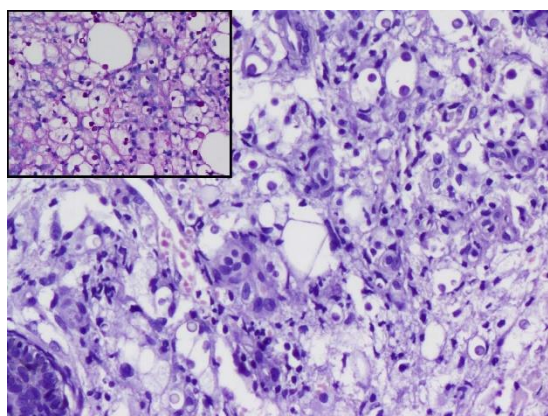


Fig-3: Spores of Cryptococcus along with mixed inflammatory infiltrate -x 200 H & E; Inset shows PAS positive spores suggestive of *C. neoformans*

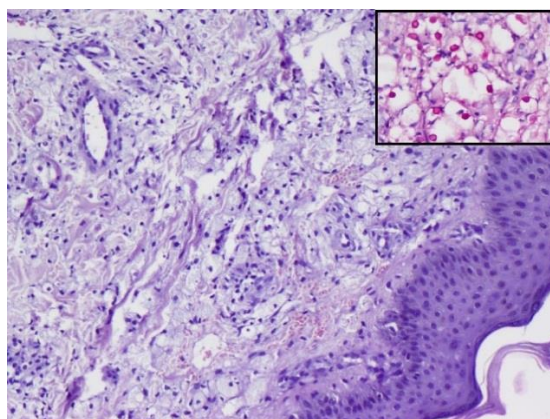


Fig-4. Skin with dermis showing multiple, narrow-based encapsulated fungal spores –x 100, H & E; Inset shows Mucicarmine positive spores suggestive of *C. neoformans* - x 400

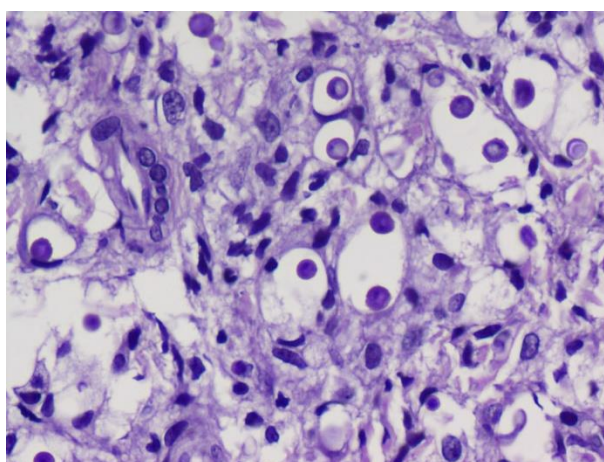


Fig-5. Round, budding, narrow-based yeast cells of *C. neoformans* with refractile capsule – x 400, H & E

He was put on an induction phase of therapy with liposomal amphotericin B (6mg/kg/day) and flucytosine 100 mg/kg daily and presently is in the consolidation phase with fluconazole (400 mg/day

DISCUSSION

Cryptococcosis is seen in nearly 2.8% cases of SOT recipients. The median time to disease onset is 21 months following transplantation, 68.5% cases occurring 1 year after transplant [6]. Approximately 25-54% of SOT recipients with cryptococcosis have pulmonary involvement, and in 6-33% the disease is limited to the lungs only [6]. CNS involvement and disseminated infections (involvement of ≥ 2 sites) have been reported in 52-61% of patients [6]. Approximately 25% of SOT recipients with *C. neoformans* disease have disseminated infection [6].

The spectrum of disease consists predominantly of meningoencephalitis and pneumonia, but skin and soft tissue infections may also occur. Other sites of infection include the prostate, peritoneum and eye. Cryptococcus infection is usually considered as a reactivation of a quiescent infection, although not well

prescribed for 8 weeks). The patient has an unsatisfactory overall general condition with persisting thrombocytopenia, anaemia and leucocytosis, serum creatinine of 2.1 mg/dl, although vitals are stable.

evidenced [3]. It has been described to be dermatropic in animal models [1]. Another study, in a cohort of SOT recipients showed that, tacrolimus therapy had a higher ratio of skin and soft tissue infections to CNS infections when compared with previous immunosuppressive regimens [7]. This was attributed to the anticryptococcal activity of tacrolimus at temperatures of 37° to 39°C; although at environmental temperatures it loses this property [8]. Thus, skin involvement might result from the lower temperatures at this site. Our patient also had an episode of CMV and BK virus nephropathy, indicating the need for close monitoring of immunosuppression and adequate dose adjustment.

The life cycle of *C. neoformans* involves two distinct forms: asexual and sexual. The asexual stage is that of an encapsulated yeast, which is the primary structure seen in tissue and culture isolates. The sexual stage, the basidiospores, has been hypothesized to be

the infectious propagules. They may deposit in lung, where the spores rapidly convert to yeasts and elicit a granulomatous and Th1 response. The yeasts remain quiescent in tissues and the host is asymptomatic until loss of local immunity occurs, through immunosuppressants or progression of an HIV (human immunodeficiency virus) infection. This causes replication in pulmonary lymph node complex and eventually, dissemination. This pathophysiology is similar to the scenario proposed for reactivation of tuberculosis and histoplasmosis, and may explain the pathogenesis in our patient [1].

IRIS and cryptococcosis are well described with HIV infection and its treatment, but it also occurs as a complication with SOT recipients. With SOT recipients, it occurs with those on potent antirejection regimens (calcineurin inhibitors) that have been tapered after initiation of antifungal therapy. It appears in two forms: unmasking and paradoxical. It is hypothesized that as immunity improves with antiretroviral therapy, latent cryptococcal infections become clinically apparent, as the inflammatory cells interact with the polysaccharide antigen of the fungus. During treatment for cryptococcal meningitis, IRIS manifests as headache, new neurologic signs, inflammatory cells in the CSF (cerebrospinal fluid), and increased intracranial pressure. Distinguishing between immune reconstitution and progressive infection is difficult, but cultures from the CSF and lymph node aspirates are generally negative in IRIS [9].

Cryptococcosis is associated with high rates of morbidity and mortality, despite treatment. The most important prognostic factors include extent and the duration of the predisposing immunologic deficits. Hence, antifungals initiated early prove beneficial for the immunocompetent, but a long term maintenance therapy is required in the immunosuppressed.

CONCLUSION

Disseminated Cryptococcosis with skin involvement has been reported in literature, yet the exact mechanisms of involvement and IRIS still remain elusive. It is usually misdiagnosed as a part of ongoing sepsis and empirical antibiotics delay specific therapy. IRIS in cryptococcosis with its dysregulated immune response needs to be identified, and because there are no specific tests for it, the diagnosis relies on clinical guidelines and judgment. Since our patient had a spectrum of opportunistic pathogens, this case report becomes important not only for clinical diagnosis and management, but also for the laboratory personnel to render an early and appropriate diagnosis.

REFERENCES

1. Perfect JR. (2015). Cryptococcus neoformans and Cryptococcus gattii. In John E. Bennett, Raphael Dolin & Martin J. Blaser (Eds.), Principles and Practice of Infectious Diseases (pp. 2934-2948). Philadelphia, USA: Elsevier Saunders.
2. Chaya, R., Padmanabhan, S., Anandaswamy, V., & Moin, A. (2013). Disseminated Cryptococcosis presenting as cellulitis in a renal transplant recipient. *The Journal of Infection in Developing Countries*, 7(01), 060-063.
3. Chuang, Y. M., Ho, Y. C., Chang, H. T., Yu, C. J., Yang, P. C., & Hsueh, P. R. (2008). Disseminated cryptococcosis in HIV-uninfected patients. *European Journal of Clinical Microbiology & Infectious Diseases*, 27(4), 307-310.
4. Neuville, S., Dromer, F., Morin, O., Dupont, B., Ronin, O., Lortholary, O., & French Cryptococcosis Study Group. (2003). Primary cutaneous cryptococcosis: a distinct clinical entity. *Clinical Infectious Diseases*, 36(3), 337-347.
5. Haas, M. (1997). Histologic subclassification of IgA nephropathy: a clinicopathologic study of 244 cases. *American journal of kidney diseases*, 29(6), 829-842.
6. Perfect, J. R., Dismukes, W. E., Dromer, F., Goldman, D. L., Graybill, J. R., Hamill, R. J., ... & Pappas, P. G. (2010). Clinical practice guidelines for the management of cryptococcal disease: 2010 update by the Infectious Diseases Society of America. *Clinical infectious diseases*, 50(3), 291-322.
7. Kanj, S. S., Welty-Wolf, K., Madden, J., Tapson, V., Baz, M. A., Davis, R. D., & Perfect, J. R. (1996). Fungal infections in lung and heart-lung transplant recipients: report of 9 cases and review of the literature. *Medicine-Baltimore*, 75, 142-156.
8. Odom, A., Del Poeta, M. A. U. R. I. Z. I. O., Perfect, J., & Heitman, J. (1997). The immunosuppressant FK506 and its nonimmunosuppressive analog L-685,818 is toxic to Cryptococcus neoformans by inhibition of a common target protein. *Antimicrobial agents and chemotherapy*, 41(1), 156-161.
9. Singh, N., Lortholary, O., Alexander, B. D., Gupta, K. L., John, G. T., Pursell, K. ... & Limaye, A. P. (2005). An immune reconstitution syndrome-like illness associated with Cryptococcus neoformans infection in organ transplant recipients. *Clinical Infectious Diseases*, 40(12), 1756-1761.