

Leukopenia Associated With Teicoplanin Therapy in Patient with Sickle Cell Anemia: A Case Report

Sultan Mubarki

Clinical Pharmacist, Internal Medicine Specialty, King Fahd Central Hospital, Jazan, Saudi Arabia

Case Report

*Corresponding author

Sultan Mubarki

Article History

Received: 10.11.2017

Accepted: 17.11.2017

Published: 30.11.2017

DOI:

10.36348/sjimps.2017.v03i11.008



Abstract: Teicoplanin induced leukopenia is rare. This case report for 34 years old patient known case of sickle cell anemia diagnosed as osteomyelitis with two episodes of decreased WBC after initiating teicoplanin to cover MRSA strains. WBC increased after drug withdrawal in both episodes. These leukopenias were drug related.

Keywords: Teicoplanin, leukopenia, WBC, sickle cell anemia, osteomyelitis

INTRODUCTION

Teicoplanin is a glycopeptide antibiotic working by binding to acyl-D-alanyl-D-alanine in the bacterial cell wall. The spectrum of activity of teicoplanin is restricted to Gram-positive aerobic and anaerobic bacteria [1]. It is more active than vancomycin against streptococci and Gram-positive anaerobes and Staphylococcus aureus (including methicillin-resistant strains). Haematological side effects of teicoplanin are rare [3] and only few reports showed that the incidence of leukopenia related to teicoplanin is very low [2].

The first case report of teicoplanin induced leukopenia was published in 1989 [2]. It was happened in a 73-year-old man hospitalized because of subacute bacterial endocarditis caused by Streptococcus faecalis and leukopenia developed after 20 days of teicoplanin therapy. Another case report published in 2012 in BMJ of teicoplanin-induced leukopenia in a patient with infective endocarditis resolved after short course of lenograstim, a recombinant granulocyte colony-stimulating factor (G-CSF) reverted biochemical abnormalities [3].

CASE REPORT

34 years old female patient known case of sickle cell anemia came to emergency department with left hip pain, right leg swelling and pain, and back pain for two weeks. She has a history of recent hospitalization with ICU admission. Condition start worsening in the past 5 months and after that she cannot walk because of pain. She has been operated and incision done with fluid drainage from left hip and right femur. Deep wound swap obtained and culture results showed growth of methicillin-resistant Staphylococcus aureus (MSRA) with sensitivity to vancomycin, linezolid and teicoplanin. Based on clinical examination, laboratory results and other findings; patient diagnosed with

osteomyelitis in right femur. Patient started on teicoplanin 800 mg intravenously loading dose followed by 400 mg daily as maintenance dose. Before starting teicoplanin, WBC was in the normal range and start gradually decrease (figure 1). On day 5, teicoplanin stopped because of leukopenia (WBC 2.19), and after that WBC start increasing gradually. On day 14, teicoplanin resumed again with maintenance dose of 400 mg intravenously daily but WBC start decreasing again on day 17, 18, 19 which lead to stop teicoplanin on day 19 and start linezolid 600 mg oral twice daily. After stopping teicoplanin WBC start increasing and reach to the normal range on day 37.

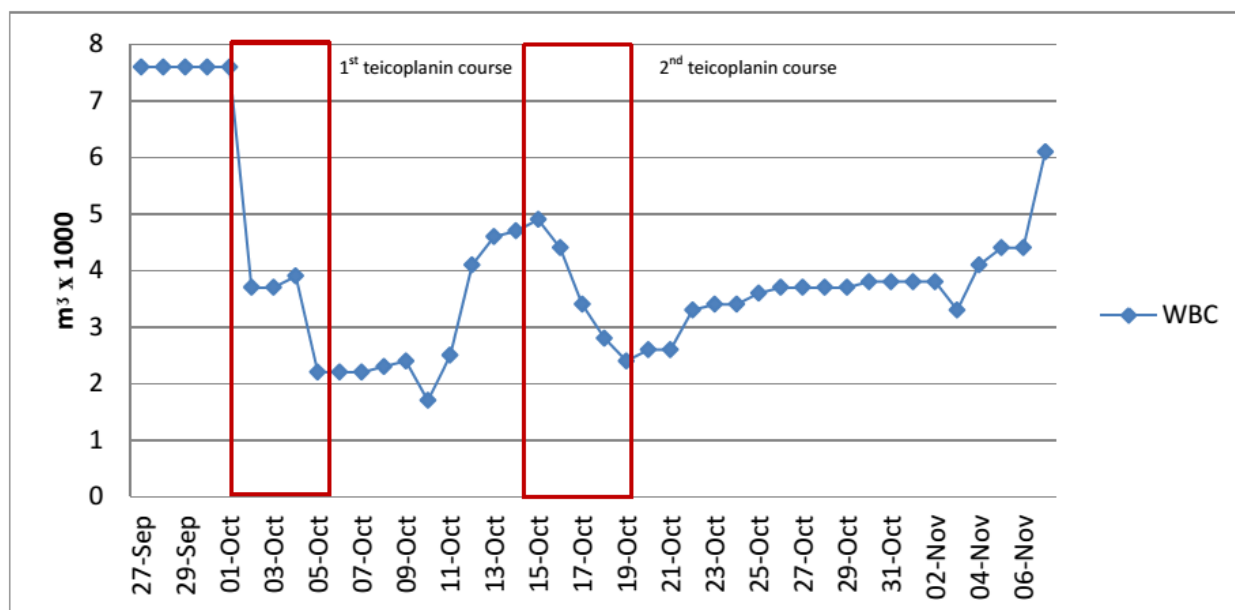


Fig-1: Time relationship between teicoplanin administration and WBC count

Because of the close time relationship between drug administration and the decrease in WBC count, as well as between drug withdrawal and increase in WBC count, the episodes of leukopenia were drug related.

REFERENCES

- Greenwood, D. (1988). Microbiological properties of teicoplanin. *Journal of Antimicrobial Chemotherapy*, 21(suppl_A), 1-13.
- Favero, A. D., Patoia, L., Bucaneve, G., Biscarini, L., & Menichetti, F. (1989). Leukopenia with neutropenia associated with teicoplanin therapy. *DICP*, 23(1), 45-47.
- Patel, P., Sandoe, J., & Baig, W. (2012). Teicoplanin-induced leucopenia with immediate resolution after administration of G-CSF. *BMJ case reports*, 2012, bcr0120125668.