

## **Case Report**

### **Management of Internal Root Resorption – A Case Report**

Sangeeta Kulkarni<sup>1</sup>, Sangeetha Singh<sup>2</sup>

<sup>1</sup>Senior lecturer- Department of Conservative dentistry & endodontics

<sup>2</sup>Post graduate student - Department of Conservative dentistry & endodontics, Al-Badar dental college & hospital, Gulbarga, Karnataka

#### **\*Corresponding Author:**

Sangeeta Kulkarni

Email: [sangeeta\\_tisha09@yahoo.com](mailto:sangeeta_tisha09@yahoo.com)

---

**Abstract:** Management of a case of internal root resorption is a challenge to the endodontists. Internal resorption of teeth is an insidious process and is generally found in teeth with previous history of trauma. It may occur in cases with chronic pulpal inflammation, following caries or due to trauma in the form of an accidental blow. Internal resorption is very often noticed in anterior teeth, due to their susceptibility to trauma. However, it may be seen in posterior teeth, most likely because of carious involvement of the pulp. Early diagnosis, removal of the cause, proper treatment of the resorbed root is mandatory for successful treatment outcome. This case report describes the management of the resorptive defect in the apical 1/3rd which was treated nonsurgically with thermoplastized guttapercha technique. A six-month follow up demonstrated clinically asymptomatic and adequately functional tooth, with radiographic signs of healing.

**Keywords:** Internal resorption, pulpal inflammation, trauma, calcium hydroxide, thermoplastized guttapercha technique, fiber post, all ceramic crowns

---

#### **INTRODUCTION**

Resorption is defined as a condition associated with either a physiologic or a pathologic process resulting in loss of dentin, cementum or bone [1]. Andreasen has classified tooth resorption as Internal (Inflammatory, Replacement) and External (Surface, Inflammatory and Replacement). Internal resorption is an inflammation process initiated within the pulp space with the progressive destruction of intraradicular dentin and dentinal tubules along the middle and apical thirds of the canal walls as a result of clastic activities. External resorption is resorption initiated in the periodontium and initially affecting the external surfaces of a tooth. It may be further classified as surface, inflammatory, or replacement, or based on location as cervical, lateral, or apical. It may or may not invade the dental pulp space [2]. The etiology for resorption initiates from various injuries to the tooth, including thermal, mechanical, and chemical [3]. The pathology of internal root resorption (IRR) is caused by transformation of normal pulp tissue into granulomatous tissue with giant cells, which resorb dentin [4]. This, in turn, resorbs the dentinal walls, advancing from the center to the periphery. In the permanent dentition, it is a pathologic event of rare type. Although the exact cause is unknown, chronic pulpal inflammation from bacterial invasion, trauma, and orthodontic treatment have been suggested as a cause in most cases [5-7]. Resorption occurs in two stages: Degradation of the inorganic mineral structure followed by disintegration of the organic matrix [8].

Internal inflammatory resorption involves progressive loss of dentin, whereas root canal replacement resorption involves subsequent deposition of hard tissue that resembles bone or cementum but not dentin. Internal inflammatory resorption can be perforating or nonperforating root resorption [9]. Clinically, the condition is usually symptomatic; however, it may include the presence of a reddish area – pink spot, which represents the granulation tissue showing through the resorbed area. Radiographs are mandatory for diagnosing internal resorption, which reveals a round to oval radiolucent enlargement of the pulp space [9,10]. The margins are smooth and clearly defined with distortion of the original root canal outline. Internal resorption can be detected by: Visual examination based on changed color in tooth crown, radiographic diagnosis, conventional and cone beam computed tomography, light microscopy and electron microscopy [11]. Various materials available for the treatment of internal root resorption include MTA, glass ionomer cement, Super EBA, hydrophilic plastic polymer (2-hydroxyethylmethacrylate with barium salts), zinc oxide eugenol and zinc acetate cement, amalgam alloy, composite resin and thermoplastized gutta-percha administered either by injection or condensation techniques [12]. In modern dentistry, patients demand more than the restoration of function; and are particular about the esthetics as well, especially in relation to the anterior region [13,14]. The present case report shows the psychological, esthetic, functional and economic importance of maintaining the natural

tooth for a patient, in comparison with replacement with a prostheses or osseointegrated implants. This case report describes the successful management of non-perforating internal root resorption and successful healing after 8 months to 1 year of follow-up period.

### CASE REPORT

A 45 year-old female patient reported to department of conservative dentistry and endodontics, Al-badar dental college and hospital, Gulbarga, with a chief complaint of pain in upper left anterior region since a month. The patient's medical history was non-contributory. Clinical examination revealed the presence of deep caries involving pulp in relation to 21, 22 & 23. Radiographic examination showed radiolucency in middle third of root surface of the lateral incisor indicating a case of internal resorption with associated radiolucency in the periapical area of same tooth [Figure 1a, 1b]. Widening of periodontal ligament in relation to 23 was also evident. It was decided to complete the endodontic therapy for the tooth 21, 22, & 23 followed by post and core in relation to 21 and finally restoration with ceramic crowns

During the first visit after obtaining the patient's consent, anesthesia was delivered using 2% Lignocaine with 1: 80,000 adrenaline (Lignox, Indoco Remedies Ltd, India). Isolation was done using rubber dam (Hygienic Dental Dam, Coltene Whaledent, Germany). All caries were removed and access cavity was prepared in relation to 21, 22 and 23. Working length was determined using apex locator (Root ZX II; Morita, Tokyo, Japan) [Figure 2].

Cleaning and Shaping along with the copious irrigation with 2.5% sodium hypochlorite (septodont, India) was done. Alternatively ultrasonic irrigation was performed and an intracanal dressing of calcium hydroxide was given. Access cavity was sealed with temporary cement. During the second visit, master cone radiograph was taken [Figure 3] and the portion of the canal below the resorptive defect in relation to 22 was obturated with guttapercha (Dentsply, Maillefer) and AH Plus sealer (Dentsply, Maillefer, Konstanz, Germany) using sectional condensation technique and the remaining canal was obturated with thermoplastized guttapercha technique (Figure 4). Meanwhile the adjacent teeth, i.e 21 and 23 were also obturated with conventional obturation technique. A six month follow up showed that the tooth was clinically asymptomatic, with radiographic signs of healing.

Next Post space was prepared in relation to 22. An apical seal of 5mm of guttapercha was maintained. A suitable size fiber post (glass fibre post) (Figure 5) was selected due to its ability to maintain a monobloc effect. It was checked for fit in the canal. The post space were etched using 37 % phosphoric acid and bonding agent ( 3M ) followed by light curing for 10

seconds. Glass fibre post was luted in the post space using multi link automix resin cement and light cure for 20 seconds (Figure 6). This was followed by composite core build up in relation to 22. (Figure 7) Finally, prosthesis of all ceramic crowns was cemented in relation to 21, 22 & 23 (Figure 8). The patient was very satisfied with the final outcome.

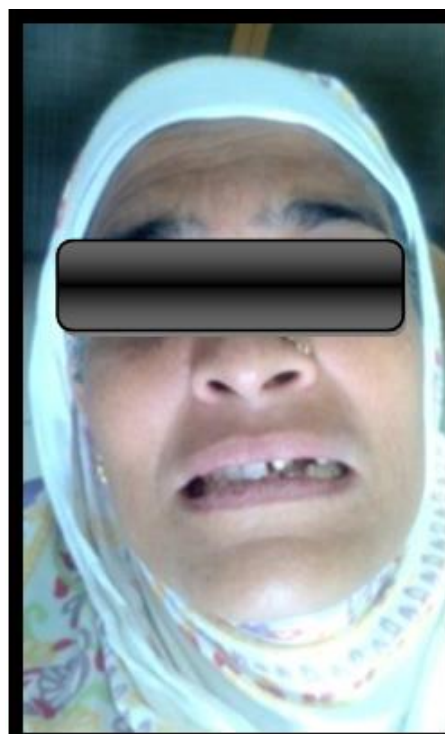

Fig-1a: Preoperative image of 21, 22, 23

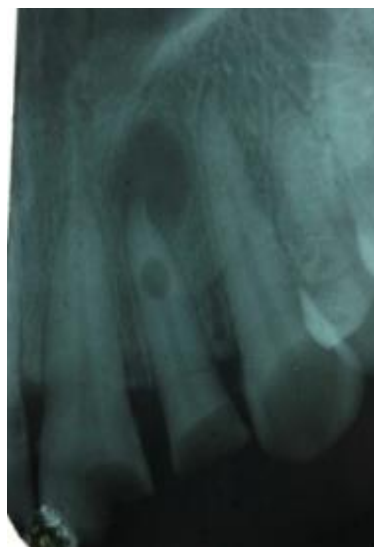
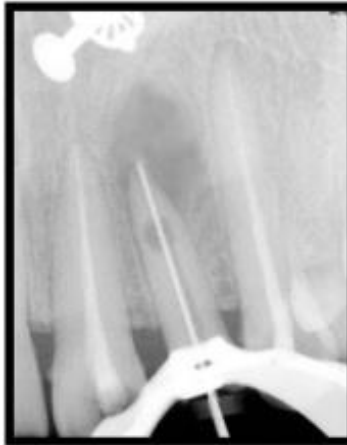
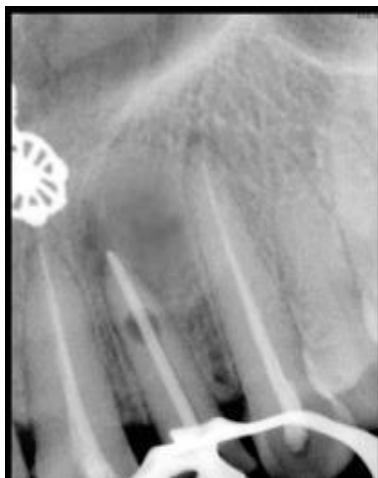

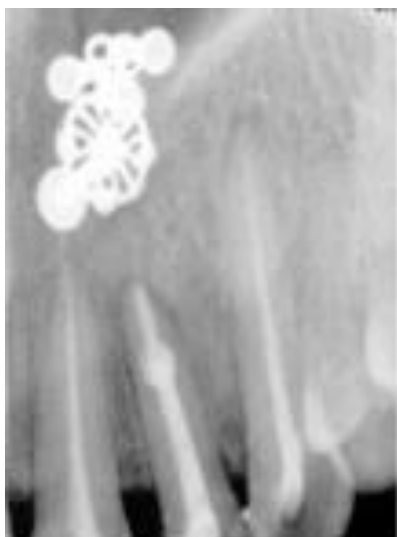Fig-1b: Preoperative IOPA x-ray of the patient



**Fig-2: IOPA showing working length determination**



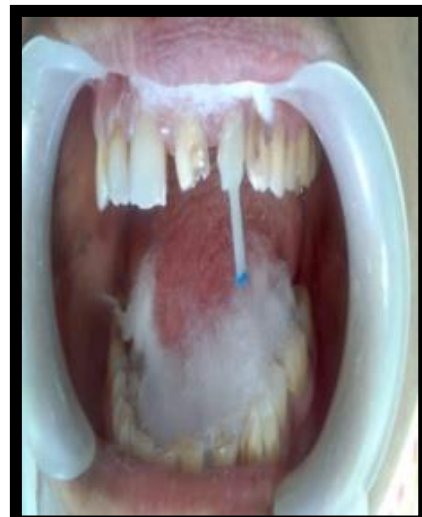**Fig-3: IOPA showing master cone determination**



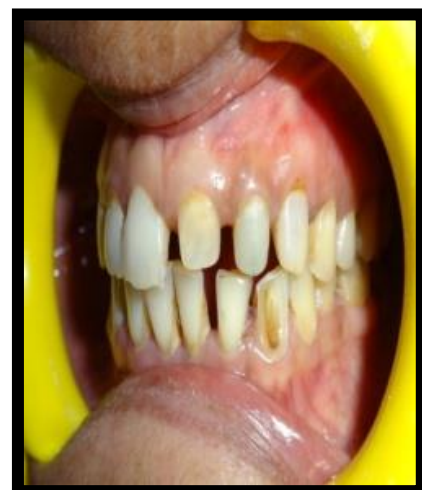**Fig-4: obturation with thermoplastized guttapercha technique**



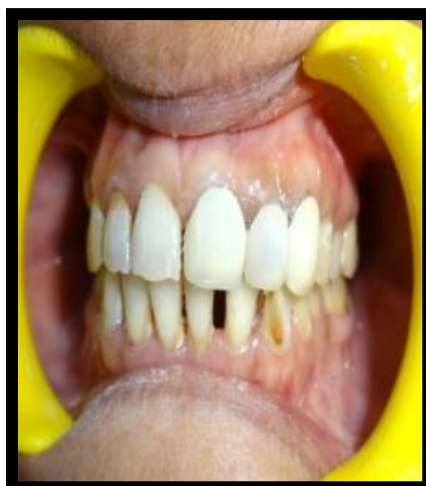**Fig-5: Glassix fibre post**



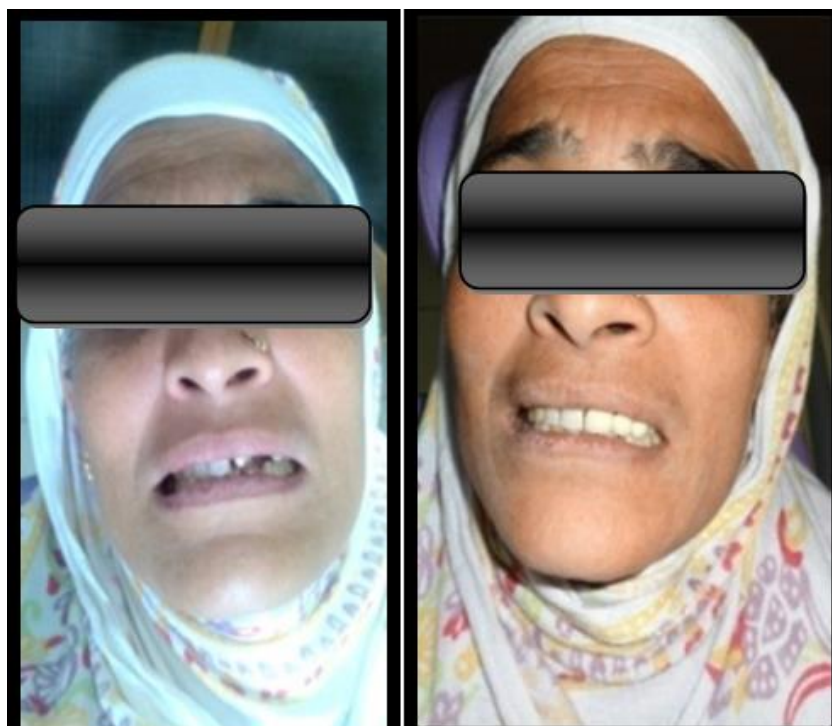**Fig-6: glassix fibre post luted in place**



**Fig-7: composite buildup of 22**



**Fig-8: ALL CERAMIC crowns in relation to 21, 22 & 23**



**Fig-9: Preoperative and postoperative view of the patient**

## DISCUSSION

Internal resorption is undoubtedly an endodontic challenge, especially, if the resorptive area is extensive and perforating. When diagnosed, immediate removal of the causative agent must be considered, aiming to arrest the cellular activity responsible for the resorptive activity [15]. However, the complex irregularities of the root canal system and the inaccessibility of internal resorption defect provide technical difficulties for thorough cleaning and obturation of the root canal. The persistence of organic debris and bacteria in these areas may jeopardize the longterm success of the endodontic treatment [16]. There is always a dilemma of whether to treat a tooth with a questionable prognosis endodontically or

extract it and subsequently place an implant. Bell first reported a case on internal resorption in 1830. Since then there have been numerous reports in the literature [17]. It is a multifactorial process associated with various factors, which may be categorized into physiological resorption, local factors, systemic condition and idiopathic resorption. A combined approach involving both hand instrumentation and antibacterial irrigation was performed on the involved tooth. Sodium hypochlorite is the most commonly used irrigant during root canal treatment due to its tissue dissolving and broad antimicrobial properties. Ultrasonic activation of irrigants should be viewed as an essential step in the disinfection of the internal resorption defect [12]. However, even with the use of

ultrasonic instruments, bacteria might still remain in confined areas [18]. Moreover only chemo mechanical debridement of the root canal space may fail to consistently render the root canal system bacteria-free. Hence an intracanal, antibacterial medicament should be used as part of disinfection process of the inaccessible areas of resorptive defects. Calcium hydroxide is antibacterial and has been shown to effectively eradicate bacteria that persist after chemo mechanical instrumentation [19]. Calcium hydroxide has also been shown to have a synergistic effect when used in conjunction with sodium hypochlorite to remove organic debris from the root canal [20]. In this case report, the extensive loss of tooth structure and the clastic non perforating internal root resorption was successfully managed by warm vertical condensation technique followed by thermoplasticized guttapercha technique. Lack of tooth structure necessitated to be supported with an anchorage system. Tooth-colored fiber posts have several advantages. Their main proposed advantage is monobloc effect, esthetics and flexibility as compared to metal posts and have approximately the same modulus of elasticity as dentin. When such posts were bonded in place with resin cement, researchers thought, forces would be distributed more evenly in the root, resulting in fewer root fractures [21]. In addition, the fiber-reinforced posts can be used with minimal preparation because resin cement uses the undercuts and surface irregularities to increase the surface area for bonding. Thus, it reduces the possibility of tooth fracture during function or traumatic injury. Management of the restoration for an endodontically treated tooth is critical. Furthermore, the longevity of an endodontic treatment is significantly increased by selecting an appropriate restoration that considers saving the tooth structure and preventing reinfection.

## CONCLUSION

Early diagnosis, removal of the cause, proper treatment of the resorbed root is mandatory for successful treatment outcome. Internal resorption is an uncommon resorption of the tooth, which starts from the root canal and destroys the surrounding tooth structure. It is easy to control the process of internal root resorption via severing the blood supply to the resorbing tissues with conventional root canal therapy. Regular recall is important to check the status of healing and for the overall prognosis of the tooth.

## REFERENCES

1. American Association of Endodontics, "Glossary of endodontic terms," 2014. [www.aae.org/glossary](http://www.aae.org/glossary)
2. Tronstad, L. (1988). Root resorption—etiology, terminology and clinical manifestations. *Dental Traumatology*, 4(6), 241-252.
3. Nilsson, E., Bonte, E., Bayet, F., & Lasfargues, J. J. (2013). Management of internal root resorption on

- permanent teeth. *International journal of dentistry*, 2013.
4. Maria R, Mantri V, Koolwal S. Internal resorption: A review and case report. [medind.nic.in/eaat/t10/i1/eaat10i1p98.pdf](http://medind.nic.in/eaat/t10/i1/eaat10i1p98.pdf)
5. Patel, S., Ricucci, D., Durak, C., & Tay, F. (2010). Internal root resorption: a review. *Journal of endodontics*, 36(7), 1107-1121.
6. Haapasalo, M., & Endal, U. (2006). Internal inflammatory root resorption: the unknown resorption of the tooth. *Endodontic topics*, 14(1), 60-79.
7. Fernandes, M., de Ataide, I., & Wagle, R. (2013). Tooth resorption part I-pathogenesis and case series of internal resorption. *Journal of Conservative Dentistry*, 16(1), 4.
8. Bhaskar SN. 10th ed. St. Louis: C. V. Mosby; 1986. Orban's oral histology and embryology; pp. 206-8.
9. Tronstad, L. (1988). Root resorption—etiology, terminology and clinical manifestations. *Dental Traumatology*, 4(6), 241-252.
10. Silveira, F. F., Nunes, E., Soares, J. A., Ferreira, C. L., & Rotstein, I. (2009). Double 'pink tooth' associated with extensive internal root resorption after orthodontic treatment: a case report. *Dental Traumatology*, 25(3), e43-e47.
11. Patel, S., Dawood, A., Wilson, R., Horner, K., & Mannocci, F. (2009). The detection and management of root resorption lesions using intraoral radiography and cone beam computed tomography—an in vivo investigation. *International endodontic journal*, 42(9), 831-838.
12. Estrela, C., Bueno, M. R., De Alencar, A. H. G., Mattar, R., Neto, J. V., Azevedo, B. C., & Estrela, C. R. D. A. (2009). Method to evaluate inflammatory root resorption by using cone beam computed tomography. *Journal of endodontics*, 35(11), 1491-1497.
13. Bakland, L., K. (1992) Root resorption. *Dent Clin North Am* 1992;36:491.
14. Levin, L., & Trope, M. (2002). Root resorption. *Seltzer and Bender's dental pulp*. Chicago, IL: Quintessence Publishing Co Inc, 425-48.
15. Trope, M. (2002). Root resorption due to dental trauma. *Endodontic topics*, 1(1), 79-100.
16. Goldberg, F., Massone, E. J., Esmoris, M., & Alfie, D. (2000). Comparison of different techniques for obturating experimental internal resorptive cavities. *Dental Traumatology*, 16(3), 116-121.
17. Bell, T. (1831). *The anatomy, physiology, and diseases of the teeth*. Carey & Lea.
18. Silveira, L. F. M., Silveira, C. F., Martos, J., Piovesan, E. M., & Neto, J. B. C. (2011). Clinical technique for invasive cervical root resorption. *Journal of Conservative Dentistry*, 14(4), 440.
19. Sjögren, U., Figdor, D., Spångberg, L., & Sundqvist, G. (1991). The antimicrobial effect of calcium hydroxide as a short-term intracanal

- dressing. *International endodontic journal*, 24(3), 119-125.
20. Türkün, M., & Cengiz, T. (1997). The effects of sodium hypochlorite and calcium hydroxide on tissue dissolution and root canal cleanliness. *International endodontic journal*, 30(5), 335-342.
21. Schwartz, R. S., & Robbins, J. W. (2004). Post placement and restoration of endodontically treated teeth: a literature review. *Journal of endodontics*, 30(5), 289-301.