

Case Report

Polycythemia Vera presenting with stroke and complicated by deep venous thrombosis – short case series

Radhakrishna H^{*1}, Bimal Prasad P², Sailesh BM³, Mitalee Kar R³, Vikram Kishore Reddy P³, Sivaramkrishna K³,
Sudhakar B⁴, Sandeep Ch⁴

¹Senior neurologist, ²Consultant neurologist, ³DNB residents, ⁴Neuro DMOs, Department of Neurology, Care Hospitals, Nampally, Hyderabad, Telangana, India

*Corresponding Author:

Dr Radhakrishna H

Email: dr.hariradhakrishna@gmail.com

Abstract: Polycythemia Vera a myeloproliferative disorder sometimes associated with vascular complications like stroke. The clinical course may be complicated by deep vein thrombosis at multiple sites if the underlying hematological disorder is not corrected. We present 3 cases of cerebrovascular disease complicated by polycythemia and the problems that came up during their management. All three cases could be managed successfully and are on follow up as outpatients.

Keywords: Polycythemia, JAK2 mutation, panmyelosis.

INTRODUCTION:

Polycythemia is a laboratory finding in which there is an increased number of red blood cells (RBC) in the peripheral blood. Polycythemia Vera (PV) is considered to be present when the hematocrit (Hct) is >48 or >52 percent in women and men respectively, or when the hemoglobin concentration (Hb) is >16.5 or >18.5 g/dl in women and men, respectively. PV is a myeloproliferative disorder resulting in an elevated absolute red blood cell mass because of uncontrolled red blood cell production. This is invariably associated with an increase in leucocyte and platelet production. PV is overall rare, occurring in 0.6-1.6 persons per million populations. The peak incidence of PV is between 50–70 years of age. In the following three case reports, we have discussed how management of polycythemia, stroke and venous thromboembolism are interlinked in presence of acute stroke. The red cell expansion in PV cases causes hyperviscosity and this plays a major role in the pathogenesis of both microcirculatory disturbances and arterial and venous thrombosis [1]. The possibility of an embolic mechanism is also considered in the pathogenesis of stroke in patients with PV by some authors [2].

Presentation of case 1:

Mr. L, a 55 years old nonsmoker male patient presented to a peripheral hospital on 15.09.2014 with acute onset of left hemiplegia of 6 hours duration. He was nondiabetic and was not a known hypertensive earlier. As he was becoming drowsy he was referred to our hospital, a tertiary care center, and within the next three hours was admitted and evaluated. His admission blood pressure was high 170/120 mmHg. He was drowsy with a Glasgow Coma score of E2V2M5. His cranial computerized tomographic (CT) scan showed intracerebral right basal ganglionic hemorrhage (ICH) with intraventricular extension, and additionally there was subarachnoid hemorrhage too (Fig 1). As the hemorrhage was associated was subarachnoid component also, a possibility of bleed secondary to arteriovenous malformation or dysplastic aneurysm was also considered but was excluded by a CT angiography at the same time as the initial scan. The further evaluation showed concurrent polycythemia with Hb of 22.7 Gm% and Hct of 69%. All other laboratory parameters were within normal limits.

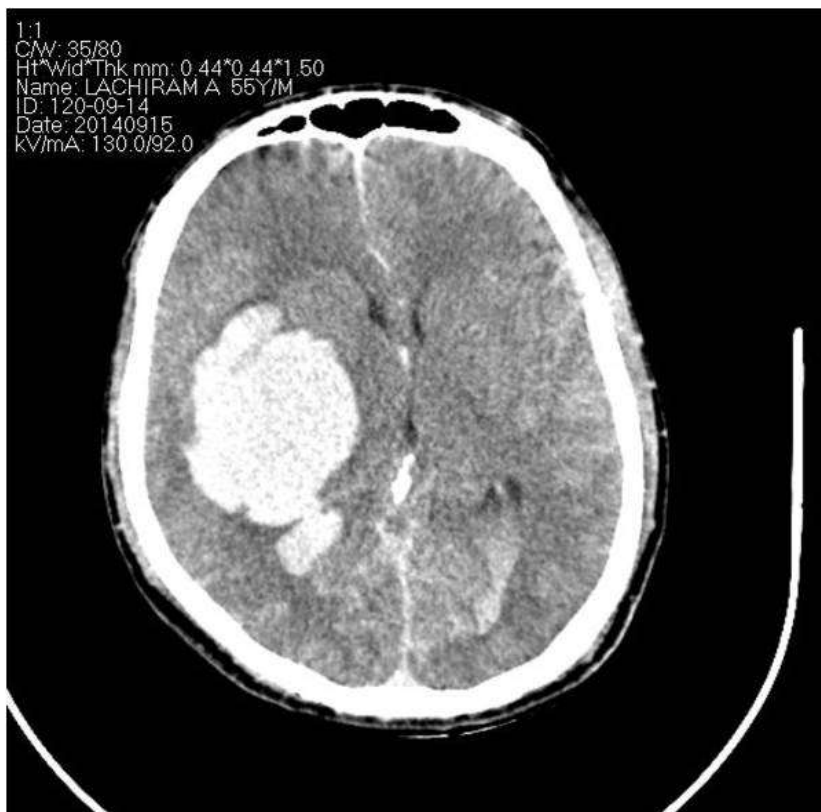


Fig 1: Intracerebral right basal ganglionic hemorrhage with midline shift and compressed ventricles

He was intubated and connected to mechanical ventilator as the oxygen saturations were decreasing. Within the next 12 hours he underwent emergency decompressive craniectomy and evacuation of hematoma. Osmotherapy, antibiotics and supportive care were continued for the next few days.

Considering the polycythemia, pending further evaluation, he was put on deep vein thrombosis (DVT) prophylaxis with compression stockings and intermittent

pneumatic compression device. During the initial two days heparin or low molecular weight heparin (LMWH) was withheld in view of large ICH, but later LMWH was introduced. He was further evaluated regarding the mechanism of polycythemia. He was a nonsmoker. His serum erythropoietin levels were 1.91 mIU/ml (normal 0.5-19 mIU/ml). JAK2V617F mutation was positive in the peripheral blood sample. The bone marrow biopsy examination was performed and was found to have hypercellularity with panmyelosis (Fig 2&3).

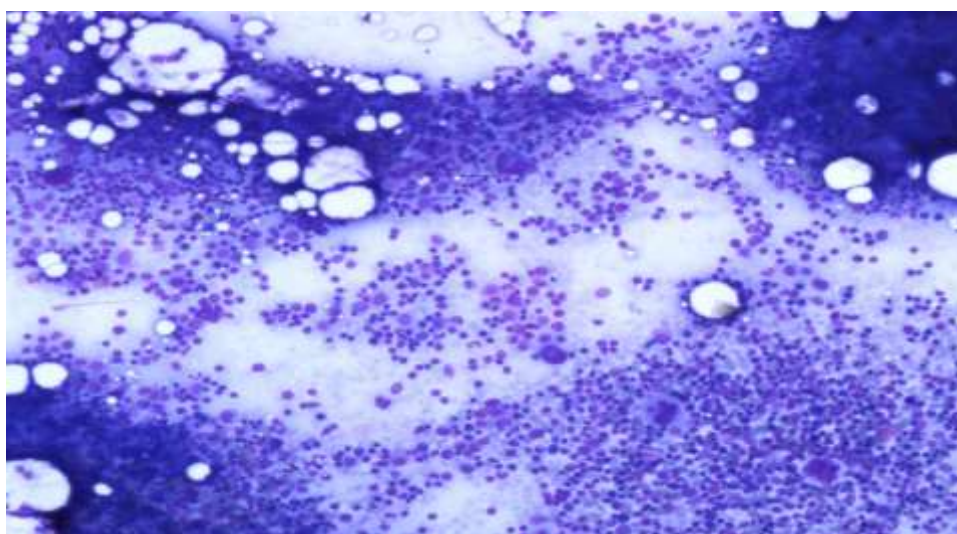


Fig 2: Bone marrow examination: Leishmann staining. X 10 magnification showing panmyelosis

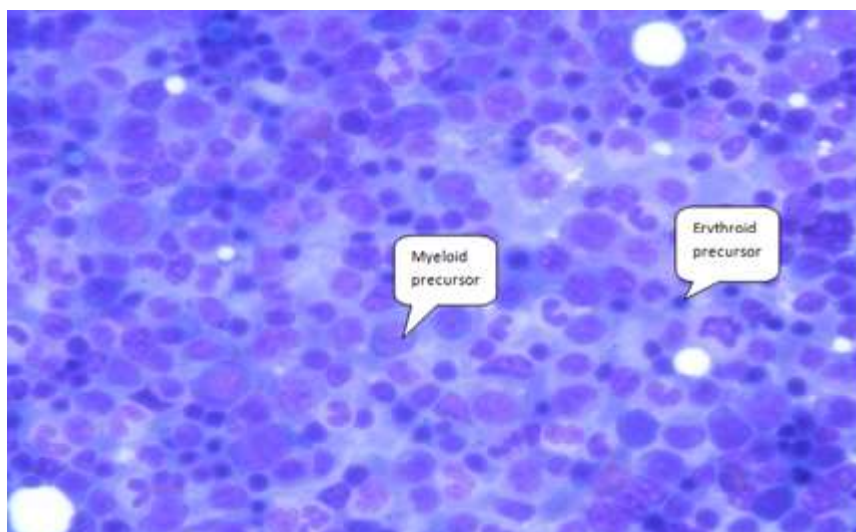


Fig 3: Bone marrow examination: Leishmann staining. X 40 magnification showing panmyelosis

He was diagnosed as a case of PV and phlebotomy was performed to let out 300 ml of blood. He was started on Cap. Hydroxyurea 500mg twice daily.

Subsequently (nearly after 1 week of admission), he developed left lower limb and left upper limb DVT as confirmed by venous Doppler examination and was managed with LMWH. After the next 5 days, he was found to have developed DVT in right lower limb also. Right upper limb was spared. He was continued on LMWH which was subsequently overlapped and replaced with oral anticoagulant, 2mg per day of

acenocoumarol. He was also started on oral anticoagulant prescribed diet – avoidance of greens and legumes. Also, he was started on low dose aspirin (75mg per day) for vascular prophylaxis. Repeat imaging was suggestive of no recurrence or expansion of bleed.

Regular follow up (Table I) in the outpatient department up to six months showed that the DVT had resolved totally with no recurrence. The patient has residual left hemiplegia of MRC grade 0/5 and normal right sided limbs and speech. There was no recurrence of DVT.

Table I

| | 15.09.2014 | 23.09.2014 | 17.10.2014 | 20.10.2014 | 27.10.2015 |
|-----------------|------------|------------|------------|------------|------------|
| Hemoglobin Gm% | 22.7 | 18.2 | 12.0 | 12.8 | 13.6 |
| Hematocrit Vol% | 69 | 57 | 37 | 39 | 40 |

Presentation of case 2:

A 42yrs old male Mr. NR was admitted on 06.04.2015 with a history of slurring of speech, deviation of angle of mouth to right side and weakness of left upper and lower limbs of 45 minutes duration, at the time of admission. His MRI brain scan was suggestive of acute left middle cerebral artery territory infarct as shown in diffusion weighted imaging (Fig 4).

As the patient presented within window period after the onset of stroke, he was thrombolysed with 60

mg of tissue plasminogen activator (rtPA) according the protocol after excluding the contraindications. Twenty four hours later he was started on antiplatelet drugs and statins. In due course of hospitalization, on day 3, his left lower limb power deteriorated to grade 1/5 (MRC grading). Repeat MRI brain showed increase in the size of infarct. Haemodynamic augmentation was done with saline and noradrenaline infusion in low concentration for the next three days. The limb power improved gradually over the next one week.

mg of tissue plasminogen activator (rtPA) according the protocol after excluding the contraindications. Twenty four hours later he was started on antiplatelet drugs and statins. In due course of hospitalization, on day 3, his left lower limb power deteriorated to grade 1/5 (MRC grading). Repeat MRI brain showed increase in the size of infarct. Haemodynamic augmentation was done with saline and noradrenaline infusion in low concentration for the next three days. The limb power improved gradually over the next one week.

phlebotomy hydroxyurea was started pending further work up.

His serum erythropoietin level was 5.5 mIU/ml. Patient was advised to undergo further evaluation for confirming PV (Bone marrow examination and JAK2 mutation testing). But due to financial constraints the

relatives could not get the tests done during his hospital stay. He was empirically continued on Hydroxyurea 500 mg/ twice daily. He was advised to get the remaining

work up done in follow-up visits. The patient was discharged 11 days after admission.

Table II

| | 06.03.2015 | 10.04.2015 | 15.04.2015 |
|--------------------|------------|------------|------------|
| Hemoglobin (Gm %) | 19.0 | 18.4 | 16.6 |
| Hematocrit (Vol %) | 55.3 | 53 | 49 |

Presentation of case 3:

A 53 years old male Mr. S was admitted on 27.10.2014 with a history of focal seizures involving left upper and lower limb followed by post ocular paralysis which improved partially after 5 minutes. He was a known case of stroke earlier – left hemiparesis secondary to right thalamic infarct in 2011. He was a hypertensive. There was also history of ischemic heart

disease and he underwent percutaneous transluminal coronary angioplasty 7 years ago. Patient was given a loading dose of anti-epileptic medication levetiracetam and was maintained with 1000 mg twice daily. MRI brain scan was suggestive of multiple right fronto-parietal acute infarcts on diffusion weighted imaging (Fig 4).

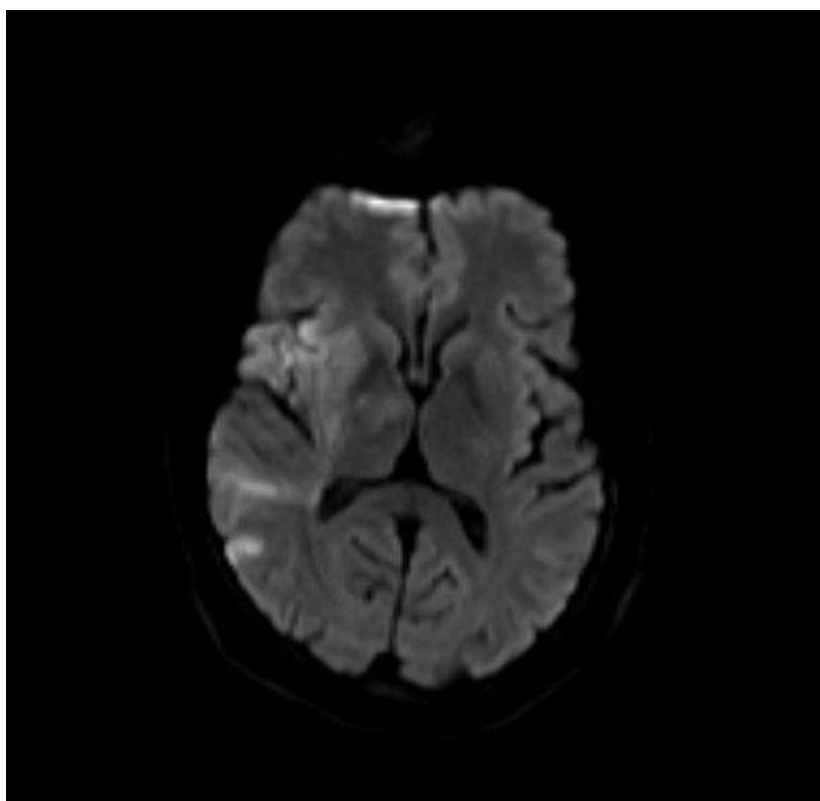


Fig 4: Right fronto-parietal acute infarct on diffusion weighted MRI imaging.

Since the patient had recurrent stroke and with the history of coronary artery disease, he was started on dual antiplatelets - aspirin 150 & clopidogrel 75 and high dose of atorvastatin. Psychiatry consultation was taken for nicotine/ alcohol dependence and started on antipsychotics and naltrexone. His Haemogram was suggestive of raised Hct and Hb% values. JAK-2 mutation was positive and bone marrow was suggestive of hyper cellularity with panmyelosis). Phlebotomy done

once in the hospital stay and 300 ml of blood was let out. He was started on Cap. Hydroxyurea 500mg twice daily. Patient did not have any further episodes of seizures during hospital stay and started with limb physiotherapy. He was discharged in a stable condition with modified Rankin Scale of I (ambulant without assistance for daily activities). The Hct values during his hospital stay were as in Table III.

Table III

| | 27.10.2014 | 30.10.2014 | 03.11.2014 |
|--|------------|------------|------------|
| Hemoglobin (Gm %) | 19.5 | 19.4 | 17.9 |
| Hct (Vol %) | 60 | 60 | 55 |
| ESR (mm/Hr) | 01 | | |
| Total Leucocyte count (per mm ³) | 23,300 | 20,700 | 22,400 |

DISCUSSION:

Polycythemia may present as thrombotic or hemorrhagic complications. Hemorrhagic diathesis is rarer, less ominous and mostly affects patients with a very high platelet count. The bleeding tendency can be reduced effectively by cytoreduction [3]. The use of antithrombotic therapies to prevent thromboembolism in patients with an acute or prior intracerebral hemorrhage (ICH) presents a clinical dilemma with competing risks and benefits. In many cases, clinical decisions must be made on the basis of indirect and observational evidence rather than high quality clinical trials.

Management of patients varies from case to case and needs to be modified according to clinical situation. The goals of treatment are to minimize the clinical, physical, laboratory features of increased red cell mass and to avoid the long-term complications of the disease (thrombotic events, bleeding, myelofibrosis, acute leukemia and other malignancies).

Prevention of stroke recurrence is also of utmost importance. Prior thrombosis is a well-established risk factor for re-thrombosis in polycythemia Vera. Cytoreduction protects against recurrent thrombosis [4].

Close to 50% of PV patients have secondary hypertension. The hypertension is caused by increased Hct and resultant increased viscosity leading to increase in intra-arterial pressure.

The goal of phlebotomy is to bring Hct to less than 45% in male and less than 42% in female patients. Initially the patients may require 1-2 phlebotomies per week to achieve this target and later once in 3-6 months. Repeated and more frequent phlebotomies result in iron deficiency that can cause other symptoms. This may also reduce further erythropoiesis [5].

Cytoreductive agents useful in such situations are hydroxyurea, interferon alfa, anagrelide and pipobroman. Frequent monitoring of blood counts is necessary while the patient is on such medication. Hydroxyurea may produce allergic reactions and the patients are also prone for opportunistic infections. Anagrelide is a phospholipase A2 inhibitor, mainly reduces platelets though is can also be used in polycythemia Vera. It can prolong Q-T interval, produce hepatotoxicity and is teratogenic. Pipobroman is a neutral amide of piperazine, effectively reduces red cell

mass and platelet counts and is useful in polycythemia and/or essential thrombocytosis both of which share a common genetic mutation (Janus kinase or JAK 2 mutation)[6]. It is an excellent alternative to hydroxyurea in patients with PV at high risk of arterial thrombosis. Interferon alfa is an injectable biologic response modifier (immunotherapy) useful in many hematologic malignancies including PV.

Splenectomy is hardly ever performed in PV patients except in a selected few who either do not tolerate cytoreductive agents or are refractory to them.

Low dose aspirin has been proved in ECLAP (Efficacy of low dose aspirin in polycythemia) study to be effective in vascular protection [1, 3].

There is much expectation on *JAK2* inhibition as a rational approach for targeting the important mechanism leading to uncontrolled cell growth and possibly involved in the pathogenesis of the hemostatic imbalance. Some pharmaceutical companies have developed small molecule inhibitors which may soon enter phase 2 studies. Whether these agents can control the cell proliferation without producing serious side effects in humans is a question yet to be answered.

CONCLUSION:

Polycythemia Vera is a myeloproliferative disorder which can give rise to a variety of complications including ischemic and/or hemorrhagic strokes. Acute care is similar to other stroke cases. The clinical picture can be complicated by DVT and sometimes pulmonary embolism. The prevention includes cytoreductive therapy with a safe agent form a choice of molecules and phlebotomy for immediate needs. Low dose aspirin is also used as a part of vascular protection.

Conflicts of interest:

There are no conflicts of interest to be declared.

REFERENCES:

1. Landolfi, R., Di Gennaro, L., Barbui, T., De Stefano, V., Finazzi, G., Marfisi, R., Tognoni, G. & Marchioli, R. (2007). Leukocytosis as a major thrombotic risk factor in patients with polycythemia vera. *Blood*, 109(6), 2446-2452.
2. Zoraster, R. M., & Rison, R. A. (2013). Acute embolic cerebral ischemia as an initial presentation

- of polycythemia vera: a case report. *Journal of medical case reports*, 7(1), 131.
3. Landolfi, R., Cipriani, M. C., & Novarese, L. (2006). Thrombosis and bleeding in polycythemia vera and essential thrombocythemia: pathogenetic mechanisms and prevention. *Best Practice & Research Clinical Haematology*, 19(3), 617-633.
 4. De Stefano, V., Za, T., Rossi, E., Vannucchi, A. M., Ruggeri, M., Elli, E., ... & Gerli, G. (2008). Recurrent thrombosis in patients with polycythemia vera and essential thrombocythemia: incidence, risk factors, and effect of treatments. *Haematologica*, 93(3), 372-380.
 5. Spivak, J. L. (2002). Polycythemia vera: myths, mechanisms, and management. *Blood*, 100(13), 4272-4290.
 6. Landolfi, R., & Di Gennaro, L. (2008). Prevention of thrombosis in polycythemia vera and essential thrombocythemia. *Haematologica*, 93(3), 331-335.