

## Case Report

### Apert syndrome with cryptorchidism and recurrent hemoptysis

Chatterjee Nandini<sup>1</sup>, Brahmachari Ramkrishna<sup>2</sup>, Dey Soumitra<sup>3</sup>, Chatterjee Chandan<sup>4</sup>

<sup>1</sup>Associate Professor, Associate Professor, General Medicine, Murshidabad Medical College, Berhampore, West Bengal, India

<sup>2</sup>Post graduate Trainee, <sup>3</sup>RMO cum Clinical Tutor, Department of General Medicine, NRS Medical College, AJC Bose Road, Kolkata-700014, India

<sup>4</sup>Associate Professor, Pharmacology, ESI-PGIMS, ESIC Medical College, Joka, Kolkata, West Bengal, India

#### \*Corresponding Author:

Nandini Chatterjee

Email: [soriasis\\_2009@yahoo.in](mailto:soriasis_2009@yahoo.in)

**Abstract:** We present the case of 30 year old male patient of Apert Syndrome with cryptorchidism and recurrent life threatening hemoptysis. Subsequent investigations revealed bronchiectasis. We would like to highlight the fact that complications secondary to congenital anomalies, if not addressed early, lead to medical, financial and social burdens that are otherwise avoidable.

**Keywords:** cryptorchidism, anomalies, bronchiectasis.

## INTRODUCTION

Craniosynostoses are a spectrum of uncommon disorders characterized by abnormal union of cranial sutures accompanied by a host of clinical presentations. Apert syndrome being the commonest among them has been much documented in scientific literature [1]. However, our patient, apart from being visually disturbing had another compelling reason for recurrent admissions. He was suffering from repeated hemoptysis for the last 4 years for which we evaluated him further.

## CASE REPORT

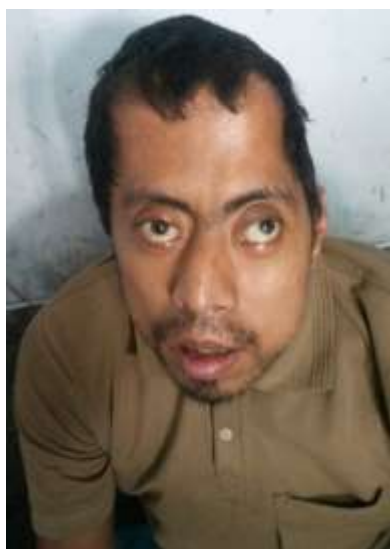Our patient was a 30 year old male who presented with cough and hemoptysis for two days. It was moderate in quantity and not associated with fever, chest pain or any dyspnoea. There had been similar episodes in the past which were treated in the local hospital. There was no history of tuberculosis in the past.

He was the youngest of four siblings. As stated by his mother, he was delivered normally but had delayed milestones. His other siblings were normal. O/E The patient had a deformed skull with prominent forehead, shallow orbits with strabismus in the left eye, hypoplastic maxilla and prognathism. (Fig 1, 2). There was proptosis, high arched palate and unerupted premolar and molars bilaterally. He had kyphosis, elbow contractures and genu valgum. Both hands and feet showed syndactily of fingers and toes. The thumbs and index fingers of both hands were fused while the great toes were fused with the 2<sup>nd</sup> and 3<sup>rd</sup> toes bilaterally (Fig 3). There was mild pallor, normal vitals, no cyanosis, clubbing, lymphadenopathy or icterus. On examination of the respiratory system, chest was deformed with a

depressed sternum and kyphosis. There was no mediastinal shift. Chest was resonant all through. On auscultation there were bilateral vesicular breath sounds with some coarse crepitations and increased vocal resonance in the right upper chest. GI system examination was normal except the genitalia. The testes could not be palpated in the scrotal sac, which was hypoplastic. one testes could be palpated in the right inguinal anal. Secondary sexual characteristics were normal. Nervous system examination revealed impaired immediate and recent memory, slurred speech. He was alert and oriented, however, being uneducated, calculations could not be tested. The Binet Kamat test for intelligence performed in the Institute of Psychology, Calcutta University revealed an IQ Score of 30, mental age being 4 years. The social age was 6 years by the Vineland Social Maturity Scale. Other components of nervous system including ophthalmoscopy were normal. CVS examination was noncontributory. He had normal visual acuity and hearing.

Investigations revealed a microcytic hypochromic anemia. Blood biochemistry was essentially normal. Chest X ray upper zone patchy on the right. Sputum for AFB was negative. CECT Thorax demonstrated right upper lobe bronchiectatic changes along with consolidation (Fig4). USG Abdomen with Doppler showed aberrant intra abdominal testes in the right lumbar region (Fig 5). Echocardiography was normal. X ray of the hands and feet showed soft tissue fusion of the digits without bony unions. MRI brain showed asymmetry of cerebral hemispheres, MRI Spine was essentially normal except kyphosis.

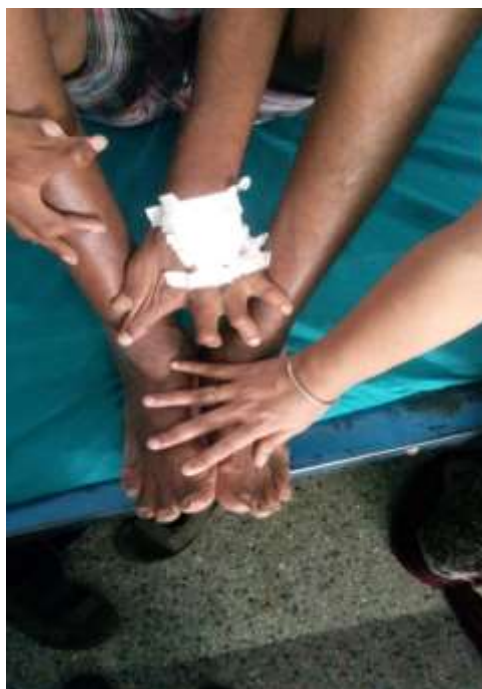The patient was put on antibiotics and recovered considerably. He has been referred to cardiothoracic surgery for consideration of pulmonary lobectomy. The principal varieties of Craniosynostoses that we come across are Apert, Crouzen, Pfeiffer, Carpenter and Saethre Chotzen syndromes. Each has its own characteristic clinical landmarks by which they may be recognized apart from their specific genetic alterations. Of these Apert Syndrome is characterized by mental retardation, syndactily in both hands and feet along with malformations of skull and face Apert syndrome is a variant of acrocephalo syndactily, affecting the first branchial arch. It is an autosomal dominant disorder. Almost all cases are sporadic, signifying fresh mutations or environmental insult to the genome. There is specific missense mutation in the FGFR2 gene, with an advantage in the male germ line [2].



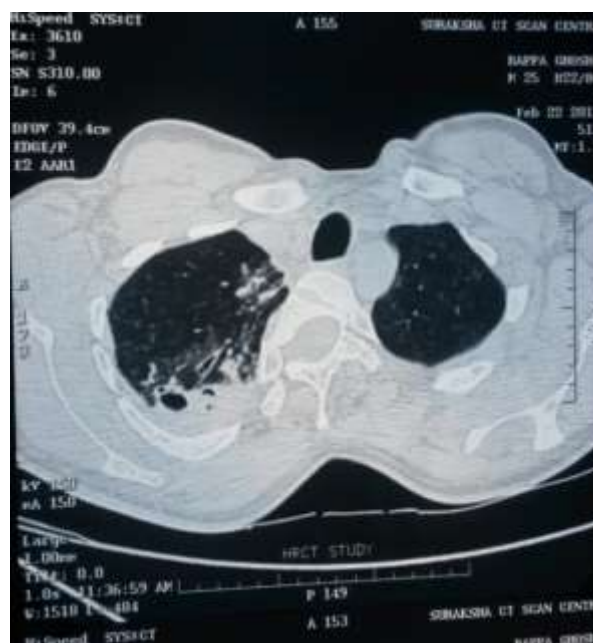**Fig 1: Frontal view of face showing prominent forehead, left sided squint, proptosis.**



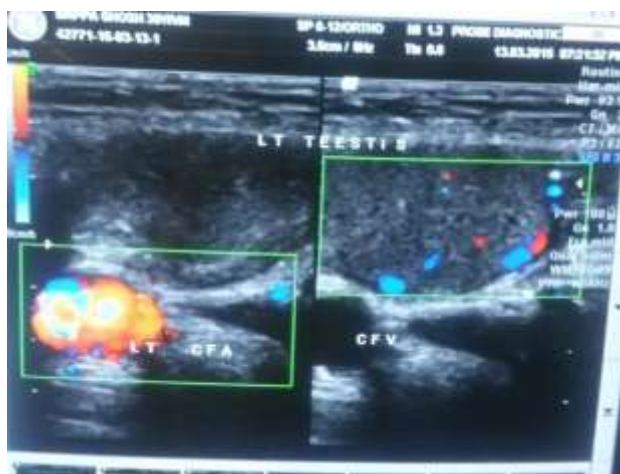
**Fig 2: Profile showing depressed nasal bridge, prognathism, low hairline**



**Fig 3: Hands and feet showing syndactily and camptodactily**



**Fig 4: CECT Thorax showing bronchiectetic changes and consolidation in right upper lobe**



**Fig 5: Ultrasound abdomen with colour Doppler showing intra abdominal left testes**

The incidence of Apert syndrome as quoted has varied from 1 in 160,000 to 1 in 65000 live births in different studies [1]. Indian statistics is not, however, available. Male s and females are affected equally. Moreover, the incidence rises sharply with the age of the father.

Apart from the skeletal defects many anomalies of various organ systems have been described. The prevalence of anomalies of the respiratory system documented in literature is 1.5% - much lesser than cardiovascular or genitourinary anomalies found in 10% and 9.6%, respectively. Pulmonary aplasia, absence of middle lobe, tracheoesophageal fistula has been described [3]. A study in Saudi Arabia documented a 1.6% incidence of bronchiectasis in association with patients with Craniosynostoses [4]. The explanations for predisposition to bronchiectetic changes put forward were a) recurrent sinusitis 68% b) GERD 32% c) seizures d) in coordination in the swallowing reflex [5]. Our patient did not have seizures but his mother did mention recurrent respiratory tract infections and headaches since childhood. Craniofacial malformations including high arched palate predispose to sinusitis while kyphosis may account for GERD and micro aspirations.

Cryptorchidism has been documented in 4.5% of Apert syndrome cases. The importance of timely intervention in such cases cannot be overemphasized as it subsequently leads to infertility and even malignancy [6].

Our patient is an example of total neglect and indifference of his family and community. He is illiterate, unemployed and unmarried. In the times when prenatal sonological diagnosis of this condition is a reality, early intervention could have improved his medical condition and enriched his quality of life [7].

## REFERENCES

1. Cohen, M. M., Kreiborg, S., Lammer, E. J., Cordero, J. F., Mastroiacovo, P., Erickson, J. D., ...

- & Martínez-Frías, M. L. (1992). Birth prevalence study of the Apert syndrome. *American journal of medical genetics*, 42(5), 655-659.
2. Moloney, D. M., Slaney, S. R., Oldridge, M., Wall, S. A., Sahlin, P., Stenman, G., & Wilkie, A. O. (1996). Exclusive paternal origin of new mutations in Apert syndrome. *Nature genetics*, 13(1), 48-53.
3. Cohen, M. M., & Kreiborg, S. (1993). Visceral anomalies in the Apert syndrome. *American journal of medical genetics*, 45(6), 758-760.
4. Banjar, H. H. (2007). Clinical profile of Saudi children with bronchiectasis. *The Indian Journal of Pediatrics*, 74(2), 149-152.
5. Banjar, H. H. (2007). A review of 151 cases of pediatric noncystic fibrosis bronchiectasis in a tertiary care center. *Annals of thoracic medicine*, 2(1), 3-8.
6. La Vignera, S., Calogero, A. E., Condorelli, R., Marziani, A., Cannizzaro, M. A., Lanzafame, F., & Vicari, E. (2009). Cryptorchidism and its long-term complications. *Eur Rev Med Pharmacol Sci*, 13(5), 351-6.
7. Maria, R. L., Robert, S., Andrzej, Z., & Malgorzata, S. M. (2010). Progressive development of sonographic features in prenatal diagnosis of Apert syndrome—case report and literature review. *Ginekol Pol*, 81, 935-939.