

## Outcomes of Tibial Plateau Fractures Managed by Ilizarov External Fixation

Dr. Nazmul Huda Shetu<sup>1\*</sup>, Dr. B. M. Rahgir Mahmud<sup>2</sup>, Dr. Md. Maruf Al Hasan<sup>3</sup>, Dr. Md. Syedur Rahaman<sup>4</sup>,  
Dr. Ohidul Islam<sup>5</sup>, Dr. Razib Ahmed<sup>6</sup>, Dr. Nitya Ranjan Balo<sup>7</sup>, Dr. Md. Emdadul Haque<sup>8</sup>

<sup>1</sup>Assistant Professor, Ilizarov & Defomity Correction Unit, National Institute of Traumatology and Orthopaedic Rehabilitation (NITOR), Sher-E-Bangla Nagar, Dhaka, Bangladesh

<sup>2</sup>Junior Consultant, Department of Orthopaedic Surgery, Upazila Health Complex, Kumarkhali, Kushtia

<sup>3</sup>Medical Officer, Department of Orthopaedic Surgery, National Institute of Traumatology and Orthopaedic Rehabilitation (NITOR), Sher-E-Bangla Nagar, Dhaka, Bangladesh

<sup>4</sup>Registrar, Department of Orthopaedic Surgery, National Institute of Traumatology and Orthopaedic Rehabilitation (NITOR), Sher-E-Bangla Nagar, Dhaka, Bangladesh

<sup>5</sup>Junior Consultant, Department of ILIZAROV and Orthopaedic Surgery, National Institute of Traumatology and Orthopaedic Rehabilitation (NITOR), Sher-E-Bangla Nagar, Dhaka, Bangladesh

<sup>6</sup>Junior Consultant, Ilizarov & Defomity Correction Unit, National Institute of Traumatology and Orthopaedic Rehabilitation (NITOR), Sher-E-Bangla Nagar, Dhaka, Bangladesh

<sup>7</sup>Indoor Medical Officer, Department of Orthopaedic Surgery, Kurmitola General Hospital, Dhaka, Bangladesh

<sup>8</sup>Assistant Professor, Department of Orthopaedic Surgery, National Institute of Traumatology and Orthopaedic Rehabilitation (NITOR), Sher-E-Bangla Nagar, Dhaka, Bangladesh

DOI: <https://doi.org/10.36348/sjimps.2026.v12i06.001>

Received: 06.04.2026 | Accepted: 23.05.2026 | Published: 04.06.2026

\*Corresponding author: Dr. Nazmul Huda Shetu

Assistant Professor, Ilizarov & Defomity Correction Unit, National Institute of Traumatology and Orthopaedic Rehabilitation (NITOR), Sher-E-Bangla Nagar, Dhaka, Bangladesh

### Abstract

**Background:** Complex tibial plateau fractures are severe intra-articular injuries characterized by articular comminution, metaphyseal instability and soft tissue compromise, making surgical management challenging. Ilizarov technique offers stable fixation while preserving fracture biology and minimizing soft tissue trauma. This study aimed to evaluate the radiological and functional outcomes of Schatzker type V and VI tibial plateau fractures managed with Ilizarov external fixation. **Methods:** This prospective observational study was conducted at the National Institute of Traumatology & Orthopaedic Rehabilitation (NITOR) and in a private hospital in Dhaka, Bangladesh, from January 2018 to December 2024. Thirty adult patients with Schatzker type V or VI tibial plateau fractures treated with Ilizarov external fixation were enrolled. Data on demographics, operative parameters, time to union, radiological alignment, functional outcomes and complications were collected prospectively. Functional evaluation was performed using the knee range of motion and the Knee Society Score at 12 months postoperatively. **Results:** Thirty patients with complex tibial plateau fractures were included in this study. The majority of patients were aged 30–49 years (56.6%) and males predominated (73.3%). Motor bike accident was the most common mechanism of injury (83.3%). All patients underwent Ilizarov external fixation, with 33.3% requiring additional minimal internal fixation. The mean time to fracture union was  $16.8 \pm 3.5$  weeks. Joint stiffness occurred in 10% of patients. Satisfactory radiological alignment was achieved in 90% of patients. The mean knee range of motion was  $115.3 \pm 14.7^\circ$  and the mean Knee Society Score was  $84.7 \pm 10.2$ . Superficial pin tract infection occurred in 20% of cases, deep infection in 3.3% and loss of reduction in 3.3%. **Conclusion:** Ilizarov external fixation is an effective and safe option for complex tibial plateau fractures, providing reliable union, good functional outcomes and minimal serious complications.

**Keywords:** Tibial plateau fracture, Ilizarov fixator, Schatzker V–VI, External fixation.

Copyright © 2026 The Author(s): This is an open-access article distributed under the terms of the Creative Commons Attribution 4.0 International License (CC BY-NC 4.0) which permits unrestricted use, distribution, and reproduction in any medium for non-commercial use provided the original author and source are credited.

## INTRODUCTION

Tibial plateau fractures are complex intra-articular injuries that pose substantial challenges to knee stability, alignment and long-term functional outcomes, particularly when sustained through high-energy trauma. These fractures represent approximately 1% of all fractures and frequently result from motor bike accidents or falls from height, often accompanied by extensive metaphyseal comminution and soft-tissue compromise [1]. Among these injuries, Schatzker type V and VI fractures are especially demanding due to bicondylar involvement, axial instability and metaphyseal–diaphyseal dissociation, all of which complicate surgical reconstruction and postoperative rehabilitation [2].

The fundamental objectives in managing complex tibial plateau fractures include accurately restoring articular congruity, preserving limb alignment, achieving stable fixation and facilitating early knee mobilization. Open reduction and internal fixation (ORIF) have traditionally been regarded as the standard method for achieving anatomical reduction. However, several studies have reported high rates of wound complications, deep infection and soft-tissue breakdown following ORIF, particularly in high-energy bicondylar fractures with compromised soft tissues [3,4]. In this study, both open and closed fractures were included, though open fractures were managed with initial debridement prior to Ilizarov application. Gaundur *et al.*, highlighted that elderly and high-risk patient undergoing ORIF experienced a notable incidence of wound-related complications, adversely affecting functional recovery [5].

Given these concerns, alternative fixation strategies have been explored to reduce soft-tissue morbidity while maintaining fracture stability. Ilizarov circular external fixation has gained increasing attention as a biologically favorable option, particularly for complex proximal tibial fractures. The tensioned wire construct allows for stable fixation through ligamentotaxis, enabling indirect reduction of articular fragments while minimizing additional surgical trauma to already compromised soft tissues [6]. Moreover, the modular nature of the Ilizarov frame permits gradual postoperative adjustment and early controlled weight-bearing.

Clinical evidence supporting the use of Ilizarov fixation in complex tibial plateau fractures has been encouraging. Hassan reported satisfactory functional outcomes and acceptable complication rates using the Ilizarov technique in proximal tibial fractures, emphasizing the importance of early mobilization and joint preservation [7]. Similarly, Ghimire *et al.* demonstrated reliable fracture union and maintenance of alignment in patients treated with Ilizarov ring external fixation for complex tibial plateau fractures [1].

Comparative studies and systematic reviews further support the role of circular external fixation. Zhao *et al.*, in a meta-analysis comparing external fixation with ORIF, reported lower deep infection rates and comparable functional outcomes in patients managed with external fixation for complex tibial plateau fractures [8]. Li *et al.*, echoed these findings, noting that circular external fixation offered equivalent radiological outcomes with reduced soft-tissue complications when compared to internal fixation techniques [9]. Subramanyam *et al.*, also highlighted that Ilizarov fixation, with or without minimal internal fixation, achieved satisfactory alignment and functional results in Schatzker type V and VI fractures [10].

Despite these favorable reports, variations remain in union times, rehabilitation protocols and complication profiles across different populations. Data from South Asian trauma centers remain relatively sparse, particularly from high-volume referral institutions where delayed presentation and severe injury patterns are common. Debnath *et al.*, emphasized the need for regional outcome data after demonstrating reliable union and early weight-bearing in high-energy Schatzker type VI fractures treated with ring fixators [11]. Tahir *et al.*, further underscored the importance of contextual evidence when comparing Ilizarov fixation with ORIF in similar fracture patterns [12].

Therefore, the present study aimed to evaluate the radiological and functional outcomes of Schatzker type V and VI tibial plateau fractures managed with Ilizarov external fixation at a tertiary referral center in Bangladesh, thereby contributing region-specific evidence to guide clinical decision-making in complex proximal tibial injuries.

## MATERIALS & METHODS

This prospective observational study was conducted at the Department of Reconstructive & Deformity Correction Surgery, National Institute of Traumatology & Orthopaedic Rehabilitation (NITOR), Dhaka, Bangladesh and a private hospital in Dhaka, Bangladesh. The study was conducted over a period of seven years from January 2018 to December 2024. The study population included consecutive adult patients presenting with complex tibial plateau fractures who were managed using Ilizarov external fixation and who met the predefined eligibility criteria. A total of 30 patients were enrolled and followed up prospectively.

### Selection Criteria

#### Inclusion Criteria:

- Age  $\geq 18$  years
- Closed or open tibial plateau fractures classified as Schatzker type V or VI
- Planned management with Ilizarov circular external fixation.
- Willingness to participate and availability for regular follow-up for a minimum of 12 months

**Exclusion Criteria:**

- Presentation for surgery more than two weeks after trauma were excluded from the study.
- Pathological fractures
- Polytrauma patients requiring alternative fixation strategies

**Data Collection Procedure**

Data were prospectively collected using a structured case report form. Upon admission, baseline demographic and injury-related information including age, sex, mechanism of injury, fracture classification (Schatzker type) and time from injury to surgery were recorded. Operative details such as surgery duration, use of adjunct internal fixation and hospital stay were documented perioperatively. Postoperative follow-up assessments were conducted at scheduled intervals (6 weeks, 12 weeks, 6 months and 12 months) to record frame duration, radiological union, alignment, knee range of motion measured with a goniometer, functional

outcomes using the Knee Society Score (KSS) and complications including pin tract infection, joint stiffness, deep infection and loss of reduction. Radiological union was defined as bridging callus across at least three cortices on anteroposterior and lateral views.

**Statistical Analysis**

Data were analyzed using SPSS version 25.0. Continuous variables were expressed as mean  $\pm$  standard deviation, while categorical variables were presented as frequencies and percentages. Descriptive statistical methods were applied to summarize demographic, operative, radiological and functional outcome data. Inter-observer agreement for radiographic assessment was evaluated using Cohen's kappa coefficient.

**RESULTS****Table 1: Baseline Characteristics of Patients (n=30)**

Variable	Category	Frequency (n)	Percentage (%)
Age Group (years)	20–29	4	13.3
	30–39	7	23.3
	40–49	10	33.3
	$\geq 50$	9	30.0
Gender	Male	22	73.3
	Female	8	26.7
Mode of Injury	Motor Bike Accident	25	83.3
	Fall from Height	3	10.0
	Sports/Work-related	2	6.7
Fracture Type (Schatzker)	Type V	12	40.0
	Type VI	18	60.0
Mean Time to Surgery (days)		5.6 $\pm$ 2.3	

Table 1 presents the baseline characteristics of the study population. Patients were predominantly middle-aged, with the largest proportion aged 40–49 years (33.3%), followed by those aged  $\geq 50$  years (30.0%). Male patients constituted 73.3% of the cohort.

Motor bike accidents were the most common mechanism of injury (83.3%), while Schatzker type VI fractures accounted for 60.0% of cases. The mean interval from injury to surgery was 5.6  $\pm$  2.3 days.

**Table 2: Operative and Postoperative Parameters**

Parameter	Values, Mean $\pm$ SD or n (%)
Duration of Surgery (min)	105 $\pm$ 25
Hospital Stay (days)	8.2 $\pm$ 3.1
Mean External Fixator Duration (weeks)	18.5 $\pm$ 4.2
Additional Minimal Internal Fixation	10 (33.3%)

Table 2 describes operative and postoperative parameters. The mean duration of surgery was 105  $\pm$  25 minutes and the average hospital stay was 8.2  $\pm$  3.1 days.

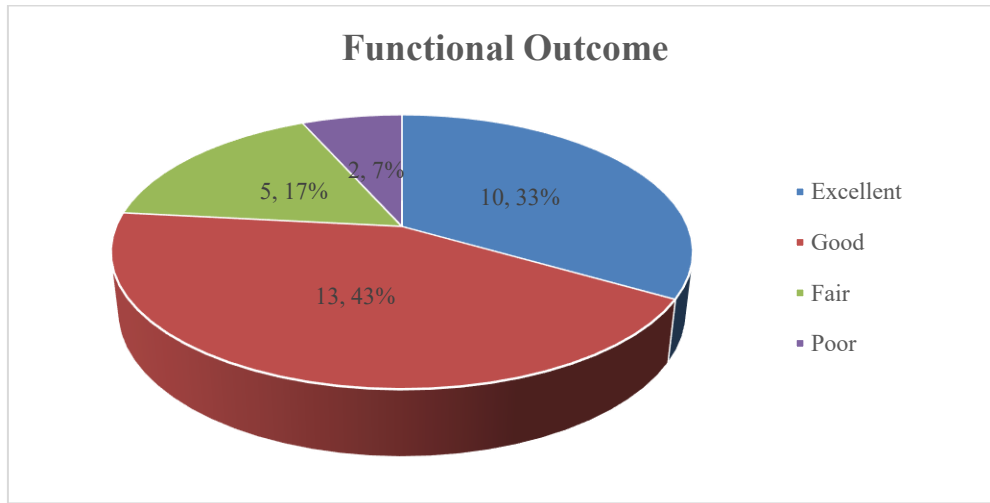
The Ilizarov frame was retained for a mean duration of 18.5  $\pm$  4.2 weeks. Additional minimal internal fixation was required in 33.3% of patients.

**Table 3: Radiological and Functional Outcomes at 12 Months**

Outcome Measure	Values, Mean $\pm$ SD or n (%)
Union Time (weeks), Mean $\pm$ SD	16.8 $\pm$ 3.5
Radiological Alignment (mild malalignment $< 5^\circ$ )	27 (90.0%)
Knee Range of Motion ( $^\circ$ ), Mean $\pm$ SD	115.3 $\pm$ 14.7
Knee Society Score (KSS), Mean $\pm$ SD	84.7 $\pm$ 10.2

Table 3 summarizes radiological and functional outcomes at 12 months. The mean time to fracture union was  $16.8 \pm 3.5$  weeks. Radiological alignment was satisfactory in 90.0% of patients, with only mild

malalignment ( $<5^\circ$ ). The mean knee range of motion was  $115.3 \pm 14.7$  degrees and the average Knee Society Score was  $84.7 \pm 10.2$ .



**Figure 1: Functional Outcomes at 12 Months**

Figure 1 demonstrates the distribution of functional outcomes at final follow-up, based on Knee Society Scores and knee range of motion. Most patients

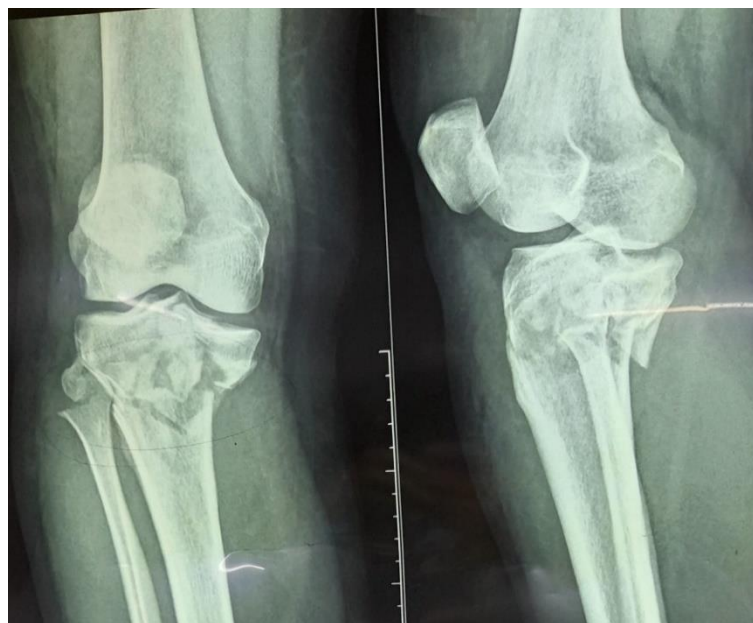achieved satisfactory functional recovery at 12 months after surgery.

**Table 4: Complications Observed During Follow-up**

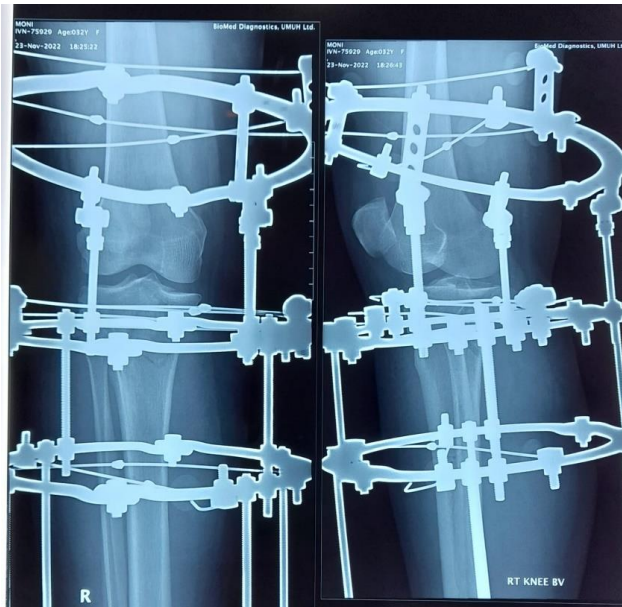
Complication Type	Frequency (n)	Percentage (%)
Pin Tract Infection (superficial)	6	20.0
Joint Stiffness	3	10.0
Deep Infection	1	3.3
Loss of Reduction	1	3.3

Table 4 presents complications observed during follow-up. Superficial pin tract infection was the most frequent complication (20.0%). Joint stiffness occurred

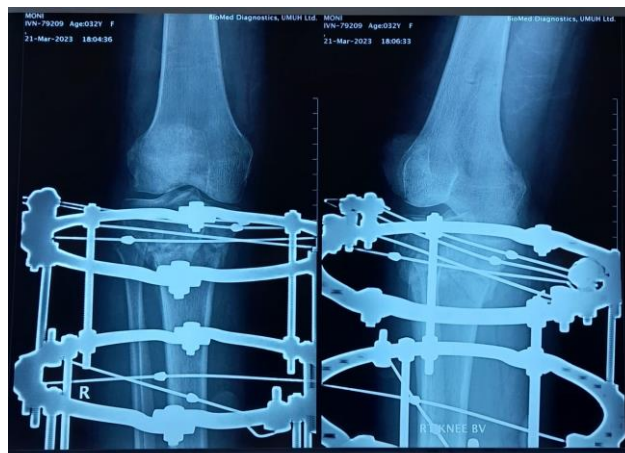
in 10.0% of patients, while deep infection and loss of reduction were each observed in 3.3% of cases.



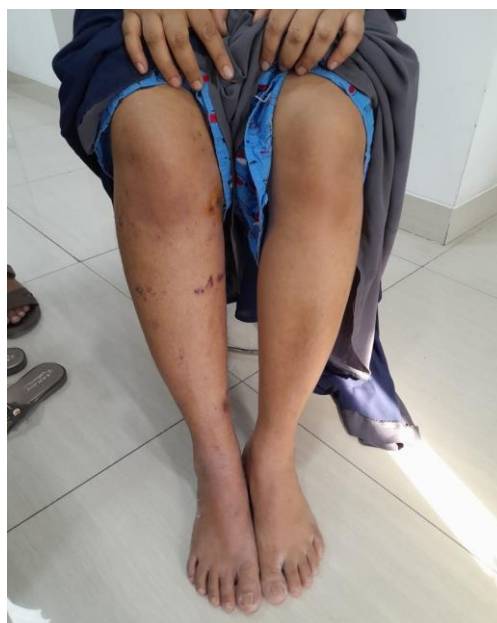**Figure 1: Pre-operative radiograph**



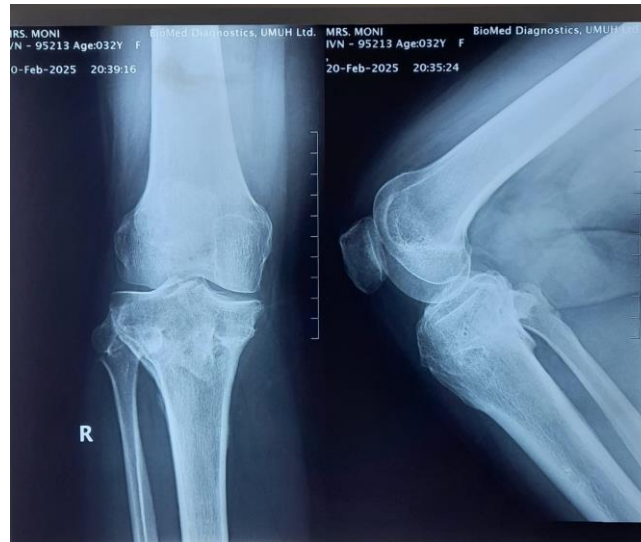
**Figure 2: Postoperative radiograph following Ilizarov external fixation with adjunct minimal internal fixation**



**Figure 3: Follow-up radiograph at four months demonstrating solid fracture union**



**Figure 4: Final clinical photograph**



**Figure 5: Final radiographs (anteroposterior and lateral views) of a complex Schatzker type VI tibial plateau fracture**

## DISCUSSION

The present study demonstrates that Ilizarov external fixation is an effective method for managing complex Schatzker type V and VI tibial plateau fractures, yielding 100% fracture union, maintenance of alignment and acceptable functional outcomes with a low incidence of major complications. These findings align with growing evidence that circular external fixation offers biological and mechanical advantages in high-energy proximal tibial injuries.

High-energy bicondylar tibial plateau fractures are frequently associated with severe metaphyseal comminution and compromised soft-tissue envelopes, factors that significantly increase the risk of complications following internal fixation. Raza *et al.*, reported that primary fixation using the Ilizarov external fixator provided stable fracture control while minimizing additional soft-tissue damage in complex tibial plateau fractures [13]. This biological advantage is particularly relevant in environments where delayed presentation and extensive swelling are common.

Fracture union in the current study occurred within a timeframe comparable to previously published series. Debnath *et al.* documented consistent union and early mobilization in Schatzker type VI fractures treated with ring fixators, emphasizing the role of controlled micromotion in promoting osteogenesis [11]. Similarly, Kumar *et al.*, reported reliable union in high-energy intra-articular tibial fractures managed with Ilizarov fixation, even in the presence of severe comminution [14]. These findings support the notion that circular fixation preserves the fracture biology while ensuring mechanical stability.

Maintenance of radiological alignment is a critical determinant of long-term knee function. Thiagarajah *et al.*, demonstrated that malreduction of

articular width in bicondylar tibial plateau fractures treated with circular external fixation was associated with the development of post-traumatic osteoarthritis [15]. In the present study, satisfactory alignment was achieved in the majority of patients, which may explain the favorable functional outcomes observed at one-year follow-up.

Functional recovery following tibial plateau fractures is multifactorial, influenced by alignment, joint congruity and rehabilitation protocols. Larsen *et al.* reported that patients treated with a combination of internal fixation and Ilizarov frames achieved acceptable patient-reported and functional outcomes at long-term follow-up [16]. Elsoe *et al.*, further demonstrated that although gait asymmetry may persist after bicondylar tibial plateau fractures, functional improvement continues during the first postoperative year following ring fixation [17]. The knee range of motion and Knee Society Scores observed in the present study are consistent with these findings.

Complication profiles in the current series were dominated by superficial pin tract infections, a well-recognized and generally manageable issue associated with circular external fixation. Subramanyam *et al.* reported similar rates of pin tract infection, noting that most cases resolved with local care and oral antibiotics without compromising outcomes [10]. Importantly, the low incidence of deep infection observed in this study is consistent with comparative literature suggesting reduced deep infection rates with external fixation compared to ORIF in complex tibial plateau fractures [8].

Comparative and meta-analytic evidence further supports the role of circular fixation in such injuries. Naja *et al.*, demonstrated in a meta-analysis that external fixation was associated with fewer soft-tissue

complications while providing comparable functional outcomes relative to ORIF [18]. Bertrand *et al.*, similarly reported that hybrid and circular external fixation offered a safer alternative in severe Schatzker V–VI fractures, particularly in the setting of compromised soft tissues [3].

Socioeconomic and functional implications of complex tibial fractures must also be considered. Elsoe *et al.*, highlighted that patients with complex tibial fractures treated with ring fixators often experience prolonged rehabilitation and social impact, underscoring the importance of achieving early stability and functional recovery [19]. Long-term studies by Karasev *et al.*, further confirmed that Ilizarov fixation provides durable outcomes with acceptable joint function over extended follow-up periods [20].

Pain-free movement is more important than a congruent joint with a stiff, painful joint. So, confirmation of the joint is more acceptable than congruence. Overall, the findings of this study reinforce existing evidence that Ilizarov external fixation is a reliable and biologically sound treatment modality for complex tibial plateau fractures, particularly in high-velocity injuries where preservation of soft tissue integrity is paramount, as well as pain-free joint movement.

#### Limitations and recommendations

The single center study with limited sample size restricts the generalizability of the findings. Future multicenter studies with longer follow-up are recommended to further validate functional outcomes and long-term joint preservation following Ilizarov fixation.

#### CONCLUSION

Ilizarov external fixation provides stable and biologically favorable management of complex Schatzker types V and VI tibial plateau fractures. This technique achieved satisfactory fracture union, maintained alignment and yielded acceptable functional outcomes with a low incidence of major complications. These results support the continued use of circular external fixation as a reliable alternative to internal fixation, particularly for high-energy injuries with compromised soft tissues.

#### Acknowledgment:

I would like to express my sincere gratitude for the invaluable support and cooperation provided by the staff, participants and my co-authors/colleagues who contributed to this study.

**Conflicts of interest:** There are no conflicts of interest.

#### REFERENCES

1. Ghimire A, Devkota P, Bhandari KK, Kharel Y, Pradhan S. Ilizarov ring external fixation for

complex tibial plateau fractures. *Revista Brasileira de Ortopedia*. 2022 Sep 2;57(04):667-74.

2. Baloch SR, Rafi MS, Junaid J, Shah M, Siddiq F, Ata-ur-Rahman S, Zohaib Z. Ilizarov fixation method of tibia plateau fractures: a prospective observational study. *Cureus*. 2020 Oct 31;12(10).
3. Bertrand ML, Pascual-López FJ, Guerado E. Severe tibial plateau fractures (Schatzker V–VI): open reduction and internal fixation versus hybrid external fixation. *Injury*. 2017 Nov 1;48: S81-5.
4. Singleton N, Sahakian V, Muir D. Outcome after tibial plateau fracture: how important is restoration of articular congruity? *Journal of orthopaedic trauma*. 2017 Mar 1;31(3):158-63.
5. Gaunder CL, Zhao Z, Henderson C, McKinney BR, Stahel PF, Zelle BA. Wound complications after open reduction and internal fixation of tibial plateau fractures in the elderly: a multicentre study. *International Orthopaedics*. 2019 Feb 14;43(2):461-5.
6. Elsoe R, Kold S, Larsen P, Petruskevicius J. A prospective observational study of 56 patients treated with ring fixator after a complex tibial fracture. *Strategies in Trauma and Limb Reconstruction*. 2017 Apr;12(1):35-44.
7. Hassan HU. Functional Outcome of Ilizarov Technique in Managing Proximal Tibial Fracture in Combined Military Hospital, Rawalpindi: Ilizarov in Tibial Fractures. *Journal of Islamabad Medical & Dental College*. 2022;11(4):204-10.
8. Zhao XW, Ma JX, Ma XL, Jiang X, Wang Y, Li F, Lu B. A meta-analysis of external fixation versus open reduction and internal fixation for complex tibial plateau fractures. *International Journal of Surgery*. 2017 Mar 1; 39:65-73.
9. Li Z, Wang P, Li L, Li C, Lu H, Ou C. Comparison between open reduction with internal fixation to circular external fixation for tibial plateau fractures: A systematic review and meta-analysis. *PloS one*. 2020 Sep 17;15(9): e0232911.
10. Subramanyam KN, Tammanaiah M, Mundargi AV, Bhoskar RN, Reddy PS. Outcome of complex tibial plateau fractures with Ilizarov external fixation with or without minimal internal fixation. *Chinese Journal of Traumatology*. 2019 Jun 1;22(03):166-71.
11. Debnath UK, Jha DK, Pujari PK. Results of ring (Ilizarov) fixator in high energy Schatzker type VI fractures of proximal tibia. *Journal of clinical orthopaedics and trauma*. 2018 Apr 1;9(2):186-91.
12. Tahir M, Kumar S, Shaikh SA, Jamali AR. Comparison of postoperative outcomes between open reduction and internal fixation and Ilizarov for Schatzker type V and type VI fractures. *Cureus*. 2019 Jun 14;11(6).
13. Raza A, Kumar S, Kumar D, Qadir A, Muzzammil M, Lakho MT. Complex tibial plateau fractures: primary fixation using the Ilizarov external fixator. A two-year study at civil hospital Karachi, Pakistan. *Cureus*. 2019 Aug 13;11(8).

14. Kumar J, Siddiqui AA, Katto MS, Jamil M, Wasim MA, Yaqoob U. Treatment of high-energy intra-articular fractures of tibia with Ilizarov external fixator in adults: A tertiary centre experience. *International Journal of Clinical Practice*. 2021 Sep;75(9): e14488.
15. Thiagarajah S, Hancock GE, Mills EJ, McGregor-Riley JC, Royston SL, Dennison MG. Malreduction of tibial articular width in bicondylar tibial plateau fractures treated with circular external fixation is associated with post-traumatic osteoarthritis. *Journal of orthopaedics*. 2019 Jan 1;16(1):91-6.
16. Larsen P, Traerup J, Mikuzis M, Elsoe R. Patient-reported and functional outcomes of bicondylar Tibial Plateau Fractures managed by internal screw fixation in combination with an ilizarov fixator: a case series of 22 patients with long-term follow-up. *Strategies in Trauma and Limb Reconstruction*. 2019 May;14(2):85.
17. Elsoe R, Larsen P. Asymmetry in gait pattern following bicondylar tibial plateau fractures—A prospective one-year cohort study. *Injury*. 2017 Jul 1;48(7):1657-61.
18. Naja AS, Bouji N, Eddine MN, Alfarii H, Reindl R, Tfayli Y, Issa M, Saghie S. A meta-analysis comparing external fixation against open reduction and internal fixation for the management of tibial plateau fractures. *Strategies in Trauma and Limb Reconstruction*. 2022 May;17(2):105.
19. Elsoe R, Larsen P, Petruskevicius J, Kold S. Complex tibial fractures are associated with lower social classes and predict early exit from employment and worse patient-reported QOL: a prospective observational study of 46 complex tibial fractures treated with a ring fixator. *Strategies in Trauma and Limb Reconstruction*. 2018 Apr;13(1):25-33.
20. Karasev AG, Zhdanov AS, Darvin EO, Karaseva TY, Sutyagin IV, Lushnikov AV. Long-term outcomes of surgical treatment of patients with tibial plateau fractures repaired with Ilizarov external fixation.