

Buccal Fat Pad Removal and Masseter Muscle Botox for Improving Facial Aesthetic: A Systematic Review of Clinical Trials

Abdulaziz Abdullah Alabood^{1*}

¹College of Dentistry, King Saud University, Riyadh, Saudi Arabia

DOI: [10.36348/sjbr.2022.v07i12.001](https://doi.org/10.36348/sjbr.2022.v07i12.001)

| Received: 11.10.2022 | Accepted: 24.11.2022 | Published: 04.12.2022

*Corresponding author: Abdulaziz Abdullah Alabood
College of Dentistry, King Saud University, Riyadh, Saudi Arabia

Abstract

Introduction: Masseter muscle hypertrophy can cause a prominent mandibular angle, which results in an unaesthetic lower face contour. Botox injection is a minimally invasive procedure compared to conventional surgery and is safe and easy to handle. Patients often request an aesthetic alteration by surgical procedures or masseter muscle injections to attain an aesthetic facial contour. While aesthetic surgery can reshape the lower face contour, numerous patients still choose a minimally invasive therapeutic approach. **Aim:** This study aims to review published articles that discussed the effect of buccal fat pad removal versus masseter muscle Botox for improving facial aesthetics. **Materials and Methods:** A literature search was performed from multiple databases including PubMed, Web of Science, Cochrane, and Google Scholar. The most eligible articles were included using specific keywords. The literature search was limited to full-text English articles, which were screened for eligibility by two reviewers. **Results and Discussion:** Six studies were included in our study, these studies demonstrated that aesthetic results were improved in all discussed clinical trials. However, more clinical trials are needed for fat pad removal surgery trials. **Conclusion:** Our study showed that masseter muscle Botox injection can improve overall facial aesthetic appearance. However, more clinical trials are needed for buccal fat pad removal surgery.

Keywords: Buccal fat pad removal, masseter muscle Botox, facial aesthetics.

Copyright © 2022 The Author(s): This is an open-access article distributed under the terms of the Creative Commons Attribution 4.0 International License (CC BY-NC 4.0) which permits unrestricted use, distribution, and reproduction in any medium for non-commercial use provided the original author and source are credited.

INTRODUCTION

A lower face shape that is characterized by a wide and square jaw is one of the main esthetic problems, especially in Asia [2, 4]. The lower face contour depends on the masseter muscle, the soft tissues, and the thickness of the mandibular bone [4]. Masseter hypertrophy can increase the mandibular angle, which results in an unaesthetic lower face wide contour [3, 4]. The cause of masseter hypertrophy is still unidentified, while numerous causes have been introduced [4]. The use of botulinum toxin type A for the treatment of masseteric hypertrophy was first suggested in 1994 [5]. Compared to conventional surgery, Botox injection is a minimally invasive procedure and is safe and easy to handle [3]. To attain an aesthetic facial contour, patients often request an aesthetic modification by surgical approaches or masseter muscle injections. While aesthetic surgery can reshape the lower face, however, numerous patients still choose minimally invasive therapy [4]. Previous studies have discussed buccal fat pad removal and masseteric

muscle injections for improving the facial aesthetic, this current systematic review aims to review published articles that discussed the effect of buccal fat pad removal versus masseter muscle Botox for improving facial aesthetics.

MATERIAL AND METHODS

Elaboration

This systematic review followed the guidelines of the Preferred Reporting Items for Systematic Review and Meta Analyzes Protocols (PRISMA 2020). The acronym PICOS was used according to the research question “the effect of buccal fat pad removal versus masseter muscle Botox for improving facial aesthetics?” P = Patients pre and post-procedure; I = Botox injections and buccal fat removal; C = Control group; O = Aesthetic results. The search strategy was applied to PubMed, Cochrane, Google Scholar, and Web of science on Oct 11, 2022, without the restriction of time and is demonstrated in (Fig 1).

Eligibility Criteria

For the selection process of the articles to be included in this systematic review, all articles that evaluated the effect of buccal fat pad removal versus masseter muscle Botox for improving facial aesthetics were defined as inclusion criteria. Exclusion criteria are as follows: (1) Did not evaluate the effect of buccal fat pad removal, (2) Did not evaluate masseter muscle Botox injections; (3) Did not discuss aesthetic results (4) Non-English language articles, (5) Articles with no full text available.

Selection Process

The articles were selected in two stages. In the first step, reviewers B.F and A.A evaluated the title and abstract of the articles found after applying the search strategy according to the eligibility criteria, to select the articles to be read in full. In the second step, B.F and A.A independently assessed the articles selected for full reading according to the eligibility criteria.

Data Extraction

Data arrangement was performed in an Excel spreadsheet according to the criteria (a) Author, (b) Aims and objectives; (c) The total number of samples; (d) Year of publications; (e) Results. Illustrated in (Table 1).

Risk of Bias

The risk of bias classification was performed in the RevMan 5.3 software (The Nordic Cochrane Center) according to the criteria (1) Low risk of bias (high methodological quality), (2) Moderate risk of bias (moderate methodological quality), (3) High risk of bias (low methodological quality). All included studies demonstrated low-risk bias (high methodological quality). No insufficiency concerning the data outcome was observed for all articles. A general analysis of the risk of bias in the studies is demonstrated in (Fig 2).

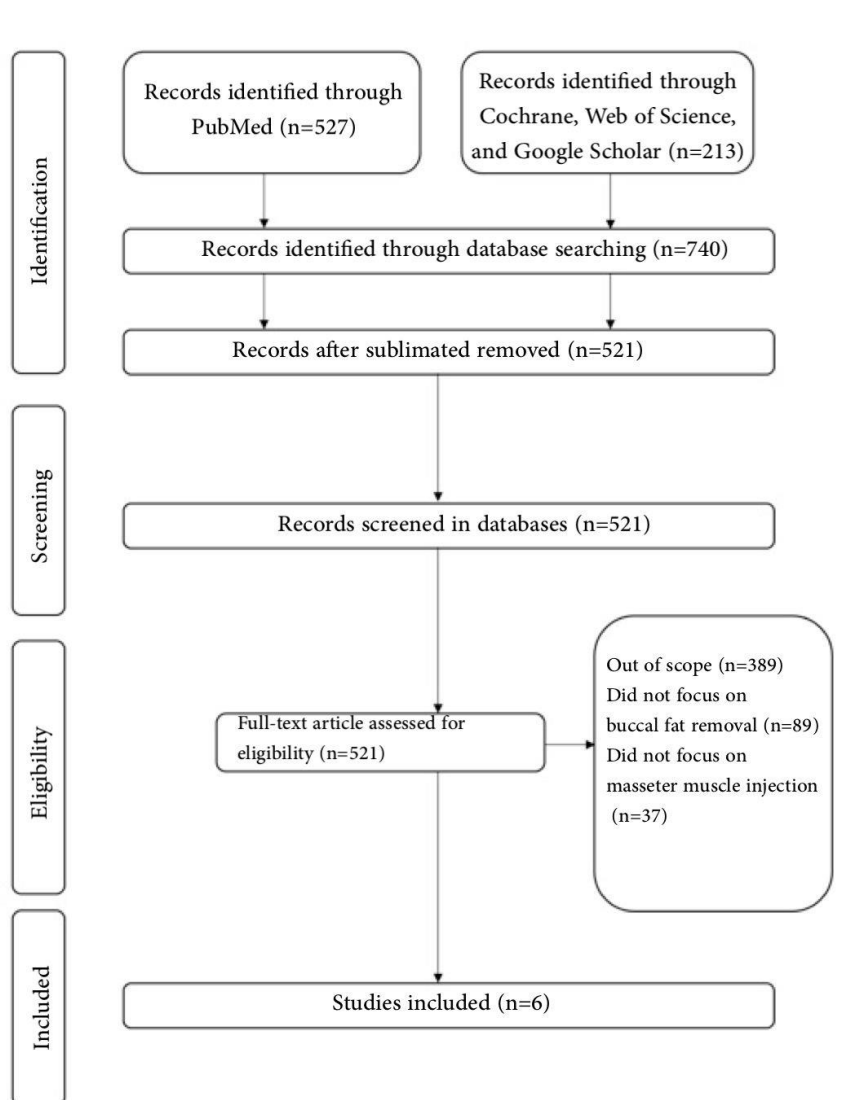


Fig 1: Study flow chart

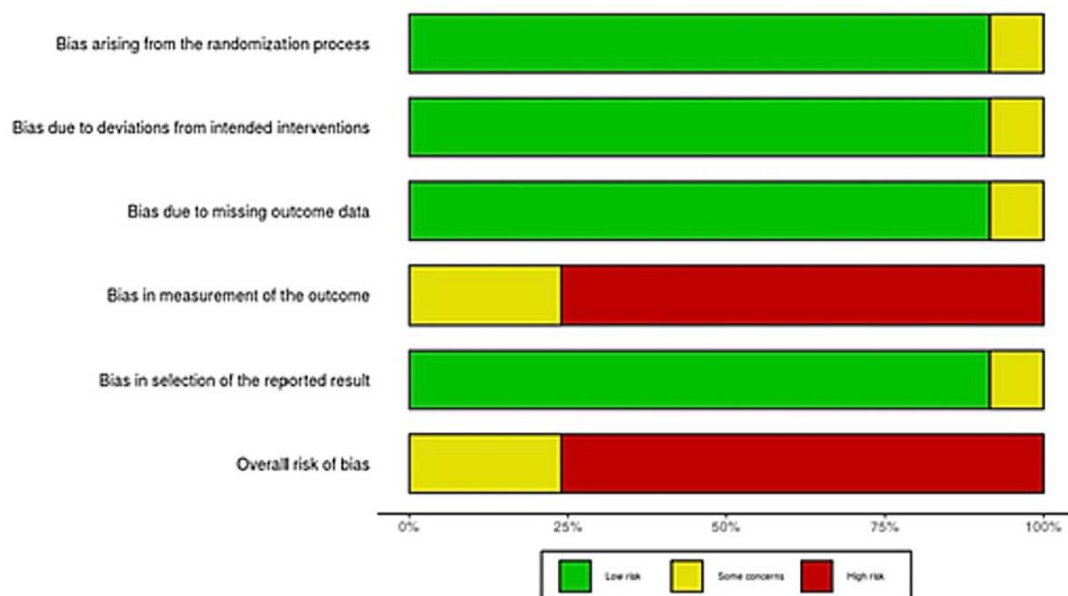


Fig 2: General analysis of the risk of bias in the studies

RESULTS

Six studies were included in our results. A minimum number of studies discussed buccal fat pad removal to improve the facial aesthetic appearance. Orlando *et al.*, assessed long-term psychometric outcomes of surgical treatment of HIV-related facial lipoatrophy. The author concluded that all the participants had significant improvement in their aesthetic appearance [1]. On the other hand, Hong *et al.*, investigated botulinum toxin for masseteric hypertrophy treatment. The results showed that Prabotulinum toxin A can improve lower face contour [2]. Another study by Xie *et al.*, established a masseter classification method for botulinum toxin type a

protocol. Improved lower face contour was also suggested by the authors [3]. Shome *et al.*, evaluated the effectiveness of Botox type A in the management of masseter hypertrophy. The results showed an effective in the management of masseter hypertrophy with satisfactory facial esthetic [4]. Lee *et al.*, assessed the changes in the lower facial contour achieved with BoNT-A. He concluded that the administration of the second dose of BoNT- A injection contributes to better aesthetic results [5]. Kim *et al.*, evaluated the effects of botulinum toxin type A on masseteric hypertrophy. The results demonstrated that nine subjects showed aesthetically good results [6]. Characteristics of included studies are presented in (Table 1).

Table 1: Characteristics of included studies

Author	Aims and objectives	Total number of Sample	Year of publication	conclusion
Orlando <i>et al.</i> ,	assess long-term psychometric outcomes of surgical treatment of HIV-related facial lipoatrophy	299 participants	2007	All the participants had significant improvement in the aesthetic appearance
Hong <i>et al.</i> ,	Investigate botulinum toxin for masseteric hypertrophy treatment	90 participants	2021	Prabotulinum toxin A can improve lower face contour
Xie <i>et al.</i> ,	Establish a masseter classification method for botulinum toxin type A protocol	504 participants	2014	Improved the lower face contour
Shome <i>et al.</i> ,	Evaluate effectiveness of Botox type A in management of masseter hypertrophy	50 participants	2019	Effective for management of masseter hypertrophy with satisfactory facial esthetic.
Lee <i>et al.</i> ,	Assess the changes in the lower facial contour achieved with BoNT-A	20 participants	2015	Administration of a second dose of BoNT-A injection contribute to better aesthetic results
Kim <i>et al.</i> ,	Evaluate the effects of botulinum toxin type A on masseteric hypertrophy	11 participants	2003	Nine subjects showed aesthetically good results

DISCUSSION

Few studies discussed about fat pad removal and its contribution to better aesthetic results. Most of the clinical trials discussed about masseter muscle injection and their effect on facial aesthetic contour. Shome *et al.*, evaluated the effectiveness of Botox type A in the management of masseter hypertrophy. The results showed an effective in the management of masseter hypertrophy with satisfactory facial esthetic [4]. Kim *et al.*, evaluated the effects of botulinum toxin type A on masseteric hypertrophy. The results demonstrated that nine subjects showed aesthetically good results [6]. Orlando *et al.*, assessed long-term psychometric outcomes of surgical treatment of HIV-related facial lipoatrophy. The author concluded that all the participants had significant improvement in their aesthetic appearance [1]. On the other hand, Hong *et al.*, investigated botulinum toxin for masseteric hypertrophy treatment. The results showed that Prabotulinum toxin A can improve lower face contour [2]. Lee *et al.*, assessed the changes in the lower facial contour achieved with BoNT-A. He concluded that the administration of the second dose of BoNT-A injection contributes to better aesthetic results [5]. Another study by Xie et al established a masseter classification method for botulinum toxin type a protocol. Improved lower face contour was also suggested by the authors [3].

CONCLUSION

Our study showed that masseter muscle Botox injection can improve overall facial aesthetic appearance. However, more clinical trials are needed for buccal fat pad removal surgery. Aesthetic results were improved in all discussed clinical trials and more clinical trials are needed for fat pad removal surgery.

Conflicts of interest: The authors reported no conflicts of interest related to this study.

Acknowledgment: I would like to thank King Saud University for their usual cooperation.

Financial support and sponsorship: No

REFERENCES

- Orlando, G., Guaraldi, G., De Fazio, D., Rottino, A., Grisotti, A., Bline, M., ... & Esposito, R. (2007). Long-term psychometric outcomes of facial lipoatrophy therapy: Forty-eight-week observational, nonrandomized study. *AIDS Patient Care and STDs*, 21(11), 833-842. doi:10.1089/apc.2007.0029
- Hong, J. Y., Jeong, G. J., Kwon, T. R., Kim, J. H., Li, K., & Kim, B. J. (2021). Efficacy and safety of a novel botulinum toxin A for masseter reduction: A randomized, double-blind, placebo-controlled, optimal dose-finding study. *Dermatologic Surgery*, 47(1), e5-e9. doi:10.1097/DSS.0000000000002475
- Xie, Y., Zhou, J., Li, H., Cheng, C., Herrler, T., & Li, Q. (2014). Classification of masseter hypertrophy for tailored botulinum toxin type A treatment. *Plastic and Reconstructive Surgery*, 134(2), 209e-218e. doi:10.1097/PRS.0000000000000371
- Shome, D., Khare, S., & Kapoor, R. (2019). Efficacy of botulinum toxin in treating Asian Indian patients with masseter hypertrophy: a 4-year follow-up study. *Plastic and reconstructive surgery*, 144(3), 390e-396e. doi:10.1097/PRS.0000000000005944
- Lee, H. H., Kim, S. T., Lee, K. J., & Baik, H. S. (2015). Effect of a second injection of botulinum toxin on lower facial contouring, as evaluated using 3-dimensional laser scanning. *Dermatologic Surgery*, 41(4), 439-444. doi:10.1097/DSS.0000000000000291
- Kim, H. J., Yum, K. W., Lee, S. S., Heo, M. S., & Seo, K. (2003). Effects of botulinum toxin type A on bilateral masseteric hypertrophy evaluated with computed tomographic measurement. *Dermatologic surgery*, 29(5), 484-489. doi:10.1046/j.1524-4725.2003.29117.x