

Experience and Limitations of Gynecological Laparoscopy for a Beginner in Private Practice

Dr. Nishat Anam Borna^{1*}, Dr. A. N. M. Mozammel Haque²

¹Jr. Consultant (Obs & Gyn), Paba Upazila Health Complex, Paba, Rajshahi, Bangladesh

²Associate Professor, Department of Surgery, Rajshahi Medical College, Rajshahi, Bangladesh

DOI: [10.36348/sijog.2022.v05i06.006](https://doi.org/10.36348/sijog.2022.v05i06.006)

Received: 11.05.2022 | Accepted: 07.06.2022 | Published: 28.06.2022

*Corresponding author: Dr. Nishat Anam Borna

Jr. Consultant (Obs & Gyn), Paba Upazila Health Complex, Paba, Rajshahi, Bangladesh

Abstract

Introductions: Minimally invasive surgery is now the standard surgical procedure for benign gynecological diseases and plays an increasing role in their treatment. This study presents a personal series of an evaluation of the laparoscopic surgical approach. Its outcomes in the surgical treatment of patients with benign gynecological diseases. **Aim:** The study aimed to evaluate the outcome of gynecological laparoscopy in a low-resource setting. **Method:** This cross-sectional study was conducted in a private hospital in Rajshahi, Bangladesh. It is a retrospective surgical series of patients performed by the author, which analyzes (n=24) female patient treated from 2019 to December 2020. **Results:** A number of 24 female patients were included in this study; their mean age was 32.6 years. Among them diagnostic laparoscopy was done in 13 patients. This is mostly due to primary sub-fertility and therapeutic laparoscopy in 11 patients (2 salpingectomy for ectopic pregnancy, 3 laparoscopically assisted vaginal hysterectomy, 1 myomectomy, 1 TLH, 1 laparoscopic adhesiolysis, 2 Ovarian cystectomy, and 1 left sided salpingoophorectomy was done for ovarian cyst). 1 laparoscopic procedure for LAVH was converted to laparotomy due to excessive bleeding. 20 patients were released without incident, but post-Surgical site infection occurred in 1 patient. There was no significant difference in operative complications, blood loss, or length of hospital stay compared to conventional laparoscopic surgery reported in the literature. The perioperative complications are minimal in this personal series. In this study, laparoscopic myomectomy and laparoscopic adhesiolysis for pelvic endometriosis. It took longer to perform using this approach compared with other procedures. **Conclusion:** Despite having many benefits over conventional procedures, gynecological laparoscopy has several limitations, especially in a low resource-poor setting (Lack of knowledge, Popularity among patients, Higher cost, Long learning curve, Instrumental backup). This paper reported a feasible and safe surgical approach to laparoscopic surgery for gynecological diseases.

Keywords: LAVH±BSO, SILS, TLH, LH.

Copyright © 2022 The Author(s): This is an open-access article distributed under the terms of the Creative Commons Attribution 4.0 International License (CC BY-NC 4.0) which permits unrestricted use, distribution, and reproduction in any medium for non-commercial use provided the original author and source are credited.

INTRODUCTION

Nearly all surgery produces surgical scars. For the time being, no endoscopic surgery is scarless. The new single-incision laparoscopic surgery (SILS) and natural orifice surgical approaches are the latest innovations in surgical endoscopy. They produce reduced numbers of scars that may not be visible to others except for the doctors and the patients. However, these surgical approaches may require the modifications of surgical instruments and a longer learning curve to facilitate the surgery. These laparoscopic approaches help to reduce the number of accessory ports and also their potential complications. Thus, they provide a safe,

"scarless" and an esthetic option than conventional laparoscopy or open surgery [1, 2]. Because there is a single incision, patients often enjoy a speedy recovery after the surgery and are impressed with this single scar approach.

The single port surgical approach, however, is clumsy to perform because of its operating limitations. Even with the use of flexible camera and modified laparoscopic instruments to facilitate the procedures, these additional instrumentations are expensive and also do not overcome the intrinsic difficulties to perform these single port surgeries. This single port approach

also requires a specially designed expensive portal device to enable surgeons to achieve and complete their operations. It imposes additional costs without any documented operative advantages. Although some surgeons used multiple conventional trocars placed at the umbilicus to perform cosmetically the same, a single-site, multiple incisions laparoscopic surgery (at the umbilicus), they still encountered the same technical difficulties as the single port surgery. Wong and Lee, in 2014, reported and shared their preliminary experience of a modified laparoscopic surgery technique [3]. Using this "modified 3 ports approach", the author now demonstrates in a larger series of patients that this laparoscopic approach possesses the technical advantages of "reduced scars", esthetic and ease over the conventional laparoscopy.

Surgical approach

This evaluation of laparoscopic surgery has the crucial features to position the three portal incisions in the abdomen that can hardly be noticeable after their healing. The positions of these three ports are 1) a small 5-mm incision is at the 8 o'clock position of the para umbilicus with two lateral port which allows direct entry of an optical tip trocar and cannula as described previously by the author [4]; 2) another 5-mm trocar/cannula is at 0.3 cm-0.5 cm away, but at the 4 o'clock position of the umbilicus; 3) an additional port is placed at either the mid-suprapubic point just below the level of the pubic hairline or anywhere at the left or right lower abdominal quadrant wherever convenient for the surgeon's operating manipulation. Sometimes, a 3-mm mini-port trocar and cannula were used, which could result in an even smaller sized scar, to enhance the cosmetic effect (Figure 1).

A straight 5 mm 0-degree conventional laparoscope and standard operative instruments are used with this approach. The use of angulated instruments or flexible camera is not required. Even with conventional instruments and laparoscope, there are only minimal clashing between the laparoscope and the other umbilical portal instrument. Because of the limited space between them, the two cannulas' heads at the umbilicus should be of small sizes; the laparoscope and the operating instrument can then manipulate freely at operation without any interference.

When it is necessary to retrieve surgical specimens from the peritoneal cavity, one of the 5-mm port incisions at the umbilicus is enlarged to a 10–12 mm incision, followed by the insertion of a blunt 10–12-mm trocar and cannula. This enlarged umbilical port of 11-12 mm size serves to introduce an end bag for the collection and retrieval of the operative specimen. On the other hand, this enlarged port/wound can be used for inserting a 10-mm grasping forceps or a 12-mm electric morcellator for myomectomy and morcellation. The introduction of a needle for surgical suturing is also feasible with this portal arrangement. The instruments

at the left lower abdominal port will be manipulated as with our usual standard three ports or four ports laparoscopic procedure.

In this approach, the surgical steps for the common gynecological operations are similar to those of conventional laparoscopic procedures. Special surgical techniques if any are described as follows:

Adnexal surgery

The techniques to perform salpingo-oophorectomy, oophorectomy, and ovarian cystectomy had been previously described in the preliminary paper in 2014. There was no major change in surgical techniques. The adnexal disease was easily exposed by moving the uterine manipulator. The operation proceeded to divide any adhesions, perform ovarian cystectomy or remove pelvic tumors by blunt and sharp dissection using two operating instruments without crossing over, and finally, hemostasis was ensured. An endobag was inserted through a 10 mm port at the umbilicus; specimens were placed inside the bag and removed via the 10 mm portal wound at the umbilicus. Larger specimens, including large dermoid cyst or chocolate cyst wall, were retrieved by piecemeal removal within the bag at the umbilicus. The rest of the surgery, such as checking hemostasis, placement of adhesive barrier materials, surgical suturing, were performed similarly to the conventional laparoscopy.

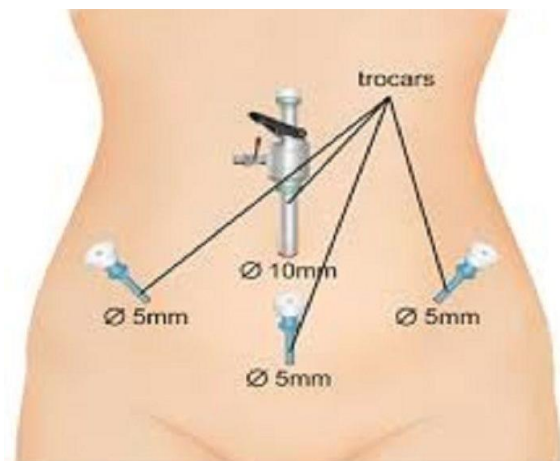


Fig-1: The positions of surgical ports in the modified laparoscopic surgery - two lateral port at the umbilicus, two 5 mm cannula or one 5mm/one 10 mm cannula. The third trocar and cannula are positioned at the left lower quadrant of the abdomen

Myomectomy

There had not been much technical improvement in dealing with fibroid larger than 8 cm in diameter because it would be difficult to remove a large fibroid from the uterus. The surgical manipulation at the level of the umbilicus would not allow easy removal of a large fibroid. To place the operative port at a higher abdominal position, would defeat the purpose of this approach [5]. Therefore, laparoscopic myomectomy for

a larger fibroid > 8 cm was performed using other conventional laparoscopy approaches. After extraction of the fibroid from the uterus, the fibroid was then placed in an end bag and left temporarily aside. The myomectomy wound was then sutured using barbed sutures to close the wound and to control hemostasis. The 5-mm laparoscope was then transferred to the lateral abdominal port to provide direct monitoring of the morcellation process, to ensure safety. The fibroid was then morcellated and removed piece by piece using a 12-mm electrical morcellator under direct visualization. There was no surgical failure after those huge fibroids were excluded for this approach. The myomectomy procedure was shown in Figure 4.

In this approach, the lateral lower quadrant abdominal wound remained as a 5 mm portal wound, which was used to monitor the morcellation procedure, to remove debris and assist in the uterine wound suturing.

Hysterectomy

Laparoscopy-assisted vaginal hysterectomy [LAVH ± BSO] was the only procedure for patients who underwent a hysterectomy in this series of patients. In the early stage, the author had used total laparoscopic hysterectomy (LH) and laparoscopic subtotal hysterectomy (LSH) and LAVH using this new portal arrangement, LAVH was then chosen. Technically, with this approach, both TLH and LSH could be performed, but the dissection of the vaginal vault and vault suturing was found to be more difficult. With the LAVHs, after the laparoscopic part was completed, the uterus could be easily removed through the vagina with or without morcellation, and the vaginal vault closed. There were no technical difficulties encountered while performing the LAVH procedure with this approach. Therefore, LAVH is the most suitable procedure for using this approach because technically, it is an easier procedure compared to the total laparoscopic hysterectomy, demanding less time, less bleeding, less skill, and laparoscopic suturing.

RESULT

Laparoscopic surgery using the modified 3 ports approach was performed in 24 Female patient for

various gynecological diseases (Table 1). Their mean age was 32.6 years. Among there, laparoscopy was done in 13 patients. This is mostly due to primary sub-fertility and therapeutic laparoscopy in 11 patients (2 salpingectomy for EP, 3 LAVH, ectopic pregnancy, 3 laparoscopically assisted vaginal hysterectomy, 1 myomectomy, 1 TLH, 1 laparoscopic adhesiolysis, 2 Ovarian cystectomy, and 1 Lt sided salpingo Oophorectomy was done for ovarian cyst). 1 laparoscopic procedure for LAVH was converted to laparotomy due to excessive bleeding. 20 of the patients. The second POD was uneventful, and we released without incident. But post-Surgical site infection occurred in 1 patient. There was no significant difference in operative complications, blood loss, or length of hospital stay compared to conventional laparoscopic surgery reported in the literature. The perioperative complications are minimal in this personal series. In this study, laparoscopic myomectomy and laparoscopic adhesiolysis for pelvic endometriosis. It took longer to perform using this approach compared with other procedures. Overall, cosmetics was excellent with scars hardly visible, as shown in Figure 4.

DISCUSSION

Minimally invasive surgery has now established as the standard surgical procedure for benign gynecological diseases and plays an increasing role in their treatment. However, the conventional laparoscopic surgery using three to four ports is now considered by some to be unnecessary. Single port surgery is a rapidly developing surgical procedure and marks a new frontier in laparoscopy. It has not widely adopted in gynecological surgery for several reasons: (1) Inconvenient operations with clashing and "sword fighting" of the instruments. (2) Loss of angulation directions for suturing, tissue separation, and hemostasis. (3) Some surgeons may require purposely designed instruments to facilitate the ease of surgery, thus increasing the cost of operation. (4) More extended training because of the long learning curve. (5) More demanding skills in challenging situations. Despite its reported success in some centers, short-term or long-term complications still occur [6,7].

Table-1: Showed that 24 patients had the laparoscopic surgery. The patients' characteristics, pathology, gynecologic procedures, and outcomes were listed.

Type of surgeries	Patient no	Age (mean)	Pathology	Hospital stay (av)	Complications
Primary sub-fertility	13	32.6	Tubal pathology, peritoneal factors, endometriosis, and intra-abdominal causes of infertility	3.1	Surgical site infection occurred in 1 patient.
Salpingectomy	2	41.1	Tubal rupture, severe tubal damage, recurrence of ectopic pregnancy in the same tube,	3.4	
LAVH	3	42	Fibroids, adenomyosis, DUB, polyps, CIN2-3, hematometra,	3.1	
TLH	1	51.1	Uterine leiomyomas, abnormal uterine bleeding, endometriosis and prolapse	3.3	
Ovarian cystectomy	2	51.1	cystadenoma, dermoid cysts, periovarian cyst, ovarian fibroma	2.1	
Salpingo Oophorectomy	1	44.2	Endometriosis	3.1	
Lap myomectomy	1	41.3	Fibroids, adenomyosis	2.3	
laparoscopic adhesiolysis	1	39	Pelvic adhesions, endometriosis, abscess, ectopic pregnancy	3.3	

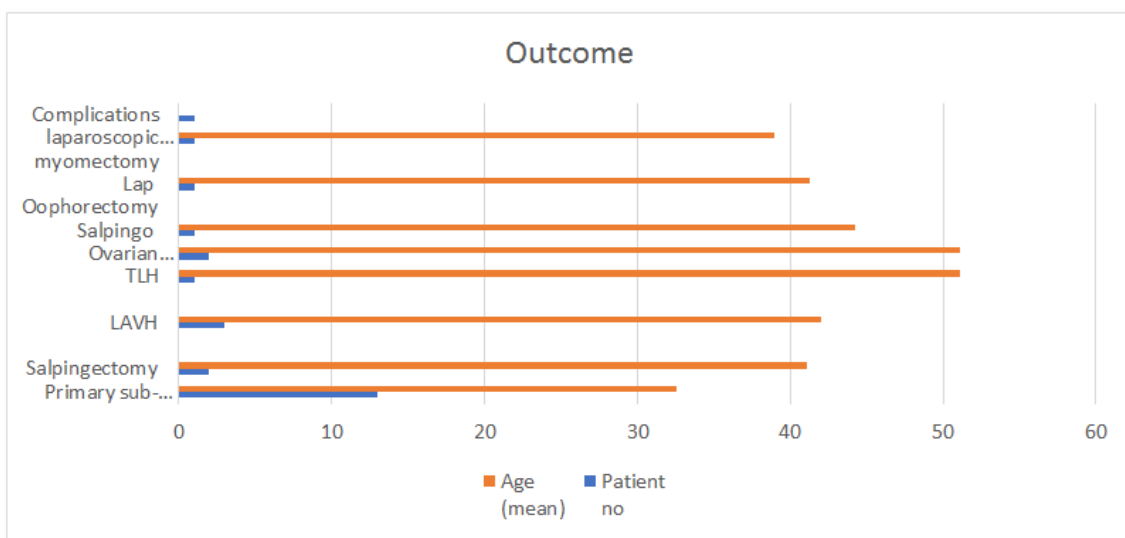


Fig-2: The patients' characteristics, pathology, gynecologic procedures, and outcomes were listed

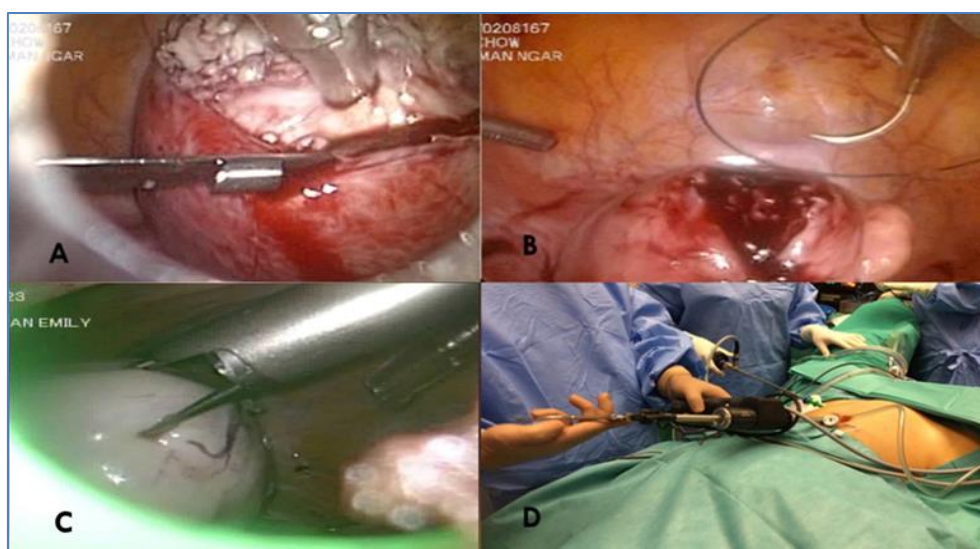


Fig-3: Laparoscopic myomectomy using modified approach A) Myomectomy performed in the usual manner. B) Myomectomy wound suturing using barbed suture. C) Electric morcellation of fibroid. D) External view of morcellation of fibroid under direct vision by laparoscopy from the lateral abdominal port

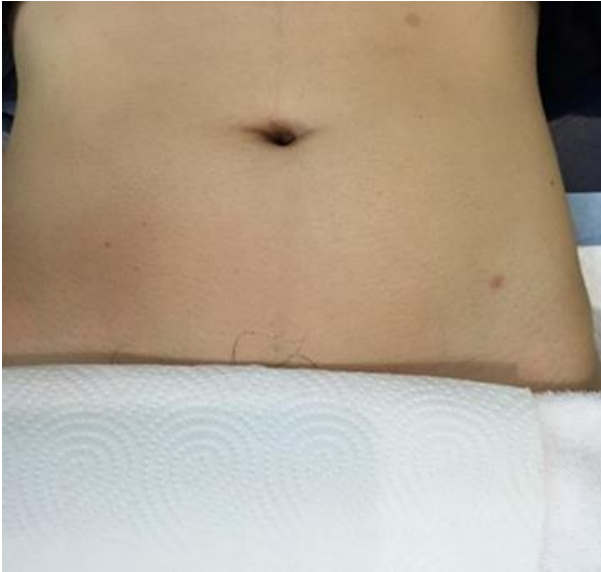

Fig-4: Good aesthetic scars after the modified 3 ports laparoscopic surgery

This present approach has adopted the single-port laparoscopic surgery concept of reduced scars to modify the three-port surgical approach, with two ports placed at the umbilicus, and one port elsewhere in the body. Any laparoscopic procedures for benign gynecological diseases can be performed with the surgeon operating with the common laparoscopic instruments, manipulating at portal sites similar to conventional laparoscopic surgeries. This approach will not only shorten the learning curve and reduce the difficulties encountered in single port surgery but will also provide satisfactory outcomes.

With the increasing number of patients operated in this personal series, there are additional techniques that may need elaboration to make it easier for others to follow and perform laparoscopic surgery with this approach. The following is a list of advice in addition to those presented in the preliminary study [3].

- i. A 5 mm laparoscope instead of a 10 mm laparoscope should be used. However, it can pose some difficulties in maintaining a consistently good visual field because it is easy to get obscured by blood contamination or smoke, resulting in blurred vision. When this happens, clear vision can be regained by touching the tip of the laparoscope to the surrounding bowel or pelvic peritoneum. Time may be saved by not having to remove the laparoscope for cleaning.
- ii. The laparoscope should be held behind and view the operating instrument at a distance to avoid clashing with operating instruments during an operation.
- iii. Due to the small caliber of the 5 mm laparoscope lens, the use of an older laparoscope, impaired light cord, any increased

bleeding in the pelvis will cause a dark and unclear operating field. The laparoscope and light cord should be well maintained and checked before the operation. Bleeding should be controlled promptly, and hemostasis achieved to allow a clear view for easy operation.

- iv. The clashing of the laparoscope with the operating instrument at the umbilicus can still be a problem. The movements of both should be in the same direction together, not to crossing each other. However, experience in this approach is essential to perform the surgery smoothly and safely.
- v. Fibroids about 8 cm or less in size can be satisfactory and conveniently morcellated inside an end bag under direct laparoscopic vision or morcellated by a cold knife at the umbilical wound by enlarging the two umbilical portal wounds. The latter approach may, however, create a bigger umbilical scar.
- vi. Complicated surgeries like severe pelvic adhesions and advanced pelvic endometriosis are still difficult to perform with this approach because of the extent of disease can be widespread, which could be away from the operation field of the laparoscopic instruments.
- vii. On some occasions, it is not a shame to abandon this approach, make a few more portal incisions, and operate using three to four ports. Alternatively, a wound can be enlarged to make the procedure operable and safe.
- viii. If there are suspected adhesions at the umbilical site after previous laparoscopic surgeries, the introduction of the laparoscope should be under laparoscopic vision using an optical guided trocar, e.g., the Endo path Xcel Trocar, with a technique previously described by the author [4]. The direction of the trocar entry should be directed to the side less likely to have adhesions such as left-sided entry when previous surgery was on the right side. Most importantly, any suspected injury can be recognized, and repair is done promptly.

CONCLUSIONS

In this larger follow-up series, some limitations of the study mentioned previously, such as single-surgeon experience, non-comparative study design, and patient selection bias, are less of a problem. Due to the difficulties of randomized studies in a single surgeon operation situation, surgical techniques can be biased and limited toward one's experience, for example, the LAVH approach for hysterectomy in this study.

Nevertheless, the outcome of this laparoscopic approach is obvious with the following advantages: (1) less clashing of instruments, operations are mainly performed in a way similar to the conventional

laparoscopic surgery; (2) a less expensive and a more cost-effective procedure by using standard instruments and laparoscopy; (3) it offers a familiar view of the operation and manipulative movement of the instruments same as conventional laparoscopy. Because its technical difficulty stands between conventional laparoscopy and single-port surgery, the learning curve will be shorter for those who are interested in adopting this approach.

REFERENCES

1. Fader, A. N., Rojas-Espaillet, L., Ibeanu, O., Grumbine, F. C., & Escobar, P. F. (2010). Laparoendoscopic single-site surgery (LESS) in gynecology: a multi-institutional evaluation. *American journal of obstetrics and gynecology*, 203(5), 501-e1.
2. Behnia-Willison, F., Foroughinia, L., Sina, M., & McChesney, P. (2012). Single incision laparoscopic surgery (SILS) in gynaecology: feasibility and operative outcomes. *Australian and New Zealand Journal of Obstetrics and Gynaecology*, 52(4), 366-370.
3. Wong, F. W. S., & Lee, E. T. C. (2014). A modified three-port “hidden scars” surgical approach in gynecology: A surgeon's experience of an initial 72 cases. *Gynecology and Minimally Invasive Therapy*, 3(2), 43-46.
4. Wong, W. S. F. (2013). A safe optically guided entry technique using Endopath Xcel Trocars in laparoscopic surgery: A personal series of 821 patients. *Gynecology and Minimally Invasive Therapy*, 2(1), 30-33.
5. Lee, C. L., Huang, K. G., Jain, S., Wang, C. J., Yen, C. F., & Soong, Y. K. (2001). A new portal for gynecologic laparoscopy. *The Journal of the American Association of Gynecologic Laparoscopists*, 8(1), 147-150.
6. Park, J. Y., Kim, T. J., Kang, H. J., Lee, Y. Y., Choi, C. H., Lee, J. W., ... & Kim, B. G. (2013). Laparoendoscopic single site (LESS) surgery in benign gynecology: perioperative and late complications of 515 cases. *European Journal of Obstetrics & Gynecology and Reproductive Biology*, 167(2), 215-218.
7. Lee, E. T. C., & Wong, F. W. S. (2015). Small bowel obstruction from barbed suture following laparoscopic myomectomy—a case report. *International Journal of Surgery Case Reports*, 16, 146-149.