

Cornual Ectopic Pregnancy Medically Treated (About a Rare Case)

Adadi Hind*, Jayi SofiaSaleh, Mohamed Abderrahmane, Fdili Alaoui Fatima Zahra, Chacara Hekma, Boubou Meriem, Melhouf Moulay Abdelilah

Department of Obstetrics & Gynecology II, University Sidi Mohammed Benabdellah, Fes 30050, Morocco

DOI: [10.36348/sijog.2019.v02i08.002](https://doi.org/10.36348/sijog.2019.v02i08.002)

Received: 15.07.2019 | Accepted: 22.07.2019 | Published: 18.08.2019

*Corresponding author: Adadi Hind

Abstract

Ectopic pregnancy is a gynecological emergency that must always be considered in a woman of childbearing age because of her morbidity and mortality. Cornual pregnancies are rare and account for only 2% of the ectopic ones. Their management is poorly codified: the treatment is medical, when possible with methotrexate. The alternative is surgical with a significant risk of haemorrhage that can justify the use of an embolization and sometimes leading to a radical treatment that must be explained beforehand to the patient.

We report the case of a cornual pregnancy diagnosed on ultrasound in a patient of 36 years, nulliparous, followed in our training for abortive disease whose etiological record objectified resistance to activated protein C. The patient underwent pelvic pain of low intensity with minimal bleeding. The endovaginal ultrasound objectified: an empty uterus, in a normal size and with a regular cavitory line. We have evidenced a gestational sac around the left eccentric myometrium with no visible embryo, with yolk sac. There was no intraperitoneal fluid effusion. The diagnosis of cornual pregnancy was made on the ultrasound data coupled with the BHCG assay (9597 mIU / ml), and was supported by pelvic MRI. The patient received medical treatment successfully.

Cornual pregnancy is a rare ectopic pregnancy, difficult to diagnose, with risk of short-term haemorrhagic rupture and recurrence in the medium term. In the meantime, the availability of MRI in emergencies, endovaginal ultrasound coupled with the measurement of plasma BHCG allows early diagnosis. The therapeutic choice is mainly guided by the clinical picture, the treatment can be surgical or medical. However, in view of the rarity of this entity, the selection criteria of the patient candidates for this medical treatment remain poorly codified. Our case enriches the literature in this sense, and through it we insist on the diagnostic characteristics and the success and failure factors of the medical treatment.

Keywords: Ectopic pregnancy, cornual pregnancy, endovaginal ultrasound, medical treatment, methotrexate.

Copyright © 2019: This is an open-access article distributed under the terms of the Creative Commons Attribution license which permits unrestricted use, distribution, and reproduction in any medium for non-commercial use (Non-Commercial, or CC-BY-NC) provided the original author and source are credited.

INTRODUCTION

Ectopic pregnancy is defined as the implantation of the egg outside the uterine cavity. Its most common seat is the fallopian tube. Cornual pregnancy is a special ectopic pregnancy, as it is located in the part of the fallopian tube which penetrates the muscular layer of the uterus. It's unusual and accounts for less than 3% of the ectopic pregnancies [1]. The appearance of the cornual pregnancies is marked by the presence around the gestational sac of a myometrium that can allow its development until the 16th week of gestational age, thus exposing to a sudden rupture and a cataclysmic haemorrhage. Its prognosis is

therefore more serious than conventional tubal ectopic pregnancies and requires an early and accurate diagnosis before the stage of rupture [2] [3]. The rarity of this entity made the treatment not well codified and the option of medical treatment is only reported by a few authors.

We report a case of an ectopic cornual pregnancy diagnosed early and medically treated successfully.

OBSERVATION

Mrs. A. aged 36, treated for abortion disease (gravida 5, parity 0) and in whom the etiological assessment had objectified a mutation of the gene encoding factor V. Admitted in our training for 05weeks+04days amenorrhea associated with minimal bleeding and pain pelvic of low intensity.

General physical examination was evaluated as normal and patient was hemodynamically stable. (systemic blood pressure 110/70 mmHg and heart rate 83 /min). Slight vaginal bleeding as "spotting" and slight sensitivity without rebound or defense was determined. Serum β -hCG was measured as 9597 IU/L.

The realization of a supra-pubic and then endovaginal ultrasound has objectified the presence of a gestational sac with vesicle vitelline without visualized embryo, eccentric on the left, which comes barely in contact with the endometrial-myometrial junction zone surrounded by the myometrium and the trophoblastic crown; note that the distance: bag - cavity = 8mm; distance sac-serous = 5.7mm all evoking a pregnancy of pregnancy (Figure1). A pelvic MRI was performed showing the same appearance which supported the

diagnosis of early stage of corneal ectopic pregnancy. (Figure 2)

Given the patient's history, hemodynamic stability, and ability to follow strict supervision, hospitalization was indicated to initiate medical therapy with methotrexate at a dose of 50mg/m². The first dose of methotrexate injected was 89.5 mg intramuscular (IM) in the absence of hepatic and renal contraindications.

Biological and ultrasound monitoring for signs of surgical treatment:

- D0: injection of the first dose of methotrexate
- D4: Clinical evaluation without anomaly
- D7: Patient always asymptomatic - BHCG = 14,222 IU / L increased more than 15% - the decision was to administrate a second injection of methotrexate with strict supervision.

A control at day 14 (7 days after the 2nd injection) a reduction of more than 15%. Then Weekly surveillance was established, showing a decrease in BHCG level that went negative after 9 weeks after the 2nd injection of Methotrexate.

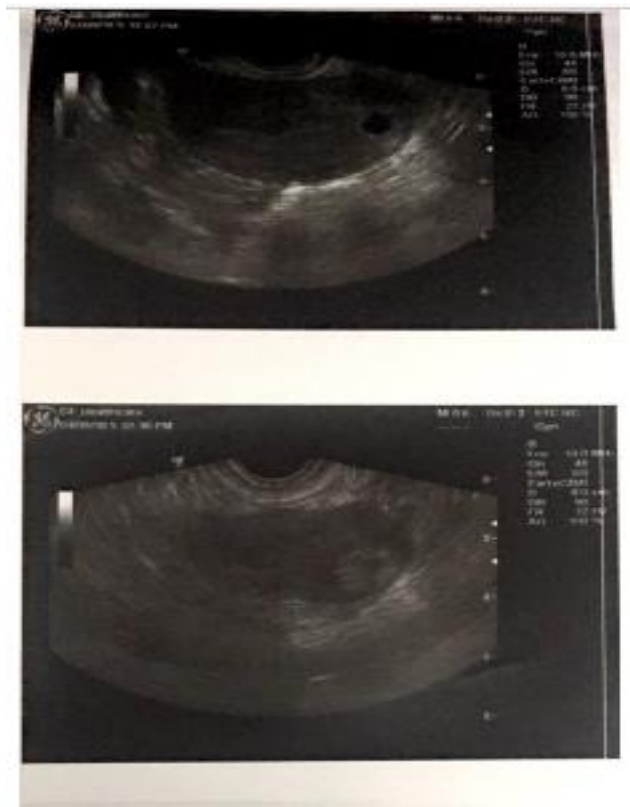


Fig-1: Complex cystic mass with an echogenic rim compatible with a gestational sac intimately related to the uterus - myometrium completely surround the gestational sac.

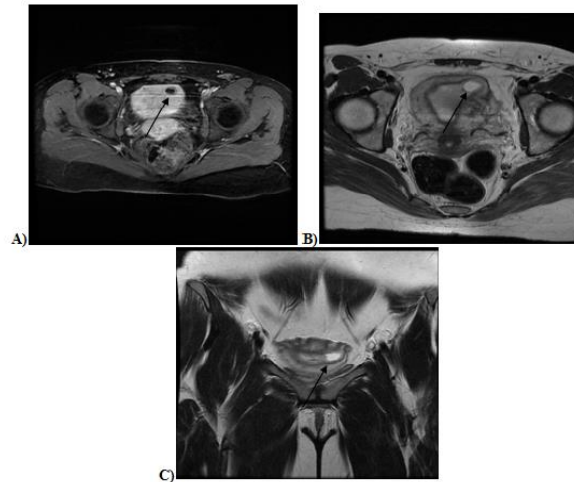


Fig-2: axial view T1 (A) axial view T2 (B) and coronal view T2 (C) of the cornual ectopic pregnancy in MRI.

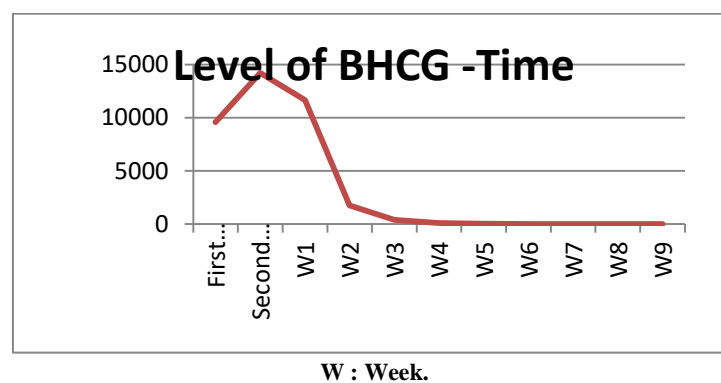


Fig-3: Evolution of BHCg level after administration of methotrexate

DISCUSSION

Cornual pregnancy is an ectopic one with unusual localization. It's rare and respects less than 3% of ectopic pregnancies, according to statistics [4]. Interstitial, angular and cornual pregnancies are often classified under the same nomination but each one has its own definition and own prognosis. In the strict sense of the term, interstitial pregnancy is developed in the intra-myometrial portion of the fallopian tube which is a canal of 0.7mm diameter and about 10 to 20mm of length. The gestational sac is placed laterally to the round ligament. Angular pregnancy develops at the tubal ostium precisely at the bottom of the uterine horn. Opposite to the normal pregnancy, it's situated in the axis of the round ligament, and the risk of rupture here is rare in the case where this implantation is inside the endometrial cavity. Histologically, the placental villi are inserted at the level of the wall of the uterine horn, the interstitial portion is empty that way. In the literature, we find that the presence of fibromatous uterus is a factor of risk of the angular pregnancy. The cornual term is defined initially as a pregnancy placed at the horn of a malformed uterus. Some of the authors regrouped the cornual pregnancy under that definition: the development of trophoblastic tissue on the remaining stump of a removed fallopian tube. On the contrary, the Anglo-Saxon authors expanded this definition to all the interstitial pregnancies [5],[6].

A lot of factors are recognized, mainly smoking, pelvic infections and antecedent of an ectopic pregnancy. Maternal age, the use of medically assisted procreation techniques, antecedent of spontaneous abortion are also linked to an increase in the number of ectopic pregnancies but this could be also due to the common risk factors to these pathologies [6].

Ultrasound diagnosis of cornual pregnancies is well known. According to the data of the literature, the cornual pregnancy gives an abnormally eccentric egg sac image, surrounded by myometrium and protruding on the right or the left of the uterine fundus [3], [5], this aspect was typically found in our patient. The ovum sac remains in contact with the uterine lining, unlike the isthmic pregnancy separated from it by the myometrium [6], [7]. The outer contours of the uterus and the endometrium should be closely followed to distinguish it from a normal pregnancy in a simple angular position or on a double uterus (cervical or septate unicorn bicorne). All authors agree that the endovaginal route is the best way to explore cornual pregnancies [5], [7]. According to Ackermann [6] the endovaginal ultrasound is quite specific (88 to 93%) but its sensitivity, about 40%, is bad. Magnetic resonance imaging (MRI) is the most accurate alternative for the positive and topographic diagnosis of rare ectopic

pregnancies forms; it is great help in better locating ectopic pregnancy and better characterizing it, which consequently makes it possible to better adapt the therapeutic management of these patients [3].

The mortality rate of cornual ectopic pregnancy is estimated at between 2% and 2.5%, which is twice as much as tubular pregnancy. The propensity of the horn to be distended would explain a later symptomatology and a risk of rupture increased, unlike tubal localisation, there is no score to determine the success of a medical treatment in cornual pregnancies [8]. Thus, his treatment whether medical or surgical is not codified. It is guided by both the hemodynamic status of the patient and the experience of the medical team. However, the occurrence of a corneal rupture, which may be life-threatening for the patient with massive hemoperitoneum, as well as several reported cases of persistent trophoblastic tissue with uterine rupture during a subsequent pregnancy [9]. The recommendations of the French National College of Gynecologists-Obstetricians conclude to the possibility of using methotrexate in case of cornual pregnancy, with a low level of evidence [10]. On the other hand, no number of injection, dose, or the site of administration is recommended and no consensus exists on the limit HCG and / or the presence of cardiac activity indicative of surgical treatment. The main risk of this strategy is the failure of medical treatment and the occurrence of a cornual rupture with massive hemoperitoneum.

In the study by Nikodijevic K, et al, nineteen patients had a cornual pregnancy, about 3.79% of all the ectopic pregnancies (the incidence of ectopic pregnancy, all locations combined, was 2.95 per 100 live births) (507 / 17 187). (19/507) [11].

Methotrexate treatment was performed in 32% (6/19) of the cases: 02 patients received an intramuscular injection of methotrexate, 03 received an in situ injection of Methotrexate and only one patient benefited from an injection of Methotrexate in both sites (intramuscular and in situ).

One patient had a medical treatment failure (she received during coelioscopic in situ injection for a

20 mm cornual pregnancy with 17,076 IU / L HCG and cardiac activity present) and underwent surgery. No rupture occurred during the drug treatment with intramuscular injection [11].

In our case, we note the success of the chosen medical treatment given the clinical condition of the patient, and crowned by a success after 02 injections of Methotrexate in intramuscular site at a dose of 50 mg / m². The cases reported in the methotrexate failure literature are much less numerous than its success, probably because of publication bias. In a case series literature review, Lau and Tulandi reported 2 cases of cornual rupture after intramuscular injection of methotrexate that occurred with initial HCG greater than 10,000 IU / L [12].

Tulandi and Al-Jaloudi, in a series of 32 cornual ectopic pregnancies, reported 3 cases of methotrexate failure including two for cornual rupture (1 patient had HCG at 13,420 IU / L) without details however regarding the site of administration and the level of bhcg of other patients [13]. An exhaustive analysis of the failures of medical treatment with the occurrence of a rupture cornual in the series mentioning in each case the rate of HCG and the presence or absence of a cardiac activity remains inconclusive [14]. It seems difficult to predict the occurrence of haemorrhagic rupture although this is reported mainly in the case of high BHCG (greater than 10,000 IU / L in 12 out of 13 cases with or without cardiac activity). Nevertheless, Hirsch et al. recently compared 12 successes and 5 failures of methotrexate [15]. The dose of methotrexate administered (1 mg / kg / day) was either a single IM injection or 4 IM injections. No differences were found in HCG levels, the presence of cardiac activity or the size of the sac, however, it did not analyze single-dose or multidose protocol). Tanaka et al. reported a series of 33 patients successfully treated with methotrexate (bolus 100 mg then 200 mg IV over 12 h) with cornual pregnancies with present cardiac activity and / or HCG very high (up to 106 634 IU / L) (15). In the Jermy *et al.* Series, 16 of 17 patients were successfully treated with methotrexate (50 mg / kg IM), 4 of whom had cardiac activity.

Table -1: Occurrence of a hemorrhagic corneal rupture after treatment with methotrexate

Authors	HCG / AC		Number of cases
Benifla et al. (16)	43 000 et AC+	IS	1/15
Fernandez et al. (8)	43 000 et AC+	IM	1/6
Jermy et al. (17)	17 398 et AC -	IM	1/20
Andres et al. (18)	6193 et AC+	IS	1/3
Brown et al. (19)	19 000 et AC – 12 241 et AC+	IS	2/18
Tang et al. (20)	63 000 et AC+	IS	1/11
Cassik et al. (21)	> 10 000 et AC+	1 IS et 2 IM	3/28

IM: intramuscular; IS : in situ ; AC : cardiac activity

CONCLUSION

Cornual pregnancy, although rare, is an unusual ectopic pregnancy with a very serious

prognosis. The realisation of endovaginal ultrasound can allow its early discovery. The therapeutic choice should be guided mainly by the clinical picture which is to compare, in case of stable situation, the HCG rate and the ultrasound data, in order to choose between a medical treatment by and surgical one. The medical treatment is less invasive but remains not codified because of the rarity of the cases that benefited from it. For this fact our case comes to enrich the literature, and through it we draw the attention to the interest of the early diagnosis in the improvement of its management.

REFERENCES

- Ardaens, Y., Guérin, B., Perrot, N., & Legoeff, F. (2003). Apport de l'échographie dans le diagnostic de la grossesse extra-utérine.
- Jourdain, O., Fontanges, M., Schiano, A., Rauch, F., & Gonnet, J. M. (2008). Prise en charge des autres ectopies annexielles (cornuale, interstitielle, angulaire, ovarienne).
- Poncelet, É., Leconte, C., Fréart-Martinez, É., Laurent, N., Lernout, M., Bigot, J., ... & Lucot, J. P. (2009). Aspect échographique et IRM de la grossesse extra-utérine. *Imagerie de la Femme*, 19(3), 171-178.
- Timor-Tritsch, I. E., Monteagudo, A., Matera, C., & Veit, C. R. (1992). Sonographic evolution of cornual pregnancies treated without surgery. *Obstetrics and gynecology*, 79(6), 1044-1049.
- Ackerman, T. E., Levi, C. S., Dashefsky, S. M., Holt, S. C., & Lindsay, D. J. (1993). Interstitial line: sonographic finding in interstitial (cornual) ectopic pregnancy. *Radiology*, 189(1), 83-87.
- Fisch, J. D., Ortiz, B. H., Tazuke, S. I., Chitkara, U., & Giudice, L. C. (1998). Medical management of interstitial ectopic pregnancy: a case report and literature review. *Human reproduction (Oxford, England)*, 13(7), 1981-1986.
- Fernandez, H., Lelaidier, C., Thouvenez, V., & Frydman, R. (1991). The use of a pretherapeutic, predictive score to determine inclusion criteria for the non-surgical treatment of ectopic pregnancy. *Human Reproduction*, 6(7), 995-998.
- Downey, G. P., & Tuck, S. M. (1994). Spontaneous uterine rupture during subsequent pregnancy following non-excision of an interstitial ectopic gestation. *BJOG: An International Journal of Obstetrics & Gynaecology*, 101(2), 162-163.
- Marret, H., Fauconnier, A., Dubernard, G., Misme, H., Lagarce, L., Lesavre, M., ... & Rabishong, B. (2015). Evidence-based evaluation and expertise of methotrexate off label use in gynaecology and obstetrics: work of the CNGOF. *Journal de gynécologie, obstétrique et biologie de la reproduction*, 44(3), 230-236.
- Nikodijevic, K., Bricou, A., Benbara, A., Moreaux, G., Nguyen, C., Carbillon, L., ... & Boujenah, J. (2016). Grossesse extra-utérine cornuale: prise en charge, fertilité ultérieure et devenir obstétrical. *Gynécologie Obstétrique & Fertilité*, 44(1), 11-16.
- Lau, S., & Tulandi, T. (1999). Conservative medical and surgical management of interstitial ectopic pregnancy. *Fertility and sterility*, 72(2), 207-215.
- Tulandi, T., & Al-Jaroudi, D. (2004). Interstitial pregnancy: results generated from the Society of Reproductive Surgeons Registry. *Obstetrics & Gynecology*, 103(1), 47-50.
- Hirsch, L., Krissi, H., Ashwal, E., From, A., Wiznitzer, A., & Peled, Y. (2014). Effectiveness of medical treatment with methotrexate for interstitial pregnancy. *Australian and New Zealand Journal of Obstetrics and Gynaecology*, 54(6), 576-580.
- Tanaka, K., Baartz, D., & Khoo, S. K. (2015). Management of interstitial ectopic pregnancy with intravenous methotrexate: an extended study of a standardised regimen. *Australian and New Zealand Journal of Obstetrics and Gynaecology*, 55(2), 176-180.
- Benifla, J. L., Fernandez, H., Sebban, E., Darai, E., Frydman, R., & Madelenat, P. (1996). Alternative to surgery of treatment of unruptured interstitial pregnancy: 15 cases of medical treatment. *European Journal of Obstetrics & Gynecology and Reproductive Biology*, 70(2), 151-156.
- Fernandez, H., Lelaidier, C., Thouvenez, V., & Frydman, R. (1991). The use of a pretherapeutic, predictive score to determine inclusion criteria for the non-surgical treatment of ectopic pregnancy. *Human Reproduction*, 6(7), 995-998.
- Andrés, M. P., Campillos, J. M., Lapresta, M., Lahoz, I., Crespo, R., & Tobajas, J. (2012). Management of ectopic pregnancies with poor prognosis through ultrasound guided intrasacral injection of methotrexate, series of 14 cases. *Archives of gynecology and obstetrics*, 285(2), 529-533.
- Brown, D. L., Felker, R. E., Stovall, T. G., Emerson, D. S., & Ling, F. W. (1991). Serial endovaginal sonography of ectopic pregnancies treated with methotrexate. *Obstetrics and gynecology*, 77(3), 406-409.
- Tang, A., Baartz, D., & Khoo, S. K. (2006). A medical management of interstitial ectopic pregnancy: A 5-year clinical study. *Australian and New Zealand journal of obstetrics and gynaecology*, 46(2), 107-111.
- Cassik, P., Ofili-Yebovi, D., Yazbek, J., Lee, C., Elson, J., & Jurkovic, D. (2005). Factors influencing the success of conservative treatment of interstitial pregnancy. *Ultrasound in Obstetrics and Gynecology: The Official Journal of the International Society of Ultrasound in Obstetrics and Gynecology*, 26(3), 279-282.