

Rudimentary Uterine Horn Pregnancy; Pre-rupture Diagnosis and Management: Case Report

Elham Al Mardawi, Rawda Al Bahyan, Tahira Jamil Choudhary, Alaa Al Olayet, Aida Bismar, Thamer Al Ghamdi, Ohoud Al Yousef, Ahmad Talal Chamsi*

Department of Obstetrics and Gynecology, Security Forces Hospital, Riyadh, Saudi Arabia

*Corresponding author: Ahmad Talal Chamsi

| Received: 01.03.2019 | Accepted: 03.03.2019 | Published: 30.03.2019

DOI: [10.36348/sijog.2019.v02i03.002](https://doi.org/10.36348/sijog.2019.v02i03.002)

Abstract

Introduction: Rudimentary horn is a developmental anomaly of the uterus. Pregnancy in a rudimentary horn is rare. The Diagnosis of the rudimentary horn pregnancy is very difficult and needs high index of suspicion. **Case:** We present a case of pregnancy in a non-communicating rudimentary horn that was difficult to diagnosis in the 1st presentation. The diagnosis was suspected when the case did not respond to the medical termination of pregnancy by misoprostol; and also by mechanical methods. Following that a suspicion of an abnormally located pregnancy was made and confirmed by radiology modalities. Patient had surgical resection of the rudimentary horn. **Conclusion:** Despite recent advances in ultrasound, the diagnosis of pregnancy in the rudimentary horn remains difficult, and high index of suspicion is needed in these cases.

Keywords: Rudimentary Horn, Pregnancy, Abortion, Ectopic.

Copyright © 2019: This is an open-access article distributed under the terms of the Creative Commons Attribution license which permits unrestricted use, distribution, and reproduction in any medium for non-commercial use (Non-Commercial, or CC-BY-NC) provided the original author and source are credited.

INTRODUCTION

Rudimentary horn pregnancy is a rare obstetric entity and carries grave consequences for the mother and fetus. The diagnosis and management may pose some problems. We report our experience in diagnosing and managing a case of missed miscarriage in a rudimentary horn.

CASE DESCRIPTION

A 28-year old lady, G3 P2 L2, GA= 21 weeks by LMP but 15 weeks by ultrasound, diagnosed to have a missed miscarriage, referred to Security Forces Hospital (SFH) in Riyadh after a failed trial of medical TOP for further assessment and management. Her 1st pregnancy ended with full term vaginal delivery, the 2nd was full term cesarean section for fetal heart rate abnormalities on CTG.

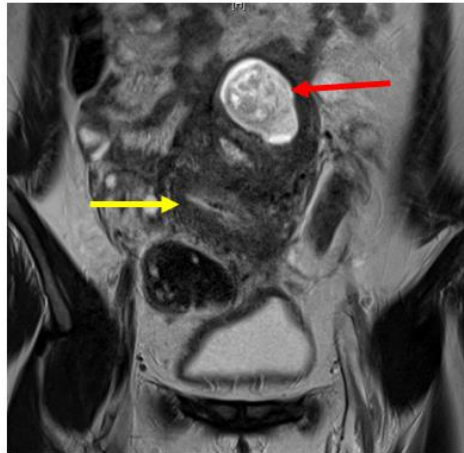
In this pregnancy, she was followed in Afif – a small City in Saudi Arabia, till she was diagnosed to have a missed miscarriage, For that, she had a trial of medical TOP but failed and was referred to SFH in Riyadh.

Ultrasound was done and showed a single non viable intrauterine pregnancy going with 15 weeks, and was to start medical Termination of Pregnancy (TOP)

by misoprostol 100 microgram vaginally every 6 hours for 4 doses. The Medical TOP was not successful. The patient was counseled for another trial, which was completed but with no response again. The cervix was closed and no bleeding. At that time, the decision was to discharge her and re admit after 2 weeks.

During The 2nd admission She received another course of misoprostol of 4 doses, 200 microgram each. In spite of that, no progress was observed. Mechanical dilatation was tried using Laminaria tent, 2 rods were inserted in the cervix (4 mm each). The other day, the cervix was 1 cm dilated so 3 rods of 5 mm size were used and kept for 24 hours. Another form of Mechanical dilatation was used by Intracervical Foly's Cather. All modalities failed.

Ultrasound was repeated and it showed a suspicious biornuate uterus with a missed miscarriage in the left horn. An MRI was done and showed a Bicornuate uterus, Right horn is empty and communicating with the cervix, Left horn is the gravid one with the dead fetus inside (Picture-1). No renal abnormalities. The condition was explained to the couple, surgical option was discussed, and patient taken for laparotomy and excision of left uterine horn.



Picture-1: Axial T2-weighted magnetic resonance imaging shows a gestational sac surrounded by thin myometrial tissue on the left (red arrow) and an empty uterus on the right side (yellow arrow). No communication was seen between the uterus and the cavity that contained the fetus, confirming the diagnosis of a rudimentary horn pregnancy

Patient underwent laparotomy through a mid-line incision and the findings were:

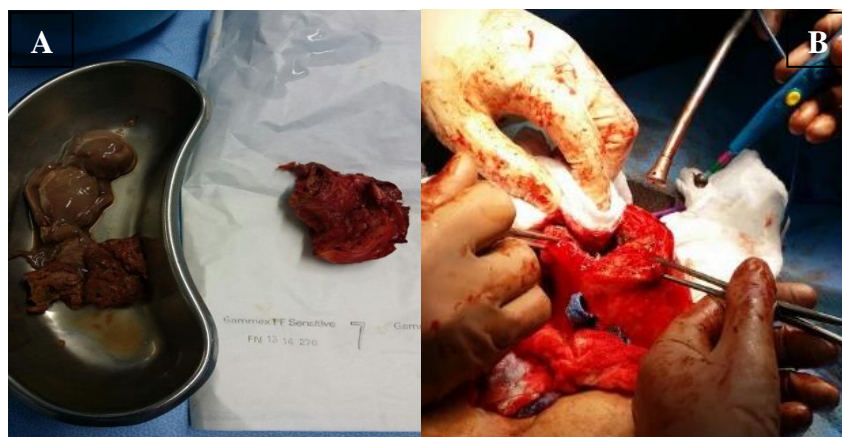- Moderate intra- abdominal adhesions
- Dextro-rotated uterus with the right tube facing anterior
- No clear cleavage could be identified between the two cavities

Adhesions were released, and the left horn was opened in the anteroposterior diameter, the fetus was delivered, placenta was removed and the left horn was excised. It was attached to the right horn by a thick fibromuscular band with no communication between them. The dead space was closed in three layers and the

estimated blood loss was around 300 ml (Picture-2). All specimens sent to histopathology for analysis and Reported as were :

- Uterine contents: Products of Conception, an Embryo with CRL of 8.5cm
- Rudimentary Left Horn of Uterus: Endometrium and Myometrium consistent with rudimentary horn chowing chorionic villi attached to Endometrium

Patient had a smooth post-operative course without complications. Discharged home on day 2 post op on combined contraceptive pills and given follow up in 3 months.



Picture-2: A: Left Rudimentary Uterine Horn after Excision. B: Product of Conception

Patient was seen after 3 months when ultrasound was repeated and showed: normal size uterus with a small hypoechoic mass towards the left horn. Patient was advised to continue on OCP.

DISCUSSION

Unicornuate uterus with a rudimentary horn is a mullerian duct malformation. The incidence of mullerian duct malformations in the general population

is estimated to be 4.3% while that of unicornuate uterus is about 0.4% [1]. Rudimentary horn pregnancy occurs in approximately 1/76 000 to 1/150 000 pregnancies [2].

The usual outcome of rudimentary horn pregnancy is rupture in second trimester in 90% of cases with fetal demise [3], however cases of pregnancy

progressing to the third trimester and resulting in a live birth after caesarean section has been documented [4].

It is recommended by most that immediate surgery be performed whenever a diagnosis of pregnancy in a rudimentary horn is made even if unruptured [5]. However, conservative management until viability is achieved has been advocated in very select cases with larger myometrial mass, if emergency surgery can be performed anytime and the patient is well-informed [6].

In the case of Mrs. T, the diagnosis was not suspected on the 1st ultrasound scan therefore termination of pregnancy was attempted. And when the diagnosis was suspected clinically, ultrasound scan in addition to other methods of confirmation such as MRI helped a lot

Although the incidence of rudimentary horn pregnancy is relatively small, the risk of serious maternal morbidity and mortality is high. Early prerupture diagnosis is therefore very important. The following criteria have been suggested by Tsafri *et al.*, for sonographic diagnosis of rudimentary horn pregnancy [7]: (1) pseudopattern of an asymmetrical bicornuate uterus, (2) absent visual continuity between the cervical canal and the lumen of the pregnant horn, and (3) the presence of myometrial tissue surrounding the gestational sac.

The attachment of the rudimentary horn to the main uterus varies from a fibro-muscular band to an extensive fusion between the two horns where there is no external separation between them. The former was the type of attachment found in our case.

CONCLUSION

This case report has highlighted the need for high level of suspicion for this rare but very important complication of pregnancy.

Informed Consent was obtained from the patient and her husband

Conflict of Interests and Funding Sources Statement: None

Acknowledgment: None

Authors' contributions

All authors have participated in Manuscript Development and Patient Management.

REFERENCES

1. Grimbizis, G. F., Camus, M., Tarlatzis, B. C., Bontis, J. N., & Devroey, P. (2001). Clinical implications of uterine malformations and hysteroscopic treatment results. *Human reproduction update*, 7(2), 161-174.
2. Ural, S. H., & Artal, R. (1998). Third-trimester rudimentary horn pregnancy. A case report. *The Journal of reproductive medicine*, 43(10), 919-921.
3. Liu, M. M. (1994). Unicornuate uterus with rudimentary horn. *International Journal of Gynecology & Obstetrics*, 44(2), 149-153.
4. Shin, J. W., & Kim, H. J. (2005). Case of live birth in a non-communicating rudimentary horn pregnancy. *Journal of Obstetrics and Gynaecology Research*, 31(4), 329-331.
5. Jayasinghe, Y., Rane, A., Stalewski, H., & Grover, S. (2005). The presentation and early diagnosis of the rudimentary uterine horn. *Obstetrics & Gynecology*, 105(6), 1456-1467.
6. Nahum, G. G. (2002). Rudimentary uterine horn pregnancy. The 20th-century worldwide experience of 588 cases. *The Journal of reproductive medicine*, 47(2), 151-163.
7. Tsafirir, A., Rojansky, N., Sela, H. Y., Gomori, J. M., & Nadjari, M. (2005). Rudimentary horn pregnancy: First-trimester prerupture sonographic diagnosis and confirmation by magnetic resonance imaging. *Journal of Ultrasound in Medicine*, 24(2), 219-223.