

Phyllode Tumors: Breast Tumors with a High Potential for Recurrence- About Two Cases**Mouna Ejjiyar^{*}, Mehdi ElGueouatri, Mehdi Sahibi, Abdelkoddous Bhihi, Imane Yafi, Mehdi Mahrouch, Moulay Driss Elamrani, Yassine Benchamkha**

Plastic, Restorative, Aesthetic and Burned Surgery Department, Mohammed VI University Hospital, Marrakech, Morocco

Case Report***Corresponding author***Mouna Ejjiyar***Article History***Received: 19.11.2018**Accepted: 28.11.2018**Published: 30.12.2018*

Abstract: Phyllodes tumors of the breast are rare fibroepithelial tumors in their malignant form, the gravity lies in high risk of local recurrence. We report two observations of patients admitted for the management of local recurrence of phyllode breast tumor. The average age of our patients was 39 years old. The size of the tumor ranged from 10 cm to 30 cm in diameter, with a localization exclusively on the right. Surgical management consisted of an enlarged tumor resection, followed by radiotherapeutic complement. Histologically, it was a phyllode tumor initially benign with slowly progressive evolution, to a phyllode sarcoma at one patient, and to a liposarcoma in the other. The evolution towards a malignant transformation can be explained in both cases by incomplete previous excisional gestures. This underlines the importance of early diagnosis and surgical management responding to oncological rules.

Keywords: Phyllode tumors, breast, local recurrence, carcinologic excision.

INTRODUCTION

Phyllode tumors of the breast (formerly called cystosarcomas phyllodes) are rare. They represent 0.3 to 1% of primary mammary tumors and 2.5% of fibroepithelial tumors and are most often benign (60 to 70%) [1]. These tumors can occur at any age, young women than in older women, with a frequency spike among women in genital activity between 35 and 50 years old, their etiopathogenesis being poorly known.

The main treatment is wide surgical excision with safety margins of at least 1 cm, which is the key to local and general prognosis. The main evolutionary risk of benign phyllodes tumors is that of local recurrence, that of sarcomas being, of course, haematogenous metastatic dissemination. The purpose of this work is to report, through two observations, the diagnostic difficulties, the evolved character and the severity of some tumors that are related to their malignancy and the risk of local recurrence, and finally to highlight the therapeutic difficulties encountered.

METHODS

We report the observations of two patients hospitalized and operated at the plastic, restorative, aesthetic and burned surgery department at the Mohammed VI University Hospital of Marrakech, during the period between January 2014 and December 2017. There were two patients admitted for management of local recurrence of phyllode breast tumor.

Observation 1

38-year-old female patient, married and mother of 6 children, low socioeconomic level, without medical or surgical antecedent, having a history of gynecological obstetrics menarche at the age of 13 years old, six deliveries by low voice, the last one 15 months before hospitalization, and breastfeeding for three months for each child. The interrogation does not found no similar case in the family. The history of the disease was three years before admission into our service, by the appearance of a nodule of the right breast gradually increasing in size, for which the patient had undergone a first resection with a histology of a phyllode tumor. The evolution was marked by the reappearance, two years later, of multiple nodules of the same breast, having indicated the achievement of a right mastectomy. Four months later, a second parietal recurrence leads to another time of tumor excision, whose anatomopathological study reveals a grade III malignant phyllode tumor, with lesional lateral and deep limits. The patient was sent to us after a third recurrence, for an enlarged excision. At the general examination, we found a patient conscious, in quite good general condition, cachectic, with slightly

discolored conjunctiva. Examination of the anterior thoracic wall found a right voluminous mass ulcerobudding latero-thoracic about 30 cm long axis, fixed in relation to the superficial and deep planes. The examination of contralateral breast was normal and axillary lymph node areas were free. The rest of the clinical examination found no sign of a secondary. On

the radiographical plan, thoracic computed tomography revealed an enormous mass of the pectoro-axillary soft tissues, measuring 31cm x 24cm x 18cm, coming into contact with the axillary pedicle at the top and ribs in depth, without lysis or bone erosion, and without endothoracic extension (Figure-1).

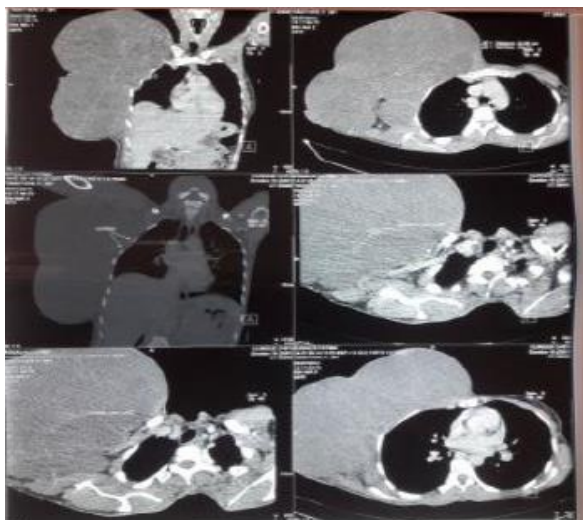


Fig-1: Thoracic computed tomography image showing an enormous mass of pectoro-axillary soft tissues of 31cm long axis

In addition, the general extension assessment did not reveal any secondary location. The patient thus benefited from an enlarged tumor resection with 3 cm

margins of safety laterally, reaching deep to the ribs. After budding (Figure-2), the loss of substance was secondarily covered by a thin skin graft (Figure-3).

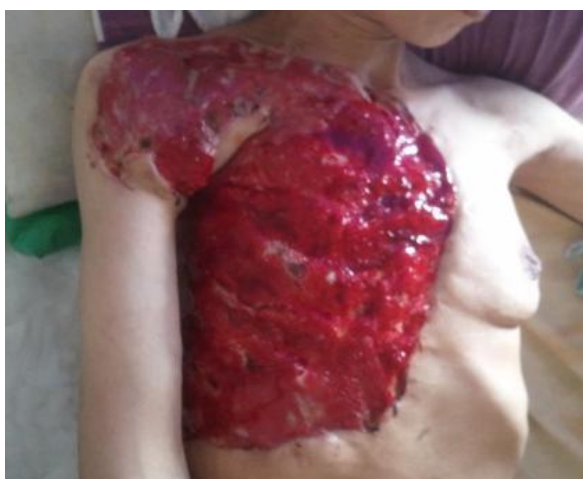

Fig-2: Appearance after budding of enlarged post-excisional loss of substance

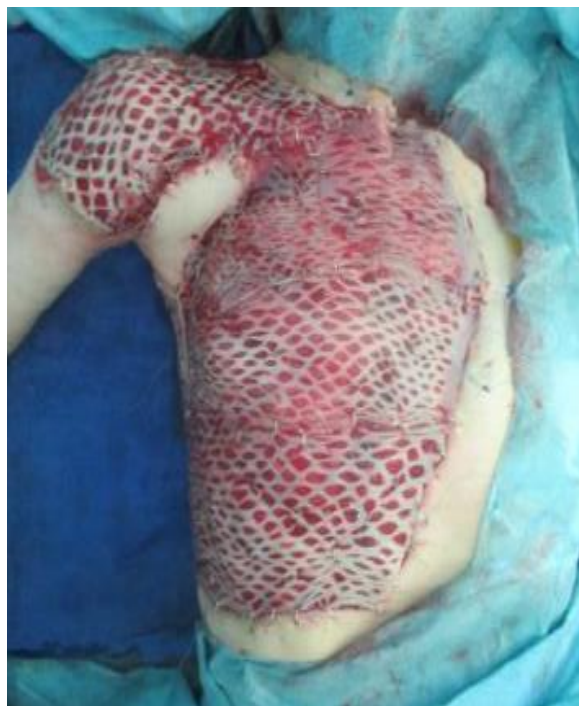

Fig-3: Thin skin graft coverage

The anatomopathological study of the operative specimen revealed tumor transformation into myxoid sarcoma compatible with liposarcoma of complete exeresis. The patient was directly addressed in oncology to benefit from a therapeutic complement by radiotherapy.

Observation 2

48-year-old female patient, single, nulliparous, low socioeconomic, no medical or surgical antecedent, having as a gynecological-obstetric history a menarche to the age of 12 and regular cycles. Research in family history does not find similar case in the family. The history of the disease began 8 years before admission to our service, while the patient was only 40 years old. The beginning of the symptomatology was marked by the discovery of a right breast nodule gradually

increasing in size, for which a simple biopsy followed by a straight mastectomy was performed highlighting a voluminous phyllode tumor measuring 10 cm in diameter, without evidence of malignancy. The evolution has been marked, five years later, by the occurrence of a local recurrence, the anatomopathological study of excision specimen revealed a grade II phyllode tumor, for which the patient benefited from 30 radiotherapy sessions. Two years later, a second parietal recurrence is noted, with in the biopsy this time a phyllode sarcoma. The patient was sent to us for an enlarged tumor excision. At the general examination, there was a conscious patient, in good general condition. Examination of the right anterior chest wall found a large subcutaneous mass fixed to the anterior pillar of the axillary hollow without palpable lymphadenopathy (Figure-4).

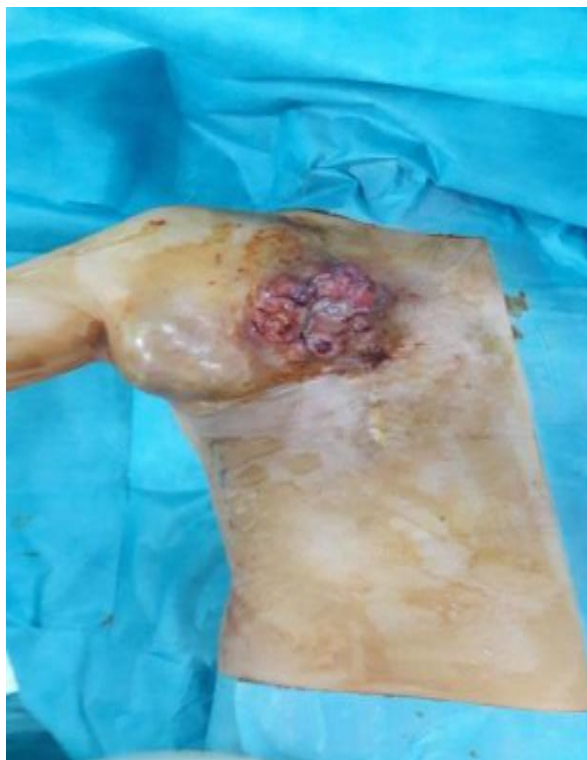

Fig-4: Bulky subcutaneous recurrence of a phyllode tumor, fixed to the anterior pillar of the axillary hollow

The rest of the general exam did not find any signs in favor of a secondary location. Thoracic MRI has put in evidence a 12 cm x 8 cm right parieto-axillary bud bursting tumor in contact with the axillary pedicle, without secondary localization. The patient

thus benefited from an enlarged tumor excision with lateral margins of safety at 3 cm reaching deep to the ribs and laying bare the axillary pedicle (Figure-5) which was covered by a large latissimus dorsi muscle flap (Figure-6).

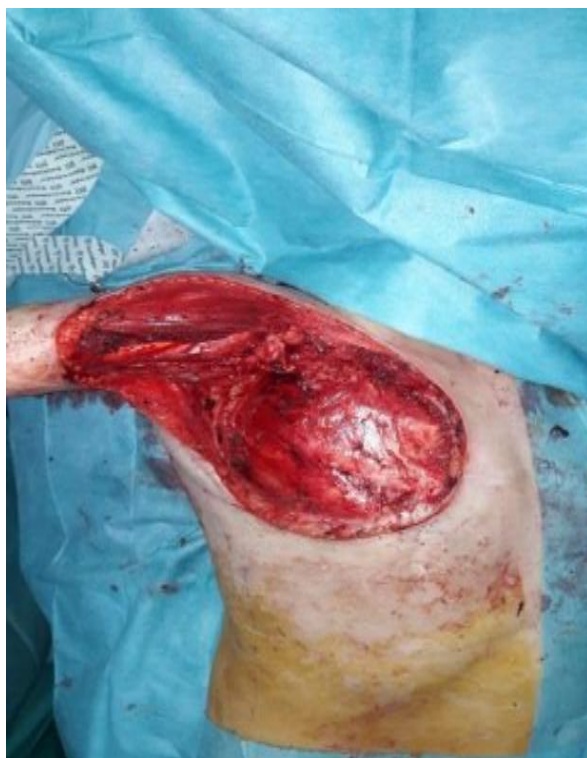

Fig-5: Enlarged tumor excision exposing the axillary pedicle

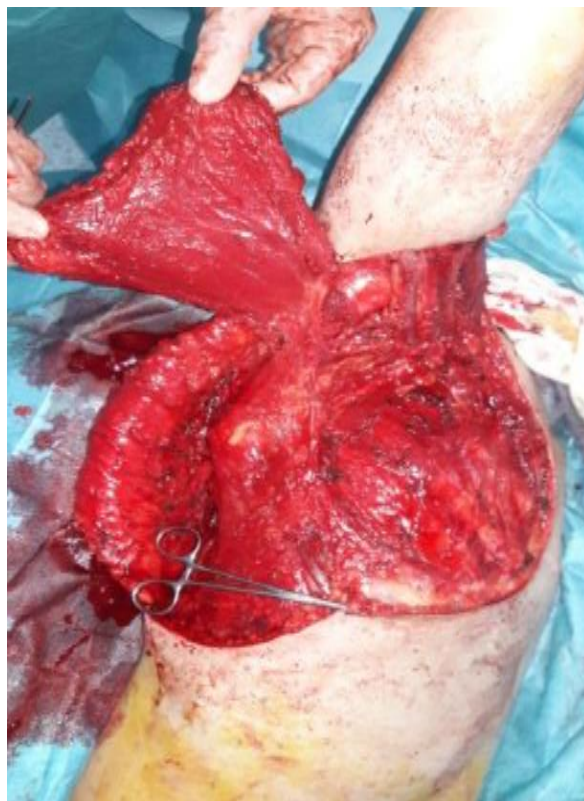

Fig-6: Coverage of the axillary pedicle by a latissimus dorsi muscle flap

Secondarily, the residual loss of substance was covered by a thin skin graft. After healing, the patient was referred to oncology to continue her sessions of radiotherapy. After six months of evolution, a control MRI revealed pulmonary nodules as well as bone lesions at the humeral level.

RESULTS

The mean age of our patients at the time of diagnosis of the phyllode tumor was 39 years old (38 and 40 years old). The notion of parity or not does not seem to have any impact on the evolution of this pathology, since one of our patients was multiparous, while the other was nulliparous. The tumor size ranged from 10 cm to 30 cm in diameter, with a localization exclusively at right. The treatment in plastic surgery, undertaken after two repeated local recurrences in both patients consisted of enlarged tumor resection with lateral margins of safety to 3 cm, then a skin graft, followed by a radiotherapy supplement. On the histological plan, it was an initially benign phyllode tumor progressive to a phyllode sarcoma in one patient, and to a liposarcoma in the other. Pulmonary and bone secondary sites were noted in a single patient. The evolution to a malignant transformation can be explained in both cases by previous incomplete excision gestures. The long-term evolution is not known, the two patients being lost of view.

DISCUSSION

Phyllodes breast tumors are rare fibroepithelial tumors of the breast whose incidence is very weak. They were described for the first time by Muller in 1938 as " phyllode cystosarcoma ". There is at this moment a discrepancy between their initial denomination, their clinical appearance may vary from a mild form localized to a metastatic malignant form. It was in 1981 that the World Health Organization adopted the term phyllodes tumors in order to remove the confusion between the malignant and benign forms. This term then appears as the most appropriate to the detriment of that of phyllode cystosarcoma. The WHO classification admits currently the existence of 3 histological grades: grade 1 or benign phyllode tumor, grade 2 or borderline phyllode tumor, and grade 3 or malignant phyllode tumor [2].

It is an almost exclusively feminine pathology. The age of onset of this tumor is between 35 and 55 years old, which is on average about 10 years later than the appearance of a fibroadenoma. He was 33.4 years old in the Sabban *et al.*, series [1], 34.1 years in the Benchiba *et al.*, series [3], and 37 years in Fathallah *et al.*, series [4]. An exceptional location in a 12-year-old girl was nonetheless reported by Issara *et al.*, [5], and a rare case of malignant phyllode tumor of the breast during pregnancy has been reported by Maitrot-Mantelet *et al.*, [6]. In our series, the average age of onset was 39 years old. The location of the tumor was

exclusively on the right in our series, as well as in that of Sabban *et al.*, [1], unlike at Fakhir *et al.*, [7] where the location on the left was predominant. Clinically the phyllode tumor is either in the form of a small, rounded nodule dented or polylobed, mobile [8], firm, circumscribed evoking a fibroadenoma or a cyst; either in form a voluminous tumor taking all the breast, with distension of the skin, collateral circulation, skin ulceration and muscle fixation, with a size varying from 8 cm in the series of Fakhir *et al.*, [7], at 10 cm in the series of Silas *et al.*, [9], arriving up to 13 cm in the series of Khabouze *et al.*, [10]. In our series, the tumor recurrence reported in Observation 1 had reached 30 cm diameter. Histologically, they correspond to a fibroepithelial tumor similar to fibroadenoma but with a predominant component of the connective tissue. So, these are particular tumors mixed by their histology which describes a lesion spectrum ranging from phyllodes tumors benign to malignant and borderline (intermediate malignancy) forms, and their evolution during local and metastatic recurrences with a possible shift towards a form histologically more aggressive [11, 12]. The diagnosis and histopronostic of phyllode tumor are established during the pathological analysis of the surgical specimen, where they present classically to the cup, a foliated structure hence their phyllode name (in Greek: phyllos means sheet) [3]. The anatomopathological diagnosis of phyllode tumor is based on the predominance of the stromal contingent with a heterogeneous distribution, an intra-canalicular architecture predominant and uneven distribution of epithelial structures on the examined surface tumor. The benign forms being the most frequent as evidenced by the series of Fathallah *et al.*, [4] as well as that of Khabouze *et al.*, [10] and Hatal *et al.*, [13]. Nevertheless, a malignant transformation can be seen and especially in liposarcoma as described in our Observation 1.

Therapeutically, surgery represents the standard treatment, key to the local and general prognosis. An enlarged lumpectomy with a margin of safety of at least 10 mm is indicated for grade 1 and 2 tumors, and a simple mastectomy without lymph node dissection is indicated for grade 3 tumors, or for tumors larger than 5 cm. The ganglionic involvement is this is why axillary dissection is not recommended routinely even in the case of grade 3 phyllode tumors [2]. In our series, an extended excision was necessary for a local control of the tumor. Adjuvant radiotherapy finds its place in the case of a tumor of grade 3, a third local recurrence, or a recurrence after a mastectomy [5]. Systemic chemotherapy is not a standard and its place is still debated, but must be discussed in forms at high risk of relapse [14]. Indeed, some propose it in case of factors of metastatic evolution in malignant phyllode tumors [11] (high tumor size, locoregional stage, extensive stromal proliferation with atypia). The main

evolutionary risk of benign phyllode tumors is that of local recurrence, that of sarcomas being, of course, haematogenous metastatic dissemination. The local recidivism rate varies from 7 to 70% according to the studies [1]. Local recurrences appear to be related to the degree of malignancy tumor as well as the surgical margins of excision. Our two observations are the best example. In fact, incomplete excision will inevitably lead to tumor recurrence, malignant transformation, or even metastatic spread.

CONCLUSION

The phyllode breast tumor is a mysterious tumor that still raises problems of terminology, preoperative diagnosis, histological interpretation and histopronostic classification. Also, and because of their rarity, their care is delicate. An early diagnosis, suspected or confirmed histologically must push to achieve a wide resection respecting oncological rules with margins of more than 1 cm, which is the best guarantee of a decrease risk of local recurrence and thus of metastatic evolution. In addition, clinical monitoring, mammographic and ultrasound is necessary for 5 years.

REFERENCES

1. Sabban, F., Collinet, P., Lucot, J. P., Boman, F., Leroy, J. L., & Vinatier, D. (2005). Tumeurs phyllodes du sein: A propos de 8 patientes. *Journal de gynécologie obstétrique et biologie de la reproduction*, 34(3), 252-256.
2. Elouahli, N. (2012). *Evolution sarcomateuse d'une tumeur phyllode du sein à propos d'un cas et revue de la littérature* (Doctoral dissertation).
3. Benchiba, I. (2014). Les tumeurs phyllodes du sein (à propos de 17 cas). Thèse n°047/2014. Faculté de médecine et de pharmacie de Fès.
4. Fathallah, K., Laabidi, I., Ben Sassi, H., Elgoul, L., Hachani, F., Khelifi, A., ... & Hidar, S. (2013). 87. Tumeur phyllode du sein: prise en charge et facteurs pronostiques. À propos d'une série de 45 cas. *Posters*.
5. Issara, K., Houjam, M., Sahraoui, S., Bouchbika, Z., Benchakroun, N., Jouhadi, H., ... & Benider, A. (2016). Tumeur phyllode chez une jeune adolescente de 12 ans: à propos d'un cas et revue de la littérature. *Pan African Medical Journal*, 25(1).
6. Maitrot-Mantelet, L., Chauvenet, L., Hugol, D., Bethoux, J. P., Gompel, A., & Plu-Bureau, G. (2012). Tumeur phyllode maligne du sein et grossesse: à propos d'un cas. In *Cancer du sein: surdiagnostic, surtraitement* (pp. 274-275). Springer, Paris.
7. Fakhir, B., Louba, A., Bouchikhi, C., Bouguern, H., Chaara, H., Melhouf, M. A., & Banani, A. (2010). Les sarcomes phyllodes: à propos de cinq patientes et revue de la littérature. *Oncologie*, 12(1), 105-108.

8. Blanc, B., Sultan, C., & Jamin, C. (2004). *Traité de gynécologie médicale*. Springer Science & Business Media.
9. Olugbenga, S., Isichei, M., & Isichei, C. (2011). Malignant Phyllodes Tumour in a Non-Governmental Health Centre (Faith Alive Foundation) in Jos, Plateau State North Central Nigeria. A Case Report and Review of Literature. *Jos Journal of Medicine*, 5(2), 50-53.
10. Khabouze, S., Chbani, M., Baydada, A., Rhrab, R., Chahtane, A., & Kharbach, A. (2001). Tumeurs phyllodes du sein (à propos de 14 cas). *Maroc Médical*, 23(3), 192-196.
11. Bendifallah, S., & Canlorbe, G. (2015). Prise en charge des tumeurs bénignes du sein épidémiologiquement fréquentes de type adénofibrome, phyllode (grade 1 et 2), et papillome: recommandations. *Journal de Gynécologie Obstétrique et Biologie de la Reproduction*, 44(10), 1017-1029.
12. Defêchereux, T., Hamoir, E., Meurisse, M., & Limage, D. M. (2002). La tumeur phyllode mammaire. *Rev Med Liege*; 57 : 10 : 629.
13. Hatal, M. (2009). Les tumeurs phyllodes du sein « A propos de 40 cas ». Thèse n° 24/2009. Faculté de médecine et de pharmacie de Marrakech.
14. Grenier, J., Delbaldo, C., Zelek, L., & Piedbois, P. (2010). Tumeurs phyllodes et sarcomes du sein: mise au point. *Bulletin du Cancer*, 97(10), 1197-1207.