

## Retroperitoneal Schwannoma-About a Case

Mahaouchi M<sup>1\*</sup>, Alilou I<sup>2</sup>, Rahmoune M<sup>2</sup>, Meklaa A<sup>2</sup>, Laghzaoui O<sup>2</sup>

<sup>1</sup>Resident, Obstetrics and Gynecology Department of Moulay Ismail Military Hospital Meknes, Morocco

<sup>2</sup>Obstetrics and Gynecology Department of Moulay Ismail Military Hospital Meknes, Morocco

### Original Research Article

\*Corresponding author

Mahaouchi M

#### Article History

Received: 22.08.2018

Accepted: 06.09.2018

Published: 30.09.2018



**Abstract:** Schwannoma is a tumor developed at the expense of Schwann cells. It is a very rare tumor both by its frequency and its retroperitoneal location. Varied presentation and difficult preoperative diagnosis. Although the vast majority of schwannomas are benign, there are malignant forms frequently associated with Von Recklinghausen's syndrome. Its diagnosis is histological and its surgical treatment consists of a complete excision of the mass due to a tumor degenerative risk. We report a case of a 59-year-old patient, followed for chronic pelvic pain associated with digestive signs, ultrasonography and scanner showed a pelvic retroperitoneal mass of 8x6 cm long axis. Exeresis was performed by laparotomy. The histological and immunological study concluded to a benign schwannoma. The clinical and paraclinical evolution over 5 years did not show local or distant recurrence. Through a review of the literature we recall the frequency, diagnosis, imaging data, treatment and evolution of this rare tumor.

**Keywords:** Retroperitoneal tumor; Benign Schwannoma; Surgery.

### INTRODUCTION

Schwannoma is a rare nerve tumor, usually benign but with a risk of malignant transformation [1-3]. It develops from the cells of Schwann's nerve sheath [1, 2, 4]. It develops in most cases at the level of the cranial nerves (especially the eighth pair) or peripheral nerves but extremely rarely in the retroperitoneum [1, 4, 5]. It can be part of a phacomatosis [2].

This tumor poses the problem of diagnosis preoperatively because it is only asserted on the histological examination of the lumpectomy specimen [1, 3-5].

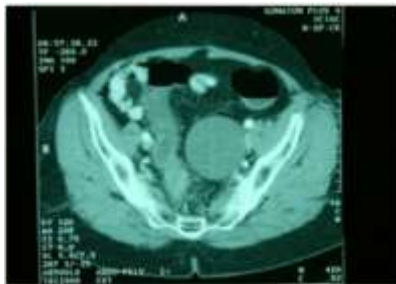
We report a new case of retroperitoneal pelvic schwannoma and through a review of the literature we will take stock of this type of tumor.

### OBSERVATION

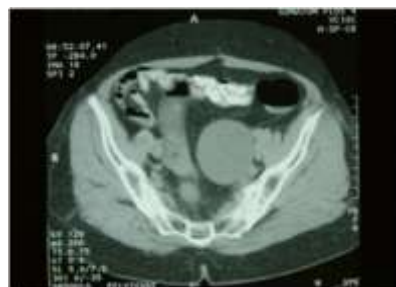This is a 59-year-old patient with a large multiparous, with no particular pathological history, admitted for the treatment of chronic pelvic pain with a type of gravity that appeared 6 months ago in the lumbosacral region and radiates to the patients. Thighs

and external genitalia, associated with constipation, without urinary signs, all evolved in a context of apyrexia and conservation of the general condition. The gynecological and general examination was without abnormalities. The abdominopelvic ultrasound showed a hypochoic mass, of well-defined homogeneous structure sus and latero-uterine left separated from the uterus and the ovary.

The scanner abdominopelvic showed an oblong retroperitoneal mass, measuring 8/6 cm, homogeneous well limited without signs of infiltration of neighboring organs and not enhancing after injection of the contrast medium (Figure 1 & 2).



**Fig-1: Pelvic computed tomography; axial section: Homogeneous left retro-mass and subperitoneal mass not enhancing after injection of the contrast product**



**Fig-2: Pelvic computed tomography; axial section: Homogeneous left retro-mass and subperitoneal mass not enhancing after injection of the contrast product**

The surgical exploration performed by laparotomy found a retroperitoneal tumor, the direct approach allows easy excision of the tumor, the operative follow-ups were simple. Histological examination of the surgical specimen confirmed the diagnosis of benign schwannoma type B. Clinical and paraclinical monitoring, in particular by CT scan, did not show local recurrence over a 5-year follow-up.

## DISCUSSION

Schwannoma is a solid tumor that develops at the expense of Schwann cells [1-3]. In 1910, Verocay described the first observation [6, 7]. The term schwannoma was owed to Masson in 1932 [1, 2, 7]. A schwannoma is very rarely retroperitoneal [1, 2]. It represents 3% of schwannomas and 4% of primitive retroperitoneal tumors [1, 2, 8]. This retroperitoneal localization represents only 0.7% of benign schwannomas and 1.7% of malignant schwannomas [1, 2]. Both sexes are equally affected and the age of the patients is most often between 30 and 60 years old [1, 2, 4]. The association with phacomatosis is usual [1, 2]. The diagnosis is most often fortuitous and late, given the latency of the evolution of the tumor. Sometimes during the exploration of abdominal or pelvic pain or because of the compression of neighboring organs: gastric pain and dyspepsia, but also portal thrombosis or ureteral compression [1-8]. This lack of specificity of the clinical signs makes its diagnosis difficult and often late.

Ultrasound and CT, if they make the retroperitoneal mass diagnosis, do not show pathognomonic images, however schwannoma is

classically described as a well encapsulated and solid tumor when it is small. It can become haemorrhagic and necrotic when it is larger [2-4, 9]. Another imaging argument is the presence of intratumoral cysts, which are found in 63% of cases for benign schwannomas and in 75% of cases for malignant schwannomas, this is noteworthy because retroperitoneal tumors rarely form cysts [2, 4, 9, 10]. Calcifications have also been observed; this would be an argument for degeneration [2, 3, 4]. Nuclear magnetic resonance provides the same information. It shows a well encapsulated tumor with a low signal in T1 and a heterogeneous hypersignal in T2 [4, 9-11]

Preoperatively, diagnosis of schwannoma will be reported in one third of cases [1, 2, 4-8]. The diagnosis of certainty can only be made on the histology, the samples being obtained by biopsies or on the operative specimen. Percutaneous aspiration biopsy is not recommended by most authors because of the difficulties of interpretation, the risk of neoplastic dissemination in case of malignant tumor and peritumoral hypervascularization [1, 2, 4, 6, 12].

Surgical excision is recommended in view of the possible histological heterogeneity of retroperitoneal tumors [1, 2, 4-6, 12-15].

Macroscopically, the tumor is nodular, well-constrained, encapsulated, and has cystic areas. In microscopy, the tumor is characterized by the presence of Verocay nodules [1].

There are two histological types of schwannomas (Antoni types A and B):

- Type A: fusiform cells arranged in bundles. The nucleus is oval. The cytoplasm is scanty;
- Type B: the arrangement of fusiform cells is hazardous. The cells are separated by a heterogeneously stained matrix with hematoxylin eosin and alcian blue.

The expression of the S100 protein in immunohistochemical study is the witness of a neurectodermic differentiation, its positivity thus directs towards a schwannoma [1, 2].

The treatment consists of a complete surgical enucleation of the tumor generally easy, since it is encapsulated. The approach is based on seat and tumor volume [1, 2, 4-7, 13, 15].

This excision can be difficult and sometimes incomplete due to intimate contact with large vessels or noble organs [2, 4, 5, 13, 14]. Recurrence is rare if the ablation has been complete. A case of heterotopic recurrence has been described, the appearance of a retroperitoneal schwannoma following exeresis of a spinal schwannoma [16]. On the other hand, benign schwannoma degenerates only exceptionally: Only one case has been described or a malignant schwannoma has appeared at a distance from a site of excision of a benign schwannoma [2, 4, 16]. This risk, even low, of transformation and recurrence makes annual post-operative surveillance by computed tomography necessary [1, 2, 5, 14, 15].

Although the great majority of schwannomas are benign and have a good prognosis, there are malignant forms whose histological nature is controversial because of their frequent association with Von Recklinghausen syndrome (4% of cases) and other neurofibromatosis [2].

The treatment of malignant schwannoma is surgical, as these tumors respond poorly to radiotherapy or chemotherapy. Metastases are preferentially hepatic, pulmonary, bone and in the subcutaneous tissue [17]. Lymphatic dissemination is very rare. The association of malignant schwannoma with neurofibromatosis is a derogatory factor since the 5-year survival rate increases from 47% to 23% [18].

## CONCLUSION

Retroperitoneal schwannoma is a rare tumor with a good prognosis in its benign form. His clinical diagnosis is often late because of borrowing symptomatology. Paraclinical examinations specify its retroperitoneal origin and evaluate the possibilities of excision. Radical surgery is the standard treatment. Due

to recurrence or even malignant transformation, further monitoring is required.

## REFERENCES

1. Moualli, S. B., Hajri, M., Amna, M. B., Kolsi, K., Chebil, M., Jilani, S. B., ... & Ayed, M. (2001, January). Le schwannome rétropéritonéal. A propos d'un cas. In *Annales d'urologie* (Vol. 35, No. 5, pp. 270-272). Elsevier Masson.
2. Garcia, G., Anfossi, E., Prost, J., Ragni, E., Richaud, C., & Rossi, D. (2002). Schwannome rétropéritonéal bénin: à propos de trois cas. *Prog Urol*, 12(3), 450-3.
3. Daneshmand, S., Youssefzadeh, D., Chamie, K., Boswell, W., Wu, N., Stein, J. P., ... & Skinner, D. G. (2003). Benign retroperitoneal schwannoma: a case series and review of the literature. *Urology*, 62(6), 993-997.
4. Li, Q., Gao, C., Juzi, J. T., & Hao, X. (2007). Analysis of 82 cases of retroperitoneal schwannoma. *ANZ journal of surgery*, 77(4), 237-240.
5. Kallel, W., Dhibi, K., Selmi, M., Bentaher, C., Hizem, R., Noomene, F., ... & Hamdi, A. (2006). Le schwannome rétropéritonéal: Exérèse par voie coelioscopique. *Le Journal de coelio-chirurgie*, (59), 48-51.
6. Khouni, H., Andriane, R., Nidhal, H., Badreddine, S., de LEVAL, J., & Faouzi, M. A. (2005). Tumeur rétropéritonéale rare: schwannome bénin. *Progrès en Urologie*, 15, 78-80.
7. Rattier, B., Desrousseaux, B., Dereux, H. J., Atat, I., & Ampé, J. (1990). Les schwannomes bénins rétropéritonéaux pelviens: à propos de 2 observations. *Journal de chirurgie*, 127(4), 209-212.
8. Aubert, J., Debais, F., & Levillain, P. (2000, February). Schwannoma of the obturator nerve with urologic manifestations: report of a case. In *Annales d'urologie* (Vol. 34, No. 1, pp. 58-65).
9. Schindler, O. S., Dixon, J. H., & Case, P. (2002). Retroperitoneal giant schwannomas: report on two cases and review of the literature. *Journal of Orthopaedic Surgery*, 10(1), 77-84.
10. Merran, S., Karila-Cohen, P., & Vieillefond, A. (2004). Tumeurs rétropéritonéales primitives de l'adulte. *Journal de Radiologie*, 85(2), 252-264.
11. Maeda, N., Yoshida, T., & Higuchi, Y. (2000). A case of retroperitoneal schwannoma: diagnostic usefulness of magnetic resonance imaging. *Hinyokika kyo. Acta urologica Japonica*, 46(3), 173-175.
12. Giglio, M., Giasotto, V., Medica, M., Germinale, F., Durand, F., Queirolo, G., & Carmignani, G. (2002, January). Retroperitoneal ancient schwannoma: case report and analysis of clinico-radiological findings. In *Annales d'urologie* (Vol. 36, No. 2, pp. 104-106). Elsevier Masson.
13. Pollo, C., Richard, A., & Preux, J. D. (2004).

- Résection d'un schwannome rétro-péritonéal en sablier par abord combiné. *Neurochirurgie*, 50(1), 53-56.
14. Cury, J., Coelho, R. F., & Srougi, M. (2007). Retroperitoneal schwannoma: case series and literature review. *Clinics*, 62(3), 359-362.
15. Goh, B. K., Tan, Y. M., & Chung, Y. F. (2006). Retroperitoneal schwannoma. *American Journal Surgery*, 192: 14-18.
16. Yamamichi, F., Nonomura, M., Soeda, A., Kanaoka, T., Fujikawa, K., & Takeuchi, H. (1999). Retroperitoneal schwannoma: a case report. *Hinyokika kyo. Acta urologica Japonica*, 45(1), 41-43.
17. Saito, R., Ishizuka, E., Iwasaki, A., & Kobayashi, K. (1997). Retroperitoneal malignant Schwannoma in the pelvis: a case report. *Hinyokika kyo. Acta urologica Japonica*, 43(1), 25-28.
18. Ortiz, J. R., da Silva Alexandro, E., Rico, S. G., Antón, I. B., San, P. M. F., & Zungri, E. T. (1999). A retroperitoneal cellular schwannoma. *Actas urologicas espanolas*, 23(5), 455-458.