

Prevalence of Wormian Bones in Dry Adult Human Skull in University of Port Harcourt and Rivers State University

Amadi-Ikpa H.A.¹, Jacks T.W.¹, Ajie P.C.¹, Victor P.D.^{1*}, Horsefall U.A.¹, Eyinda B.¹, Okpara P. E.², Ajie P.C.¹, Reuben E.², Dan-Jumbo T.², Tee G.P.²

¹Department of Human Anatomy, Faculty of Basic Medical Sciences, College of Medical Sciences, Rivers State University, Nkpolu Oroworukwo, Port Harcourt, Nigeria

²Department of Human Physiology, Faculty of Basic Medical Sciences, College of Medical Sciences, Rivers State University, Nkpolu Oroworukwo, Port Harcourt, Nigeria

DOI: [10.36348/sijap.2023.v06i04.003](https://doi.org/10.36348/sijap.2023.v06i04.003)

Received: 25.02.2023 | Accepted: 05.04.2023 | Published: 29.04.2023

*Corresponding author: Victor P.D.

Department of Human Anatomy, Faculty of Basic Medical Sciences, College of Medical Sciences, Rivers State University, Nkpolu Oroworukwo, Port Harcourt, Nigeria

Abstract

Wormian bones, otherwise 'Sutural' bones, are accessory bones within or near cranial sutures. They are mostly found on lambdoid sutures and can be one or more in each suture. This study is aimed at examining the incidence and frequency of Wormian bones in the dry adult cadaveric skull in Rivers State, Nigeria. Forty-three (43) dry adult skulls were examined for the presence, number, and location of Wormian bone. Thirty-seven (37) of the skulls were from the osteological collections of the Department of Human Anatomy, Faculty of Basic Medical Sciences, College of Health Science, University of Port Harcourt, and six (6) from the osteological collections of the Department of Human Anatomy, Faculty of Basic Medical Sciences, College of Medical Sciences, Rivers State University. 13 (30.23%) of the calvarias had Wormian bones while sutural bones were absent in 30 (69.77%). 8 (61.53%) calvarias with Wormian bones had sutural bones in the lambdoid suture; with 3 (23.08%) on the left arm and 5 (38.46%) on the right arm of the lambdoid suture. 2 (15.38%) of the calvarias with Wormian bone had sutural bone in the sagittal suture and 3 (23.08%) had Wormian bones in the lambda (Inca bone). The knowledge of incidence of Wormian bone and their calvaric distribution as described in this study is essentially useful to the Anatomist, Radiologist, Pediatrician, and Surgeon in their daily practice, as well as in forensic medicine.

Keywords: Calvaria, Wormian bone, Sutural bone, Inca bone, fontanelle, Sutures.

Copyright © 2023 The Author(s): This is an open-access article distributed under the terms of the Creative Commons Attribution 4.0 International License (CC BY-NC 4.0) which permits unrestricted use, distribution, and reproduction in any medium for non-commercial use provided the original author and source are credited.

INTRODUCTION

Wormian bones are intra-sutural bone, seen in Cranial sutures. Most commonly, they are found in lambdoid sutures (Nayak, 2008). Wormian bone can be single or multiple in each sutural location. They have been seen in the fontanelles, particularly the posterior fontanelle (Bellary *et al.*, 2013). A large Wormian bone at the lambda is often referred to as Inca bone (*os incae*) due to its relatively high frequency in Peruvian mummies. Another specific Wormian bone, the pterion ossicles, sometimes exist between the sphenoid angle of the parietal bone and the greater wing of the sphenoid bone.

The development of cranial bones begins with the condensation of mesenchymal cells that surrounds the developing brain. Two types of ossification occur in

the formation of the skull, first is intramembranous ossification through which the cranial vault and viscerocranium develop. The other is endochondral ossification through which the base of the skull develops. Sutures are craniofacial articulations of bones in which the margins of the bones approximate each other and are united by a thin layer of fibrous tissues that permit minor movement (Francis, 2011). The cranial vault sutures are fibrous tissues uniting the bones of the skull. They are the major site of bone growth along the leading margin during craniofacial development of the neurocranium (Opperman *et al.*, 2000). Sutures are not only joints; they are the primary regions of osteogenesis and the site of proliferation and differentiation of osteoprogenitor cells (Francis, 2011). The principle behind the formation of Wormian bone

can therefore be explained possibly by the formation of extra-ossification centers within the cranial sutures.

However, two hypotheses are widely used to explain the mechanism for the origin of Wormian bone. First, sutural bones are said to develop under genetic influence (Finkel, 1971). Benneth (1965) stated that Wormian bones are inherited as a dominant trait. It is speculated that the expression of a single gene is responsible for sutural bone formation (Finkel, 1971). It has been noted that the formation of Wormian bone is under epigenetic control (Mao *et al.*, 2003). The second hypothesis postulated that mechanical stress such as artificial cranial deformation or craniosynostosis is the main reason for sutural bone formation (Finkel, 1971; O'Loughlin, 2004; Sanchez-Lara *et al.*, 2007).

Furthermore, it has been suggested that genetic factors influence the structural appearance of Wormian bone, while mechanical stress has an impact on their number (El-Najjar *et al.*, 1997; Mao *et al.*, 2003; Sanchez-Lara *et al.*, 2007). Studies also suggest an interplay of genetic influence and stress in the pathogenesis of sutural bone (Kenneth *et al.*, 1965). Wormian bones are believed to occur more frequently in disorders that have reduced cranial ossification centers, hypotonia or decreased movement, thereby resulting in deformational brachycephaly (Sanchez-Lara *et al.*, 2007).

It has been hypothesized that the pathogenesis of Wormian bone may be due to environmental variations in dural strain within open sutures and fontanelles (Sanchez-Lara *et al.*, 2007). Wormian bones

have been demonstrated in various abnormalities such as down syndrome, kinky hair syndrome, Menke's syndrome, otopalatodigital syndrome, congenital disorders such as osteogenesis imperfecta, cretinism, cleidocranial dysostosis, primary acro-osteolysis, rickets, and hypothyroidism (Atoni *et al.*, 2021). However, the presence of sutural bones does not always indicate an abnormality. Sutural bones have been noted in normal subjects. When present, they are usually less than ten (10) in number, and beyond that, it is considered as pathological ((Pryles, & Khan, 1979). Sutural bones may be a useful guide in the diagnosis and treatment of children with congenital malformation (Marti *et al.*, 2013).

The aim of this study is to examine the frequency and topographical distribution of Wormian bone in the adult dry cadaveric skull at the University of Port Harcourt and Rivers State University.

MATERIALS AND METHODS

A total of forty-three (43) dry human adult skulls were used for this study. Thirty-seven (37) of the skulls were from osteological collections of the Department of Human Anatomy Faculty of Basic Medical Sciences, College of Health Sciences, University of Port Harcourt, while six (6) were from the osteological collections of the Department of Human Anatomy, Faculty of Basic Medical Sciences, College of Medical Sciences, Rivers State University, all in Rivers State, Nigeria. The skulls were examined for the presence, frequency, and topographical distribution of Wormian bone.




Fig. 1.1: Collection of Cadaveric Dry Human Skulls

RESULTS

A total of 43 dry adult human cadaveric skulls were examined, out of which sutural bones were found

present in 13 (30.23%), while Wormian bones were absent in 30 (69.77%) (Table 1.1, fig. 2.1 and fig. 2.2).

Table 1.1: Incidence of Wormian bone in the total dry skull

Wormian Bone	Number of skulls	%
Present	13	30.23
Absent	30	69.77
Total	43	100

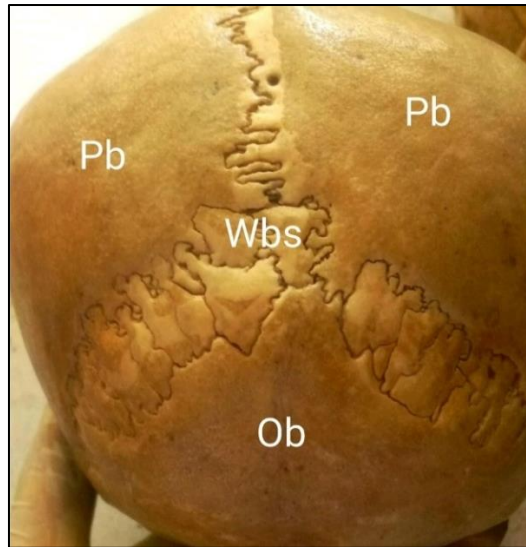


Fig 2.1: The skull, showing the lambdoid sutural bones (Wbs) in the lambda, on both left and right wings of lambdoid suture. Parietal bone (Pb), Occipital bone (Ob).

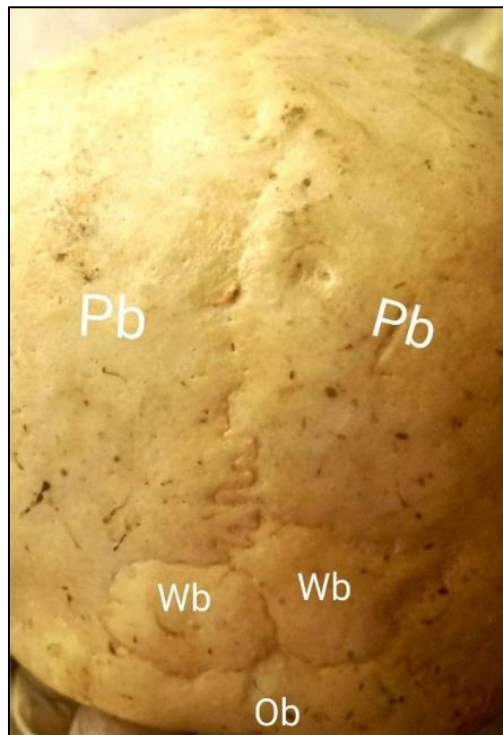


Fig. 2.2: The skull showing multiple Inca bones (Wb), parietal bone (Pb), and Occipital bone (Ob).

The topographical distribution of the sutural bones in the thirteen cadaveric skulls showed that 8 (61.54%) have sutural bones in the lambdoid sutures with 3 (23.08%) on the left arm of the lambdoid suture and 5 (38.46%) on the right arm. Three (3) (23.08%)

calvaria has Inca bone in the lambda, while 2 (15.38%) has Wormian bone in the sagittal suture (Table 2.1 and fig. 3.1).

No Wormian bone was seen in the coronal suture and bregma in the study.

Table 2.1: Topographical distribution of Wormian bone in the calvaria

S/N	Region of the Calvaria	No. of Sutural Bones	%
1	Sagittal Suture	2	15.38
2	Coronal suture	0	0.00
3	Lambdoid Suture		
A	Left arm	3	23.08
B	Right arm	5	38.46
4	Lambda (Inca bone)	3	23.08
5	Bregma suture	0	0.00
	Total	13	100

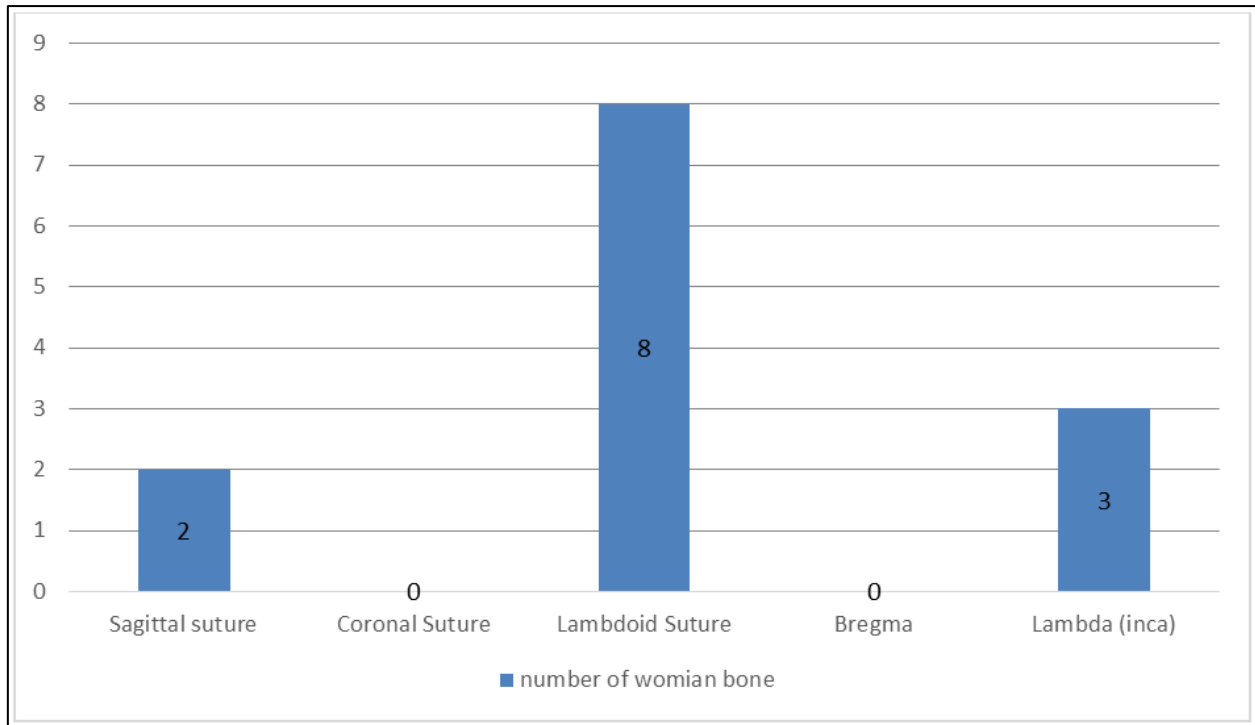


Fig. 3.1: Bar chart showing the distribution of Wormian bone on the calvaria

DISCUSSION

Wormian bones are sutural bones found in both normal and pathological conditions. The first description of these bones was attributed to Olaus Wormius, after whom the bones were named. The principle behind the formation of sutural bones can be explained by the formation of extra ossification centers within the cranial sutures. However, genetic influence in combination with stress has been implicated in the formation of Wormian bones (Finkel, 1971; Sacher-Lara *et al.*, 2007). Normal variants occur in which cases the number of sutural bones in each skull does not exceed ten (10) (Burgener *et al.*, 1997). Beyond this number, it is invariably pathological (Pryles, & Khan, 1979). Sutural bones are important clinical markers for several conditions like osteogenesis imperfecta, down syndrome rickets, hypothyroidism, etc., though it is not pathognomic. The prevalence of Wormian bone in our study is 30.23%. This varies from the results obtained in earlier studies in different parts of Nigeria, and globally. Uchenwa *et al.*, (2018) reported a higher

incidence of 45.46% in eastern Nigeria, while Atoni *et al.*, (2021) reported an incidence of 55.9% in Bayelsa State. Asharani *et al.*, (2020) reported a prevalence of 25.26% in Nagara, India. In Nepal, a prevalence of 88.57% was reported (Basnet *et al.*, 2019). Furthermore, Murlimanju *et al.*, (2011) reported an incidence of 73.1% in India. This disparity in the prevalence of Wormian bone amongst other studies relative to the present study may be explained by ethnic, racial, and geographical factors. This agrees with the postulated hypothesis of genetic and environmental factors, which influence the formation of Wormian bone. It is therefore convenient to infer that genetic factor in different ethnic groups, as well as racial and geographical locations are deciding factors in the pathogenesis of Wormian bone.

In our study, the maximum number of sutural bones were seen in the lambdoid suture (61.54%) followed by the sagittal suture (15.38%), while none was seen in the coronal, pterion, and bregma sutures.

This result agrees with the finding of earlier studies, including those of Uchenwa *et al.*, (2018) and Atoni *et al.*, (2021).

The topographical distribution of sutural bones is important in clinical practice, especially as the Radiologist and Surgeon may mistake multiple sutural bones for comminuted fracture of the skull.

With the knowledge of Wormian bone, these professionals can limit their level of suspicion of fracture in regions of the skull where the prevalence of sutural bone is high. On the other hand, it can further increase their indices of suspicion of fracture in the regions of the skull where Wormian bones are rarely seen.

CONCLUSION

In this study a prevalence of 30.23% has been reported for Wormian bones in the dry adult skull in the University of Port Harcourt and Rivers State University, all in Rivers State, Nigeria. In as much as this rate is lower than rates reported in some studies, it is also noted to be higher than some other reported prevalence in different geographical locations. The variation in prevalence reported in different locations and ethnic groups indicate the possible influence of ethnic, racial, and environmental factors in the pathogenesis of Wormian bone. Sutural bones were seen to be more prevalent in the lambdoid suture, followed by sagittal suture and least common in coronal and bregma sutures. This knowledge is relevant to the Anthropologist, Anatomist, Radiologist, Pediatrician and Surgeon, who may find this information useful in their daily practice.

REFERENCES

- Anderson, B. W., Kortz, M. W., & Alkharazi, K. A. (2022). *Anatomy, Head and Neck, skull*. [updated] Treasure Island (FL): Stat Pearls publishing. Available from: <http://www.ncbi.nlm.nih.gov/books/NBK499834>.
- Asharani, S. K. (2020). A study on occurrence of Wormian bone in adult dry skulls. *International Journal of Anatomy and Research*, 8(4), 7814-7816. DOI:10.16965.
- Atoni, D. A., Ugochukwu, L. T., Daminola, A. U. F., Anthony, O. J., & Waebi, O. (2021). The frequency and topographical distribution of sutural bones in adult dry skulls. *European Journal of Biomedical and Pharmaceutical Sciences*, 8(9), 83-87.
- Basnet, L. M., Shrestha, S., & Sapkota, S. (2019). Prevalence of Wormian bones in dried adult human skull: an osteo-morphometric study in Nepal. *Anatomical Science International*, 94, 101-109. <https://doi.org/10.1007/s12565-018-0454-x>
- Bellary, S. S., Steinberg, A., Mirzagyanyan, B. N., Shirak, M., Tubbs, R. S., Cohen, G. A., & Loukas, M. (2013). Wormian bones: A review. *Clinical Anatomy*, 26, 922-927. <https://doi.org/10.1002/ca.22262>
- Bennett, K. A. (1965). The etiology and genetics of Wormian bones. *American Journal of Physical Anthropology*, 23(3), 255-260.
- Burgener, F. A., & Kormano, M. (1997). Bone and joint disorders, conventional radiologic differential diagnosis. New York: Thieme medical publishers. 130.
- El-Najjar, M., & Dawson, G. L. (1977). The effects of artificial cranial deformation on the incidence of Wormian bones in the Lambdoidal suture. *American Journal of Physical Anthropology*, 46, 155-160.
- Finkel, D. J. (1971). Wormian bones: a study of environmental stress. *American Journal of Physical Anthropology*, 35, 278.
- Francis, H. G. (2011). Pediatric bone: Biology & Diseases. Academic Press Inc. (chapter 3) p. 85.
- Ghoh, S. K., Biswas, S., Sharma, S., & Chakraborty, S. (2017). An anatomical study of Wormian bones from the eastern part of India: is genetic influence a primary determinant of their morphogenesis? *Anatomical Science International*, 92, 373-383. <https://doi.org/10.1007/s12565-016-0342-1>
- Goyal, N., Garg, K., & Vogseh, I. (2019). Prevalence and medicolegal significance of Wormian bones in human skulls in North India region. *International Journal of Applied and Basic Medical Research*, 9(3), 165-168. [10.4103/ijabmr.104103](https://doi.org/10.4103/ijabmr.104103)
- Jeanty, P., Silva, S. R., & Turner, C. (2000). Prenatal diagnosis of Wormian bones. *Journal of Ultrasound Medicine*, 19, 863-869.
- Jin, S. W., Sim, K. B., & Kim, S. D. (2016). Development and growth of the normal cranial vault: an embryologic review. *Journal of Korean Neurosurgical Society*, 59(3), 192-196. <https://doi.org/10.3340/jkns>.
- Kaplan, S. B., Kemp, S. S., & Oh, K. S. (1991). Radiographical manifestations of congenital anomalies of the skull. *Radiologic Clinic of North America*, 29(2), 195-218.
- Kenneth, A. B. (1965). The etiology and genetics of Wormian bones. *American Journal of Physical Anthropology*, 23(3), 255-260.
- Mao, J. J., Wang, X., Money, M. P., Kopher, R. A., & Nudera, J. A. (2003). Strain induced osteogenesis of craniofacial suture upon controlled delivery of low frequency cyclic forces. *Frontiers in Bioscience*, 8, 10-17.
- Marti, B., Sirinelli, D., Maurin, L., & Carpentier, E. (2013). Wormian bone in a general paediatric population. *Diagnostic and Interventional Imaging*, 94, 428-432.
- Muralimanju, B. V., Prabhu, L. V., Ashraf, C. M., Klmar, C. G., Rai, R., & Maheshwari, C. (2011). Morphological and topographical study of

- Wormian bones in cadaver dry skulls. *Journal of Morphological Science*, 28, 176-179.
- Murlimanju, B. V., Gupta, C., Samiullah, D., Praghu, L. V., Piamm, C. G., & Somesh, M. S. (2011). Morphological investigation of cranial sutures in Indian human adult skulls. *Romanian Journal of Morphology and Embryology*, 52, 1097-1100.
 - Natsis, K., Piagkou, M., Lazaridis, N., Anastasopoulos, N., Nousios, P. G., Piagkos, G., & Loukas, M. (2019). Incidence, number, and topography of Wormian bones in Greek adult dry skulls. *Folia Morphologica (Warsz)*, 78, 359-370.
 - Nayak, S. B. (2008). Multiple Wormian bones at the Lambdoid suture in an Indian skull. *Neuroanatomy*, 7, 52-53.
 - Nisha, G., Anil, G., & Yogesh, K. (2019). Incidence and medicolegal significance of Wormian bones in human skulls in North India region. *International Journal of Applied Basic and Medical Research*, 9(3), 165-168. Doi: 10.410.
 - O' Loughlin, V. D. (2004). Effects of different kinds of cranial deformation on the incidence of Wormian bones. *American Journal Physical Anthropology*, 123, 146-155.
 - Pryles, C. V., & Khan, A. J. (1979). Wormian bones: A marker of CNS abnormality? *American Journal of Diseases of Children*, 133, 380-382. [PubMed]
 - Sanchez-lara, P. A., Graham Jr, J. M., Hing, A. V., Lee, J., & Cunningham, M. (2007). The Morphogenesis of Wormian Bones: A study of Craniosynostosis and purposeful cranial deformation. Inc. *American Journal of Medical Genetics*, 143, 3243-3251.
 - Uchenwa, O. O., Egwu, O. A., Egwu, A. J., & Nwajagu, G. I. (2018). Incidence of Wormian bones in the dried skull of Nigerian males. *International Journal of Anatomical Variations*, (1), 32-34.