

A Study of Morphological Variations in the Shape and Helix of the External Ear

Dr. R. Ravi SUNDER^{1*}, Dr. Neelima P²

¹Professor, Department of Physiology, GIMSR, Visakhapatnam, Andhra Pradesh, India

²Professor, Department of Anatomy, GIMSR, Visakhapatnam, Andhra Pradesh, India

DOI: 10.36348/sijap.2019.v02i08.003

| Received: 20.08.2019 | Accepted: 27.08.2019 | Published: 30.08.2019

*Corresponding author: Dr. R. Ravi SUNDER

Abstract

Background: The quality and discrimination of sound depends on the shape of the pinna. The auricle exhibits wide variations particularly in its shape and the rolling of helix to such an extent that right and left ears of an individual differ. **Aim:** To determine different shapes of the external ear and the degree of concavity of helix. **Materials and methods:** 90 dental students participated in the study after an informed consent. The external ears of both sides were observed for variations in the shape and rolling of helix. The results were tabulated and compared with other studies. **Results:** Oval shaped external ears were the most common forms observed, 58.33% in males and 58.97% in females. The values were compared with other studies and the decreasing order of frequency of ear shapes was oval, triangular, round and rectangular. The concavity of helix was studied. 66.66% males and 60.25% females possessed normal helix followed by wide helix covering scapha, flat helix and concave marginal helix in that order in males but females possessed concave marginal helix in more numbers as compared to wide helix covering scapha. **Conclusion:** The four different shapes of the external ear were oval, triangular, round and rectangular in the decreasing order of frequency. Oval shape is the most common as correlated with other studies. Four varieties of rolling of helix were observed -normal rolling, wide concavity covering scapha, flat helix and marginal concavity helix. The order of frequency showed gender variation.

Keywords: External ear, morphology, variations, helix, dental students.

Copyright © 2019: This is an open-access article distributed under the terms of the Creative Commons Attribution license which permits unrestricted use, distribution, and reproduction in any medium for non-commercial use (Non-Commercial, or CC-BY-NC) provided the original author and source are credited.

INTRODUCTION

The external ear is the first organ to receive the sound stimulus in the auditory apparatus. It maintains its unique identity to a point where two ears of an individual are notably different. The shape of the pinna changes the quality of the sound entering the ear, depending on the direction from which the sound comes [1]. The ear is an under-recognised defining feature of the face where its shape and size provide information of the age and sex of the individual [2]. Pinna develops from six auricular hillocks of His formed around the first pharyngeal cleft. Hyoid arch initiates the formation of cranial three hillocks and the remaining is derived from the mandibular arch [3]. Variations in the morphology of the external ear reflect the underlying genetic abnormalities. External ear is a valuable tool of identity in medicolegal aspects. It is one of the five primary features of the human face and is particularly influential in determining its appearance [4]. The impression of ear prints on doors and windows [5] is of paramount importance in a crime scene investigation. The identity of a famous sandalwood smuggler

“Veerappan” was done by the ear morphology and biometrics measurements [6]. Few studies [7, 8] were done on the external ear from different parts of the World and India [9]. Vanezis P *et al.* [10] studied on the ear photographs of Caucasian males. The data regarding the occurrence of various shapes of the pinna and rolling of helix was scanty from the population of north coastal Andhra Pradesh. Hence the present study has been done.

MATERIALS & METHODS

After taking informed consent, 90 dental students (78 females and 12 males) with age between 17-20 years participated in the study. They were asked to give the photographs of the external ear. A total of 180 pinna were observed. Variations in the shape of the auricle and rolling of the helix were tabulated and compared with other studies.

RESULTS

The results obtained from the study were as follows. The following pictures show different shapes

of the pinna. 4 shapes were identified- oval, triangular, round and rectangular.

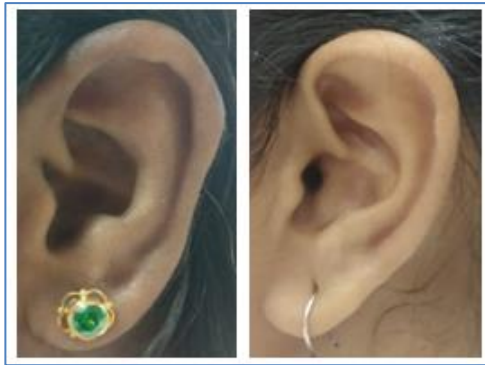

Fig-1: Oval, triangular pinna

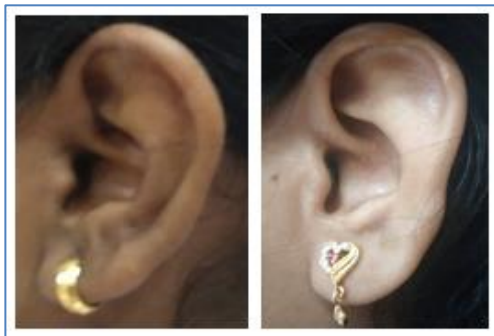
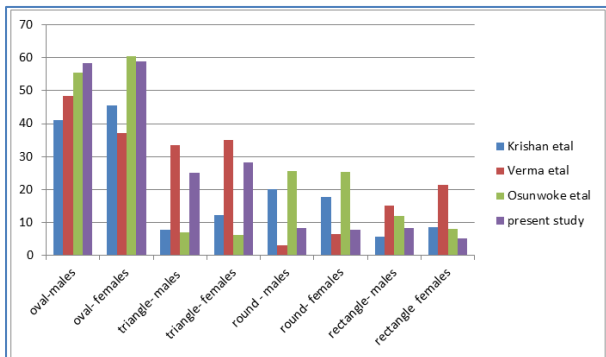


Fig-2: round & rectangular pinna

The following table and graph depicts the genderwise occurrence of various shapes of pinna in total and in percentage and also comparison with other studies.

Table-1: % gender wise distribution of various shapes of pinna

S No	Shape	Males (n= 12)		Females (n=78)	
		n	%	n	%
1.	Oval	7	58.33	46	58.97
2.	Triangular	3	25.0	22	28.20
3.	Round	1	8.33	6	7.69
4.	Rectangle	1	8.33	4	5.12
5.	Total	12	100	78	100



Graph-1: Gender wise frequency of occurrence of different ear shapes & comparison with other studies

The following pictures illustrate the occurrence of various forms of the helix. 4 different patterns have been identified- normally rolled helix,

wide helix covering scapha, flat helix and concave marginal helix.

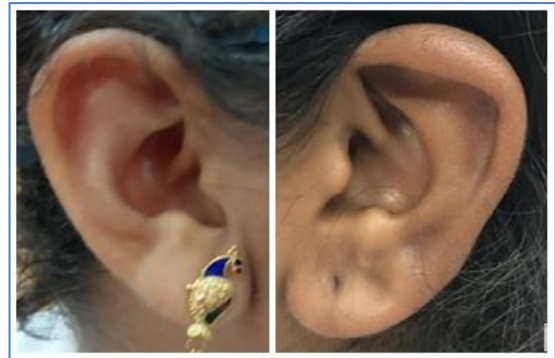

Fig-3: Various forms of helix- normally rolled, wide helix covering scapha

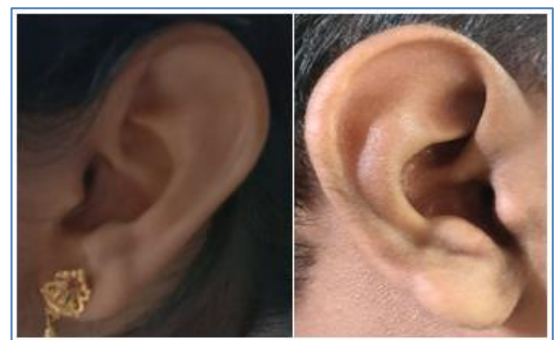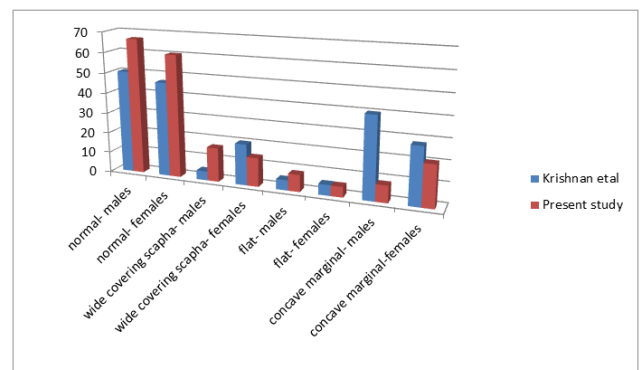


Fig-4: Flat helix, Concave marginal helix

The following table and graph shows the numbers and percentages of occurrence of various patterns of the helix in males and females and comparison with other study.

Table-2: Gender wise distribution of degree of concavity of the helix

S No	Shape of the helix	Males		Females	
		Number	%	Number	%
1.	Normal	8	66.66	47	60.25
2.	Wide covering scapha	2	16.66	11	14.1
3.	Flat	1	8.33	4	5.12
4.	Concave marginal	1	8.33	16	20.5
5.	Total	12	100	78	100



Graph-2: comparison of various shapes of helix

DISCUSSION

The human ear shows extensive variations in the form of its shape, curve of helix, anti-helix, tragus, ear lobe attachment etc. The present study is done on two types of variations exhibited by external ear i.e., shape of the pinna and degree of concavity of helix. According to Van der Lugt [11], oval shaped ears in Dutch males were 68.7%. Iannarelli [12] demonstrated that 65% of Americans possessed oval shaped ears. The present study illustrates that the commonest shape of external ear is oval, 58.33% in males and 58.97% in females which correlates with the values of the study made by Osunwoke *et al.* [13]. The decreasing order of frequency of other shapes was triangular, round and rectangular. The values were compared with other studies [13-15]. When the curve of helix was studied, four types of patterns were observed i.e., normal curve, wide concavity covering scapha, flat helix and marginal concavity of the helix. 66.66% males and 60.25% females possessed normal helix which corresponded to the values from the study done by Krishnan *et al.* [15]. The decreasing order of occurrence in males was wide helix covering scapha, flat helix and concave marginal helix in that order. But females possessed concave marginal helix in more numbers as compared to wide helix covering scapha. The present study was done on the population from north coastal Andhra Pradesh. It can be extended further to be done on population from other parts of the state and country.

CONCLUSION

Most common occurrence of the shape of external ear is oval shape followed by triangular, round and rectangular. Four different patterns of concavity of the helix were observed whose values correlated with other studies.

REFERENCES

- Guyton & Hall Textbook of Medical Physiology, Elsevier, South Indian Ed., 728.
- Keith, A. (1901). The significance of certain features and types of the external ear.
- Gray's Anatomy, 40th Ed; Churchill Livingstone Elsevier, 652-653.
- Purkait, R., & Singh, P. (2007). Anthropometry of the normal human auricle: a study of adult Indian men. *Aesthetic plastic surgery*, 31(4), 372-379.
- Meijerman, L., Sholl, S., De Conti, F., Giacon, M., van der Lugt, C., Drusini, A., & Maat, G. (2004). Exploratory study on classification and individualisation of earprints. *Forensic Science International*, 140(1), 91-99.
- Purkait, R. (2007). Ear biometric: An aid to personal identification. *Anthropologist Special volume*, 3, 215-218.
- Garba, S. H. (2010). Anthropometric study of the pinna (Auricle) among adult Nigerians resident in Maiduguri metropolis. *J. Med. Sci*, 10(6), 176-180.
- Rubio, O., Galera, V., & Alonso, M. C. (2017). Morphological variability of the earlobe in a Spanish population sample. *Homo*, 68(3), 222-235.
- Kumar, B. S., & Selvi, G. P. (2016). Morphometry of ear pinna in sex determination. *Int. J. Anat. Res*, 4(2), 2480-2484.
- Vanezis, P., Lu, D., Cockburn, J., Gonzalez, A., McCombe, G., Trujillo, O., & Vanezis, M. (1996). Morphological classification of facial features in adult Caucasian males based on an assessment of photographs of 50 subjects. *Journal of Forensic Science*, 41(5), 786-791.
- Ea, O., Wb, V., & Gc, A. (2018). Anthropometric study on the anatomical variation of the external ear amongst Port Harcourt students, Nigeria. *International Journal of Anatomical Variations*, 11(4).
- Van, D., Lugt, C. (2001). Ear Identification. Elsevier, Bedrijfsinformatie's Gravenhage, Amsterdam.
- Iannarelli, A.V. (1989). Ear identification. Forensic identification series. Paramount Publishing Company, Fremont.
- Verma, P., Sandhu, H. K., Verma, K. G., Goyal, S., Sudan, M., & Ladgotra, A. (2016). Morphological variations and biometrics of ear: An aid to personal identification. *Journal of clinical and diagnostic research: JCDR*, 10(5), ZC138.
- Krishan, K., Kanchan, T., & Thakur, S. (2019). A study of morphological variations of the human ear for its applications in personal identification. *Egyptian Journal of Forensic Sciences*, 9(1), 6.