

Congenital Ectopic Lower Lumbar Kidneys with Bilateral Malrotation and its Embryological Basis – A Case Report

Satyanarayana N^{1*}, Victor Anand David A¹, Aswinprakash S¹, Arulmoli R¹, Sunitha P²

¹Anatomy Unit, Faculty of Medicine, AIMST University, Semeling Bedong 08100, Kedah, Malaysia

²Physiology Unit, Faculty of Medicine, AIMST University, Semeling Bedong 08100, Kedah, Malaysia

*Corresponding author: Satyanarayana N

| Received: 09.06.2019 | Accepted: 19.06.2019 | Published: 30.06.2019

DOI: [10.36348/sijap.2019.v02i06.002](https://doi.org/10.36348/sijap.2019.v02i06.002)

Abstract

The variations in the structure and position of the kidney along with variations of renal vessels are reported by anatomists, surgeons and radiologists. Routine human cadaveric dissection showed a bilateral ectopic kidney with accessory renal artery was observed. Malrotation of both kidneys and altered anatomical structures in the hilum were observed. The both kidneys are located above the bifurcation of common iliac arteries. The Accessory renal arteries were arising from the abdominal aorta and supply both the kidneys. The renal veins draining into inferior vena cava. Ectopic kidney with rotational variation of accessory renal arteries is comparatively very rare. This may be asymptomatic or present with vague symptoms and sometimes remain unknown during the lifetime. These variations have an embryological basis and are clinically significant. Knowing such variations are important for general surgeons, gynecologists for performing various surgical procedures like laparoscopic surgeries and useful for the nephrologists when dealing with radical nephrectomy and renal transplantations.

Keywords: Ectopic kidney, Malrotation, Accessory renal arteries, Variations.

Copyright © 2019: This is an open-access article distributed under the terms of the Creative Commons Attribution license which permits unrestricted use, distribution, and reproduction in any medium for non-commercial use (Non-Commercial, or CC-BY-NC) provided the original author and source are credited.

INTRODUCTION

Clinical presentation of acute abdominal pain often misguiding symptom and creates difficulty in the diagnosis. Most of the cases pertaining to acute abdomen more specific to the lower abdominal pain, which sometimes may turn out to be a serious illness. The kidneys are located in the upper part of the posterior abdominal wall in the paravertebral gutters and located retroperitoneally. It vertically extends from upper border of T12 to the center of L3. Left kidney is slightly lower than the right kidney. In addition, the superior pole of the left kidney lies at a lower level of eleventh rib and the right kidney at the eleventh intercostal space because of the presence of liver. Left kidney is close to the median plane than the right. The trans-pyloric plane (L1) passes through the upper part of hilum of right kidney and lower part of hilum of left kidney. Kidneys are about 10 cm long, 5.5 cm broad and 3 cm thick. It weighs about 150 gm. in males & 135 in females. The fetal kidney is lobulated and the lobules fuse after birth [1]. There are two poles in the kidneys, upper and lower. The upper pole is broader, and it is in close contact with adrenal gland. The lower poles pointed. There are 2 borders-lateral & medial in which the lateral border is convex and medial border is concave shows hilum with renal vein, renal artery and

renal pelvis (VAP-anterior to posterior). The two surfaces of the kidney are anterior and posterior, the anterior surface is irregular & posterior surface is flat. The term renal ectopia is a congenital anomaly first described by anatomists in the 16th century. It is derived from the word “ec-topos” which in Greek means “out of place”. During embryological development of kidney, migrates to cephalic direction in their normal retroperitoneal location. Ectopic kidneys are due to the result of arrested normal migration. The ectopic kidneys may be present in iliac, pelvic, lower lumbar, abdominal, thoracic, or crossed position. The commonest type of renal ectopia is pelvic kidney [2]. The ectopic kidney may be mistaken for a tumor on clinical examination. The incidence of ectopic kidneys is 1:12,000 clinical and 1:900 postmortem cases [3]. The ectopic kidney is more susceptible to disease than normally positioned kidney due to the greater risk of injuring aberrant vessels or overlying abdominal viscera and nerves. Ectopic position of the kidneys and varied vasculature can predispose to accidental trauma during interventional radiological and laparoscopic procedures and emergency operations [4]. Therefore, the knowledge and the possibility of this anatomical variation will be of helpful for the clinician in making a correct diagnosis and offering appropriate treatment [5].

Case Report

Congenital lower lumbar kidneys with bilateral malrotation with variation in the renal artery and altered hilar Anatomy was observed in adult male cadaver during routine abdominal dissection in the Anatomy Unit, AIMST University, Bedong, Malaysia. After abdominal dissection the both kidneys were observed and found near to the pelvic brim and medial border of kidney facing anteriorly. Both kidneys are in same position and dimensions were analyzed. The dimensions of the left kidney were $11.5 \times 6.0 \times 2.0$ cm, larger than the right kidney whose dimensions were 11

$\times 5.5 \times 2.5$ cm. The both ectopic kidneys were lobulated. Both Right and left kidney was resting over psoas major muscle and inferior pole was present near to pelvic brim. The hilum's of both the kidneys are facing anteriorly which is considered as an altered hilar anatomy (Figure-1). Altered hilar anatomy includes alteration in major and minor calyces were visible externally. Normal hilar anatomy relation is disturbed. At the hilum the renal pelvis is present anteriorly. The both ureters were arising from hilum, tortuous and about 10 cm in length. Both suprarenal glands were present at upper pole of the kidney. The right and left kidneys were supplied by accessory renal arteries.

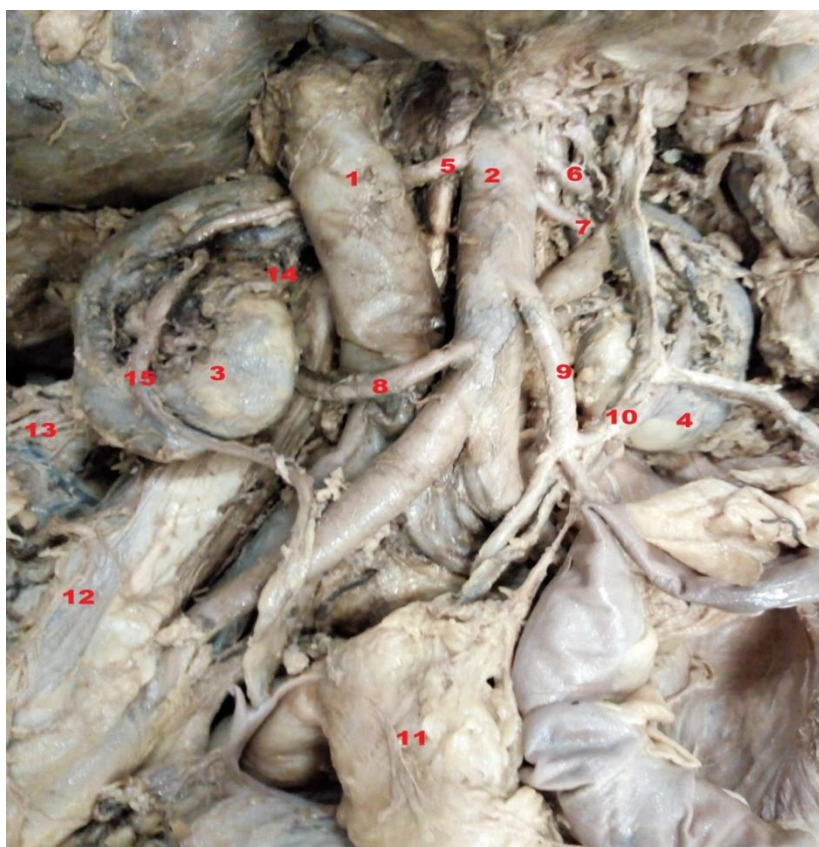


Fig-1: Congenital Lower Lumbar Kidneys with Bilateral Malrotation

1.Inferior Venacava, 2.Abdominal Aorta, 3.Right Kidney, 4.Left Kidney, 5,6,7,8-Accessory renal arteries, 9.Inferior mesenteric artery, 10.Left Ureter, 11.Sigmoid colon, 12.Psoas Major, 13.Right iliac fossa, 14.Accessory renal artery, 15.Right Ureter.

The right kidney is receiving two accessory renal arteries. The first branch arising from abdominal aorta below the origin of inferior mesenteric artery, it was 6 cm long and descended obliquely passing below the inferior vena cava, reaching to superior pole of kidney.

The second branch was 4 cm and arising from the lower part of abdominal aorta immediately above the bifurcation of common iliac artery at the level (L4-L5) and passes to the lower pole of the kidney. The left kidney is receiving three accessory renal arteries. The first branch arising below the origin of superior mesenteric artery, it was about 6.5 cm long and descended obliquely and reaching to superior pole of

kidney. The second branch was 5.5 cm and arising from the abdominal aorta immediately above the origin of inferior mesenteric artery, was passing in to hilum of left kidney. The third branch was 6cm long arising at the level of origin of inferior mesenteric artery and was passing in to hilum of left kidney.

The ectopic kidneys of both the sides were drained by two renal veins, right renal vein arising anteriorly from hilum the right kidney and drains into inferior venacava. Left renal vein arising anteriorly from the hilum of left kidney passing below the abdominal aorta and drains into inferior venacava.

The hilums of both kidneys were directed anteriorly and a bifid renal pelvis is observed, the renal pelvis is malrotated. Other gross anatomical variations were not observed.

DISCUSSION

The congenital anomaly of the renal system is more common than any other systemic anomalies. The renal system anomalies accounts for 3.0%, in which the lower lumbar kidney is a rare anomaly about 1:2500 live births and more commonly involved kidney is the left kidney [6]. The incidence of ectopic kidney is reported of 1:500 to 1:1100; ectopic thoracic kidney as 1:13000; one normal and one pelvic kidney as 1:3000 and crossed renal ectopic 1:7000 [7].

The normal functional ectopic kidney may even go undetected and it may be identified only after death, during dissection as mentioned in this case report or autopsy. The permanent kidney first lies in the pelvic cavity with its hilum directed anteriorly during embryological development. Kidney ascends with a medial rotation and gradually which reaches the lumbar region with its hilum directed medially. Because of decreased body curvature and increased growth of the body in the lumbar and sacral regions, the kidney ascend and reaches the lumbar region. When the ascend of kidney is arrested during the growing phase, this will lead to the ectopic position of kidney. It is due to arrest of its ascent during development [8].

The presence of accessory renal arteries can be described in the light of embryogenic development and its molecular regulation. The primitive dorsal aortas gives off ventral splanchnic arteries, lateral splanchnic arteries, somatic arteries and caudal continuation. The lateral splanchnic arteries supplies on either side of the mesonephros, metanephros, the gonads and the suprarenal gland. All the above structures develop, in whole or in part, from the intermediate mesenchyme of the mesonephric ridge. One ovarian artery or testicular and three suprarenal arteries persist on each side. The phrenic artery branches from the most cranial suprarenal artery frequently present and may be looked on as branches of persistent lateral splanchnic arteries [9].

Blood vessels develop in two ways: by vasculogenesis, in which vessels arises from blood islands, and by angiogenesis, in which new vessels sprout from existing ones. During vasculogenesis process, fibroblast growth factors 2 (FGF2) play major role and binds to its receptor on subpopulations of mesoderm cells and induces them to form hemangioblasts. Then, under influence of vascular endothelial growth factor (VEGF) acting through two receptors (VEGF-R2, VEGF-R1), these cells become endothelial and coalesce to form vessels. Angiogenesis also regulated by VEGF where it stimulates proliferation of endothelial cells at points where new

blood vessels will sprout from existing ones. Final modeling and stabilization of the vasculature are accomplished by platelet-derived growth factor A_2 . Persistence of lateral splanchnic arteries with branches in the form of accessory renal arteries may be attributed to misexpression of any of these transcription factors and signaling molecules as mentioned above viz VEGF, TGF β , PDGF, SHH [10].

Renal ectopia or Ectopic kidneys may present various diagnostic problems specially when acute renal disease develops and there is always a danger that the surgeon maybe unaware and be tempted to remove it as part of an unexplained pelvic mass [11]. Early diagnosis of the ectopic kidney will help to prevent long-term sequels or complications. Most frequently the accessory renal arteries are found on the left side and its occurrence as very high as 30–35% of cases, these arteries usually enter the upper or lower poles of the kidney [12]. There was much discrepancy regarding the side of accessory renal arteries, many researchers have reported a higher frequency on the left side, others reported this variation to be more frequent on the right side [13]. In the present case, we found accessory renal artery on both sides.

Satyanarayana *et al.*, 2011 described about the research findings of the variations in origin of renal arteries immediately below the origin of main renal arteries. The left inferior accessory renal arteries run towards inferior pole of left kidney, in the area where the left renal vein was leaving the left kidney [14]. Banerjee *et al.*, 2014 reported an incompletely rotated kidney with three accessory renal vessels, two renal arteries, and one renal vein at the lower pole in left kidney [15].

The study by Singh *et al.*, 2015 mentioned about the bilateral malrotation of both kidneys and a left lobulated ectopic kidney along with open hilum. The left kidney showed a pelvic position in front of sacral promontory with malrotation and three renal arteries retaining its embryological aorto-iliac branches. The two renal veins draining into right common iliac vein [16].

Sasikala *et al.*, 2017 had observed and reported about accessory renal arteries associated with congenital kidney anomalies in two cadavers: one cadaver with polycystic kidney with accessory renal artery in the right kidney, the second cadaver had malrotated kidney with accessory renal artery on the left kidney [17]. Haider Rizvi *et al.*, 2018 noted ectopic lumbar kidney during clinical examination of patient conformed by Sonography, Multislice computed tomography [18].

These accessory renal arteries are important in surgical procedures related to the posterior abdominal wall, important during kidney transplantations,

abdominal aortic aneurysm repairs, ureter surgery and procedures involving the vascular pedicles of kidney. It may be also important for radiologists for interpretation of roentgenographic examinations in angiographic procedure. Finally, anatomical knowledge of variations of renal arteries is essential before performing any surgeries related to transplantation, where microvascular techniques are involved to reconstruct the renal arteries [19].

REFERENCES

- Romanes, G., & Cunningham's, J. (1986). Manual of Practical Anatomy. Volume II: Thorax and Abdomen, Oxford University Press, 15th edition.
- Shalika, S., & Sunanda, R. (2014). Study of Human Fetal Kidney. *International Journal Anatomy Research*, 2(4):785-790.
- Adamakis, I., Pournaras, C., Katafigiotis, I., Kousournas, G., Fragkiadis, E., Leotsakos, I., ... & Constantinides, C. (2013). Radical cystectomy and lymphadenectomy to two patients with pelvic kidney: surgical pitfalls and considerations. *Case reports in medicine*, 1(3), 3.
- Meizner, I., Yitzhak, M., Levi, A., Barki, Y., Barnhard, Y., & Glezerman, M. (1995). Fetal pelvic kidney: a challenge in prenatal diagnosis?. *Ultrasound in Obstetrics and Gynecology: The Official Journal of the International Society of Ultrasound in Obstetrics and Gynecology*, 5(6), 391-393.
- Kara, E., Öztürk, N. C., Özgür, A., Yıldız, A., & Öztürk, H. (2011). Ectopic kidney with varied vasculature: demonstrated by CT angiography. *Surgical and Radiologic Anatomy*, 33(1), 81-84.
- Russell, R. C. G., Williams N. S., & Bulstrade, C. J. K. (2000). Bailey and Love's short practice of surgery. In: The kidneys and ureters. 23rd ed; Arnold, London, 1174.
- Benjamin, J. A., & Tobin, C. E. (1951). Abnormalities of the kidneys, ureters, and perinephric fascia: Anatomic and clinical study. *The Journal of urology*, 65(5), 715-731.
- Sadler, T. W. (2006). Langman's medical embryology. In: Urogenital system. 10th ed; Philadelphia Lippincott Williams & Wilkins; 236.
- Standring, S., Ellis, H., & Healy, J. C. (2005). Gray's Anatomy. 39th ed. Philadelphia Elsevier Churchill Livingstone, 1274.
- Sadler, T. W. (2006). Langman's Medical Embryology. In: blood and blood vessels. 10th ed. Philadelphia Lippincott Williams & Wilkins, 78.
- Russell, R. C., Williams, N. S., Bulstrade, C. J. K. (2000). Bailey and Love's short practice of surgery. In: The kidneys and ureters. 23rd ed; Arnold, London; 1174.
- Singh, G., Ng, Y. K., & Bay, B. H. (1998). Bilateral accessory renal arteries associated with some anomalies of the ovarian arteries: a case study. *Clinical Anatomy: The Official Journal of the American Association of Clinical Anatomists and the British Association of Clinical Anatomists*, 11(6), 417-420.
- Nayak, S. (2006). Common celiaco-mesenterico-phrenic trunk and renal vascular variations. *Saudi medical journal*, 27(12), 1894-1896.
- Satyanarayana, N., Guha, R., Nitin, V., Praveen, G., Datta, A. K., & Sunitha, P. (2011). Left inferior accessory renal arteries its embryological basis and clinical significance. *Journal of College of Medical Sciences-Nepal*, 7(1), 65-68.
- Banerjee, S. S., Paranjape, V., Arole, V., & Vatsalawamy, P. (2014). Variation of hilar anatomy in an incompletely rotated kidney associated with accessory renal vessels. *Medical Journal of Dr. DY Patil University*, 7(5), 645-647.
- Singh, J., Singh, N., Kapoor, K., & Sharma, M. (2015). Bilateral malrotation and a congenital pelvic kidney with varied vasculature and altered hilar anatomy. *Case reports in medicine*, 1-3.
- Sasikala, P., & Singh, S. (2017). Accessory renal artery associated with congenital kidney anomalies. *Anatomy*, 11(2), 67-71.
- Rizvi, E. H., Charokar, K., & Jain, A. K. (2018). Ectopic lumbar kidney: a rare presentation. *International Surgery Journal*, 5(10), 3410-3413.
- Brannen, G. E., Bush, W. H., Correa, R. J., Gibbons, R. P., & Cumes, D. M. (1982). Microvascular management of multiple renal arteries in transplantation. *The Journal of urology*, 128(1), 112-115.