

Variation in the Posterior Arch of the Atlas Vertebra and Its Clinical Significance

Dr. Urmila N Pateliya¹, Dr. Sunita Gupta^{2*}, Dr. Prabhakaran³

¹PhD Scholar, Gujarat University, Ahmedabad. Assistant Professor, Department of Anatomy, Nootan Medical College and Research Centre, Visnagar, Gujarat, India

²PhD Guide, Gujarat University, Ahmedabad. Professor and Head, Department of Anatomy, AMC Met Medical College, Balvatika, Archana Society, Bhairavnath, Maninagar, Ahmedabad, Gujarat 380008, India

³Professor and Head, Department of Anatomy, Nootan Medical College and Research Centre, Visnagar, Gujarat, India

*Corresponding author: Dr. Sunita Gupta

| Received: 02.03.2019 | Accepted: 05.03.2019 | Published: 30.03.2019

DOI: [10.21276/sijap.2019.2.3.6](https://doi.org/10.21276/sijap.2019.2.3.6)

Abstract

Introduction: Variation in posterior arch of atlas are very rare. Variation is due to developmental anomaly, its detection is incidental while investigation for head and neck region. Our aim is determine the variation in posterior arch of atlas.

Materials and methods: 50 dried atlases of unknown sex used for the study from department of Anatomy of medical college of Gujarat. **Results and observation:** 3 atlases showed absence of median part of posterior arch out of 50 vertebrae. Conclusion: Such variations must be noted by surgeons and radiologist.

Keywords: Atlas vertebrae, Posterior arch, ossification, Clinical Significance.

Copyright @ 2019: This is an open-access article distributed under the terms of the Creative Commons Attribution license which permits unrestricted use, distribution, and reproduction in any medium for non-commercial use (NonCommercial, or CC-BY-NC) provided the original author and source are credited.

INTRODUCTION

First cervical vertebra is atypical vertebra. It is also known as atlas because it supports the globe of the head [1]. It is ring shaped having two arches: anterior and posterior. Atlas differs from other vertebrae by absence of body and spine, contains weight bearing lateral mass with articular facets. Posterior arch forms 3/5th of circumference of atlantal ring, having groove called as sulcus arteriaevertebralis which transmits vertebral artery and first cervical nerve [2]. Transverse processes of cervical vertebrae contain foramina transversaria, important identifying feature of cervical vertebrae. Atlas ossifies from three centres, one for each lateral mass with half of the posterior arch. The centre for the lateral masses appear during seventh week of intrauterine life and unite posteriorly at about three years. The centre for anterior arch appears at about first year and unites with the lateral mass about seven years.

Posterior arch of atlas begins its ossification during the seventh week of intrauterine life. The vertebral laminae fuse at the time of birth, except for some length of cartilage. Complete fusion of posterior arch is expected to occur between 3 and 5 years of age. In about 2% of population, additional centers may be present posteriorly in the midline forming the posterior tubercle of the atlas during the 2nd year of life [3, 4, 7, 18]. It is very important to know about this variation during surgeries at atlanto-occipital joints. Our study provides detailed information about this variation and it will be useful for surgeons and radiologists.

MATERIALS AND METHODS

50 dried atlases of unknown sex used for the study from department of Anatomy of medical college of Gujarat. Each atlas was observed for posterior arch and any variations were photographed.

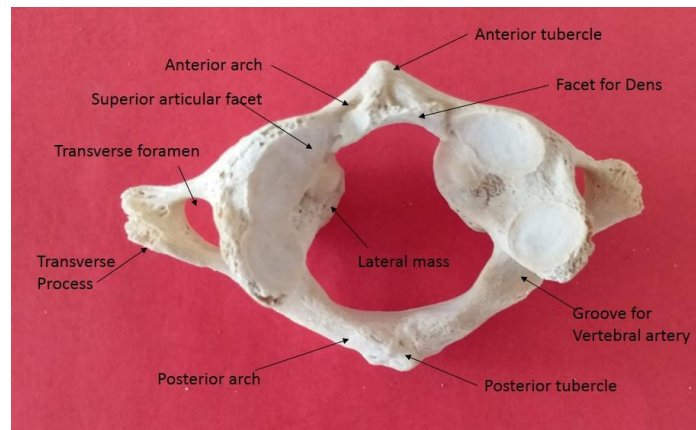


Fig-1: Atlas Vertebra

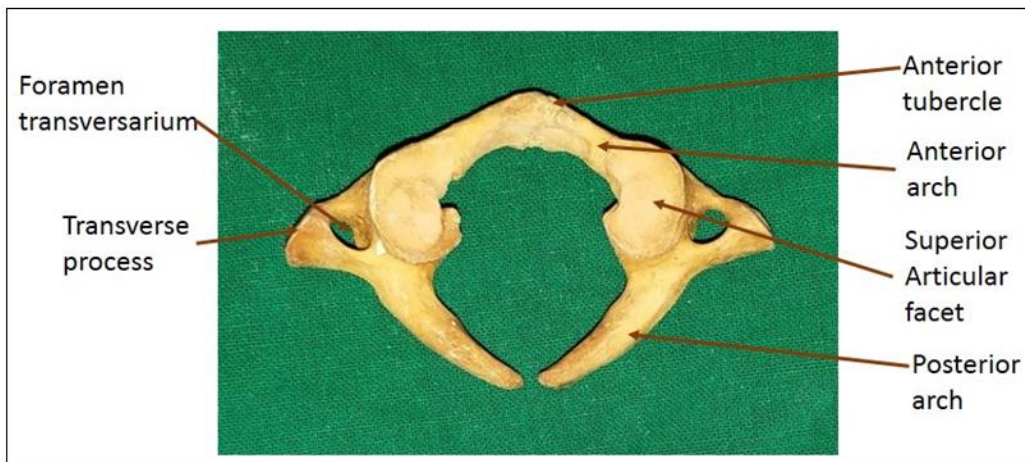


Fig-2: Atlas Vertebra deficiency in posterior arch

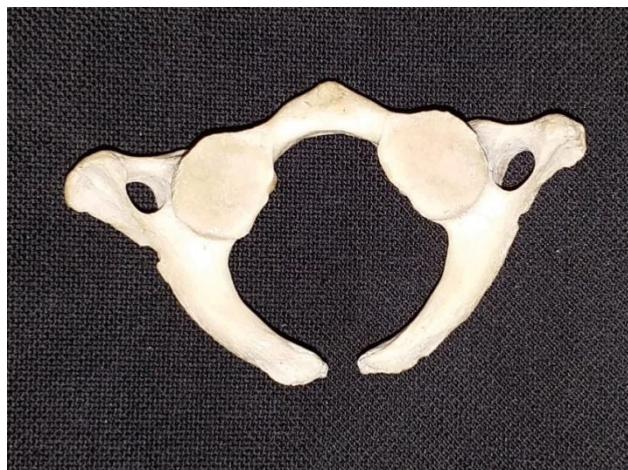

Fig-2: Atlas Vertebra deficiency in posterior arch

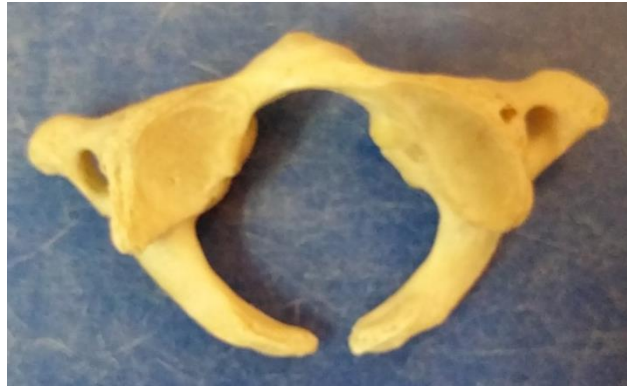

Fig-4: Atlas Vertebra deficiency in posterior arch

RESULTS

Out of 50 atlas vertebrae, 3 atlas vertebrae showed median deficiency in the posterior arch of atlas vertebrae was observed. The right and left limb of the arch of the three vertebrae showed a blunt ending.

DISCUSSION

Atlas vertebra shows greatest variability among the cervical vertebrae. Many authors have described about variations of atlas but little literature is available about median deficiency of posterior arch of atlas. In our study out of 50 atlases, 3 showed absence of deficiency of posterior arch.

Variations in this specialized region may present clinical features varying from mild neck pain, headache, vertigo, buzzing ears to neurological symptoms depending on the degree of variation. The clefts and aplasia of the atlas are rare variations

The region of the upper cervical spine due to its complicated embryonic development has been reported to be highly vulnerable to skeletal and neural developmental variants.

Atlas develops from three centers of ossification: one for the anterior tubercle and two for the lateral masses. The ossification of the posterior arch begins during the 7th week of the intrauterine life and proceeds perichondrally from the two centers located in the lateral masses. A separate ossification center develops in the posterior cartilaginous cleft during the second year of life. Complete ossification of the posterior arch occurs between 3–5 years of age. Defects in the posterior arch have been attributed to absence or defective development of cartilaginous preformation rather than disturbances of the ossification of the arch [2, 9].

Posterior arch deficiencies may range from moderate defects (median, uni- and bilateral clefts) to complete lack of ossification [5].

Thereby, suggesting a higher incidence in females as compared to the males. Several disorders including Arnold-Chiari malformations, gonadal dysgenesis and the Klippel-Feil, Down and Turner syndromes have been associated with the congenital absence and hyperplasia of the posterior arch of the atlas.

In most reports, deficits in the posterior arch have been discovered incidentally in asymptomatic subjects following x-ray examination of cervical spine due to mild injury [4-6].

Schulze PJ *et al.*, examined 26-year-old male patient with head trauma after traffic accident with headache and neck pain. Find absence of posterior arch of atlas by CT scan and MRI. The patient was managed conservatively. He was fine after a year [4].

Hosalkar HS *et al.*, Lateral cervical spine radiograph revealed two hemiarches of C1 with a hypoplasia in the midline. Cervical 2D and 3D reconstructed computed tomography (CT) studies showed hypoplasia of the posterior arch of the C1 and may be mistaken for fractures in patients who have sustained cervical spine injuries [5].

P. Prahaladu1 *et al.*, a case report of 12 year old boy absent posterior arch and partial occipitalization of right half of atlas by xray and CT scan [7].

Study by Mehta UK *et al.*, examined 75 atlas vertebrae analysed 3 presented with posterior arch defect, two with Type A defect and one with Type B defect. The total incidence of posterior arch defect is 4%. Type A: Failure of posterior midline fusion of the 2 hemi arches. Commonly appear as a fissure or a small gap in the midline. Type B: Unilateral cleft. A defect is present on one side, which ranges from a small cleft to complete absence of one half of the arch. Type C: Bilateral cleft with persistent dorsal part of arch. Type D: Absence of posterior arch with persistent posterior tubercle. Type E: Absence of entire posterior arch [8].

Paksu D *et al.*, observed congenital atlas defect in 25 year-old woman, Radiographs incidentally

revealed aplasia of the posterior arch of the atlas together with anterior rachischisis [8].

However, no reports documenting association between permanent neurological deficits and occurrence of posterior arch defects have been reported. Cervical spine radiography with flexion/extension views may help to detect cases with mechanical instability where there is increased risk of spinal cord injury [9].

Richardson EG, *et al.*, Plain lateral X-rays of the cervical spine showed absence of the posterior arch of atlas but a posterior tubercle was present. CT identified a bilateral defect with a remaining posterior tubercle, isolated from any other bony contact. The present case befits into type A, of their classification. Kwon and coworkers cited the study of Geipel, who reported clefts of the posterior arch in 4% of 1613 autopsy specimens studied, 97% being median clefts [10].

Wysocki J *et al.*, identified Anatomical variation of Split posterior (3%) or anterior (1%) arches of the atlas from the study of 100 cervical vertebra [11].

EC Tan *et al.*, identified 36-year-old female shows Radiographs of the cervical spine showed a radiolucent area in the region of the posterior arch of the atlas. Computed tomography subsequently revealed partial absence of the posterior arch of the atlas with a defect at the anterior ring. This case report illustrates a situation where congenital defect of the posterior arch of the atlas was revealed in a patient with neck pain [12].

Parul *et al.*, have identified median deficiency in the posterior arch of one of the thirty atlas vertebrae was observed. The right limb of the arch showed a bulbous ending, while the left limb of the arch had a flattened appearance [13].

L. Corominas *et al.*, identified Congenital absence of the posterior arch of the atlas associated with a fracture of the anterior arch in, nine-year old boy presented with a history of occipital headache for two months after axial compression of his neck while performing somersaults. He reported that the pain increased with hyperextension of the neck [14].

Guido Currarino *et al.*, identified seven person with defect in posterior arch four of them presented with absence of entire posterior arch, two person presented with bilateral posterior arch cleft and one presented with unilateral posterior arch cleft [15].

U. Solomon Krupanidhi *et al.*, out of 109 atlas vertebra five were show defect in posterior arch of atlas [16].

Howard L. Dorne *et al.*, identified a case of total hemiapsia of the right posterior arch, partial hemiapsia of the left posterior arch, and a midline cleft of the anterior arch in 24 year old male by CT scan [17].

Joseph JJunewick *et al.*, studied on pattern of ossification of atlas vertebra by CT scan. He studied in all age group, and correlate with the ossification pattern. In anterior arch, incomplete ossification was noted in 47 of 103 patients (46%) in the 85–96-month age category. In posterior arch Eight of the 185 (4%) did not have a midline posterior synchondrosis; five of the eight had bilateral paramedian clefts and three of the eight had a unilateral paramedian cleft. A hypoplastic right posterior arch discontinuous with the lateral mass was seen in one patient [18].

Mario Ganau *et al.*, presented a case of a 74 year-old man, admitted with head and cervical spine traumatic injury complained of mild neck pain, CT scan, demonstrated an anterior small defect of the arch on its left side, with tiny bony fragments in the middle of the defect, and a posterior rim defect at the level of the first cervical tuberculum [19].

G. M. Karwacki *et al.*, observe in anlage to stop at the ventrolateral synchondrosis. In 38 of 230 patients (16.5%), a large unossified midline gap and no ventral ossification centre were observed anterior arch of atlas. In 3 patients they observed an additional, centrally located Ossification centre within the Posterior arch of atlas [20].

S Garg *et al.*, found 4 patients of bipartite atlas, .2% of total Bipartite atlas or split atlas defects were found in 4 of the 1,735 patients. The type A posterior arch defect was found in 3 patients and the type B posterior arch defect was found in one patient. No type C, D, or E defects were observed in these bipartite atlas defect Congenital [21].

Ji Won C *et al.*, A computed tomography scan showed the midline cleft within the anterior arch of the atlas and the bilateral bony defects of the lateral aspects of the C1 posterior arch with the most dorsal part of the posterior arch preserved in a 46-year-old male presented with a 2-month history of tremor and hyperesthesia of the lower extremities after a minor head trauma [22].

Sebastian Guenkel *et al.*, analyzed 1069 patients, they found 41 cases of atlas arch defects. This represents 3.8% of all patients. Of the 41 found anomalies, 38 cases presented a dorsal arch defect. Type A was predominant with 34 cases. One vertebrae shows a typical example of type A according to the classification of Currarino *et al.*, Abipartite spodyloschisis was present in 2 cases. One

patient showed a total irregular form of the atlas vertebra [23].

Aseem Sharma *et al.*, Presented a 3 case of atlas defect, one was 32-year-old woman weakness and numbness of all four limbs after sustaining a minor head trauma. Plain radiographs of the cervical spine revealed bilateral defects in the posterior arch of the atlas with an isolated bony posterior arch remnant. MR imaging of the cervical spine showed partial aplasia of the posterior arch of the atlas.

Second was 35-year-old woman with neck pain of 6 months' duration and a tingling sensation and weakness in both upper limbs of 3 months' duration. Plain radiographs of the cervical spine showed aplasia of the posterior arch of the atlas with an intact posterior tubercle.

Third one a 30-year-old man suffering from neck pain and stiffness for the past 5 years. In radiographs reported as fractures in the posterior arch of the atlas. The patient was put in traction, and subsequently wore a cervical collar for several months, because subsequent radiographs showed no healing of the defects. The radiographs were reviewed and were thought to reveal partial aplasia of the posterior arch. A subsequent CT scan showed the defects to be margined by bone, with a smooth cortical outline. Radiographs taken during extension of the neck clearly showed anterior movement of the isolated posterior bony fragment. Spine revealed aplasia of the posterior arch of the atlas with an intact posterior tubercle [24].

Pralaya Koshore Nayak *et al.*, A case report of 22-year-old male presented to us with head injury. X-ray screening of the cervical spine revealed two posterior arches of the atlas. Computed tomography (CT) scan of the cervical spine showed, both anterior and posterior splitting of the arch of atlas along with fusion of the dens to right side of the anterior a. 3D reconstruction in the CT scan, posterior splitting of arches at different level in the axial plane, and a double posterior component in lateral X-ray film also the bodies of C1 and C2 were fused on the right side [25].

Lokesh S Nehete *et al.*, presented a case of C1 arch stenosis, canal is ellipsoid in shape with reduced anteroposterior diameter along with absence of posterior arch in midline. Arch is bifid with inward inclination [26].

Andreas Panagopoulos *et al.*, presented a case report of 24-year-old man after a road traffic accident Plain X-rays of cervical spine revealed a free bony fragment in the lateral aspect of the posterior arc of the atlas that was initially interpreted as a fracture (Fig-1). On detailed examination, the lesion was found to have smooth edges, the posterior arc of the atlas was not be clearly visualized. In CTscan of the C1/C2 region

confirmed the presence of posterior arch aplasia, a butterfly-shape atlas and persistent posterior tubercle [27].

Awareness of the existence of this condition will helpful clinicians to avoid misdiagnosis and excessive investigations.

Knowledge of this variation is also significant importance to orthopedists, as its co-existence with fractures may result in instability in the cervico-occipital region and non-union thereby leading to difficulty in further management. The recognition of this variation, early in life may prevent serious neurological deficits in subjects having any defects in the posterior arch, by restricting their neck movements and activities like strenuous sports

CONCLUSIONS

In our study incidence of deficiency of Median part in the posterior arch of the atlas vertebrae is 6%. It is a rare anomaly, usually the patient are asymptomatic and presented with headache and other associated defect or traumatic injury. It may be mistaken with fracture. Knowledge of such variations may be helpful for anthropologist, surgeons during cervical surgeries and for radiologist in interpreting the X rays.

REFERENCES

1. Datta, A. K. Essentials of Human Anatomy, Head and Neck. Cervical Vertebral; 4th Edition; 200-202.
2. Williams, P. L., Bannister, L. H., Berry, M. M., & Harold, E. (1995). "skeletal system" and "Cardiovascular system- subclavian system of arteries," Gray's Anatomy; The anatomical basis of clinical practice 38th edn. Churchill Livingstone, London; 516-519.
3. Krishna Garg, PS Mittal, Mrudula Chandrupatla. BD Chaurasia's Human Anatomy 6th ed. Introduction and Osteology, 52.
4. Schulze, P. J., & Buurman, R. (1980). Absence of the posterior arch of the atlas. *American Journal of Roentgenology*, 134(1), 178-180.
5. Hosalkar, H. S., Gerardi, J. A., & Shaw, B. A. (2001). Combined asymptomatic congenital anterior and posterior deficiency of the atlas. *Pediatric radiology*, 31(11), 810-813.
6. Prahaladu, P., Nagamani, M., Lakshmi Kumari, K., Vijaya Babu, P. V. S. S., & Mahapatro, A. (2015). Congenital absence of posterior arch of atlas with atlantoaxial subluxation—a case report. *IOSR J Dent Med Sci*, 14, 26-28.
7. Mehta, U., Geetha, K., Gaikward, M., & Chavan, L. (2014). Posterior arch anomalies of atlas and its clinical significance. *Int J Med Res Rev*, 2, 361-366.
8. Pasku, D., Katonis, P., Karantanis, A., & Hadjipavlou, A. (2007). Congenital posterior atlas defect associated with anterior rachischisis and early cervical degenerative disc disease: A case

- study and review of the literature. *Acta orthopaedica belgica*, 73(2), 282-285.
9. Richardson, E. G., Boone, S. C., & Reid, R. L. (1975). Intermittent quadriplegia associated with a congenital anomaly of the posterior arch of the atlas. Case report. *JBJS*, 57(6), 853-854.
 10. Kwon, J. K., Kim, M. S., & Lee, G. J. (2009). The incidence and clinical implications of congenital defects of atlantal arch. *Journal of Korean Neurosurgical Society*, 46(6), 522-527.
 11. Wysocki, J., Bubrowski, M., Reymond, J., & Kwiatkowski, J. (2003). Anatomical variants of the cervical vertebrae and the first thoracic vertebra in man. *Folia morphologica*, 62(4), 357-363.
 12. Tan, E. C., Soon, H. C., Kevin, M., & To, S. (2007). Congenital absence of the posterior arch of the atlas—A strange but benign anomaly. *Malaysian Orthopaedic Journal*, 1(2), 30-32.
 13. Kaushal, P. (2011). Median deficiency in the posterior arch of the atlas vertebra: a case report. *International Journal of Anatomical Variations*, 4(1), 67-68.
 14. Corominas, L., & Masrouha, K. Z. (2010). Case report: Congenital absence of the posterior arch of atlas associated with a fracture of the anterior arch. *Journal of bone Jt Surg*, 92:1300-1302.
 15. Currarino, G., Rollins, N., & Diehl, J. T. (1994). Congenital defects of the posterior arch of the atlas: a report of seven cases including an affected mother and son. *American Journal of Neuroradiology*, 15(2), 249-254.
 16. Solomon, K. U., Jayprakash, B. R., Mallirkunj, M., & Phaniraj, S. (2013). Congenital posterior arch defects of the Atlas. *International Journal of Biomedical Research* 4(12):713-715.
 17. Dorne, H. L., & Lander, P. H. (1986). CT recognition of anomalies of the posterior arch of the atlas vertebra: differentiation from fracture. *American journal of neuroradiology*, 7(1), 176-177.
 18. Junewick, J. J., Chin, M. S., Meesa, I. R., Ghori, S., Boynton, S. J., & Luttenton, C. R. (2011). Ossification patterns of the atlas vertebra. *American Journal of Roentgenology*, 197(5), 1229-1234.
 19. Ganau, M., Spinelli, R., & Tacconi, L. (2013). Complex developmental abnormality of the atlas mimicking a Jefferson fracture: Diagnostic tips and tricks. *Journal of emergencies, trauma, and shock*, 6(1), 47-49.
 20. Karwacki, G. M., & Schneider, J. F. (2012). Normal ossification patterns of atlas and axis: a CT study. *American Journal of Neuroradiology*, 33(10), 1882-1887.
 21. Garg, S., Agarwal, R., & Goyal, D. (2018). Bipartite Atlas –A Rare Entity, a Study of Its Incidence in North Indians. *Annals of International Medical and Dental Research*, 4(1):AT01-AT05.
 22. Choi, J. W., Jeong, J. H., Moon, S. M., & Hwang, H. S. (2011). Congenital cleft of anterior arch and partial aplasia of the posterior arch of the C1. *Journal of Korean Neurosurgical Society*, 49(3), 178-181.
 23. Guenkel, S., Schlaepfer, S., Gordic, S., Wanner, G. A., Simmen, H. P., & Werner, C. M. (2013). Incidence and variants of posterior arch defects of the atlas vertebra. *Radiology research and practice*.
 24. Sharma, A., Gaikwad, S. B., Deol, P. S., Mishra, N. K., & Kale, S. S. (2000). Partial aplasia of the posterior arch of the atlas with an isolated posterior arch remnant: findings in three cases. *American journal of neuroradiology*, 21(6), 1167-1171.
 25. Pralaya, K. N. (2017). Double C1 Posterior Arch. *Journal of Neurosciences in Rural Practice*, 8(11):S161-S162.
 26. Nehete, L. S., Bhat, D. I., Gopalakrishnan, M. S., Shukla, D., Konar, S., Singh, P., & Devi, B. I. (2018). Unusual cause of high cervical myelopathy-C1 arch stenosis. *Journal of craniovertebral junction & spine*, 9(1), 37-43.
 27. Panagopoulos, A., Zouboulis, P., Athanaselis, E., Papadopoulos, A. X., & Dimakopoulos, P. (2005). Aplasia of the posterior arc of the atlas with persistent posterior tubercle: a case report. *European Spine Journal*, 14(2), 205-207.